

Abdominal wall, Omentum, Mesentery & Retroperitoneum

Surgery 1

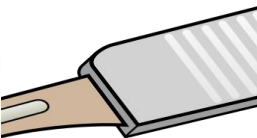
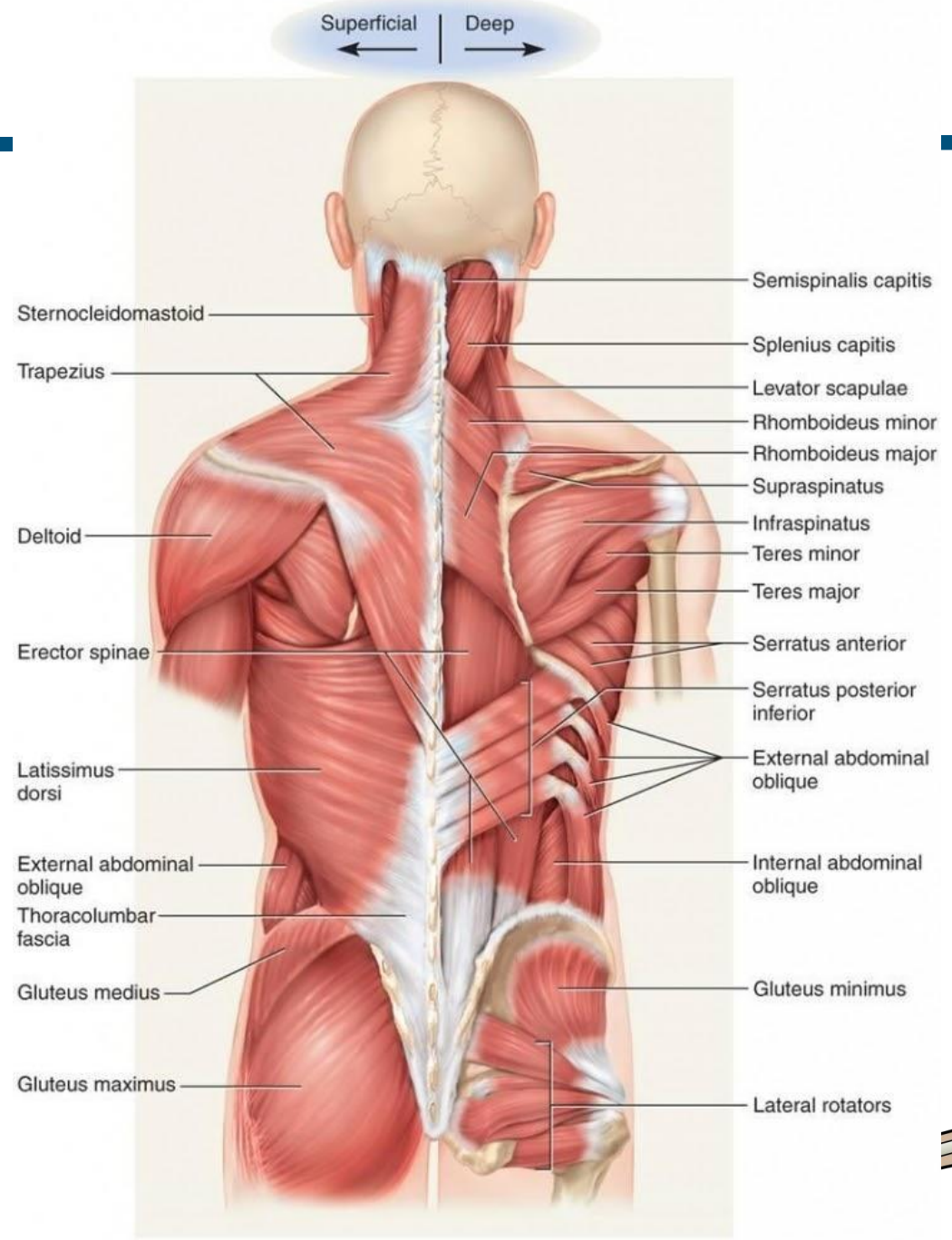
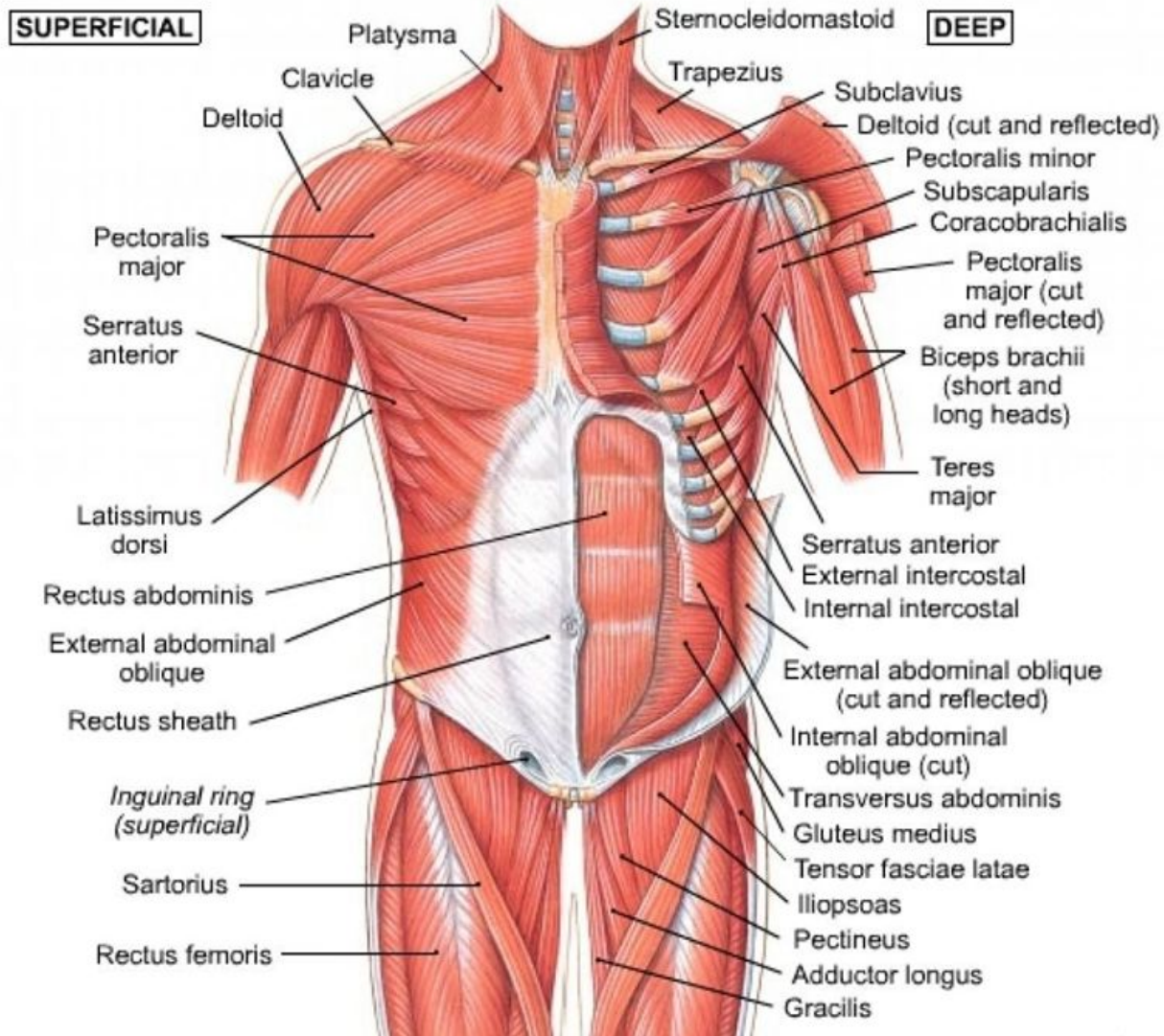
Dr. Badri Kobalava

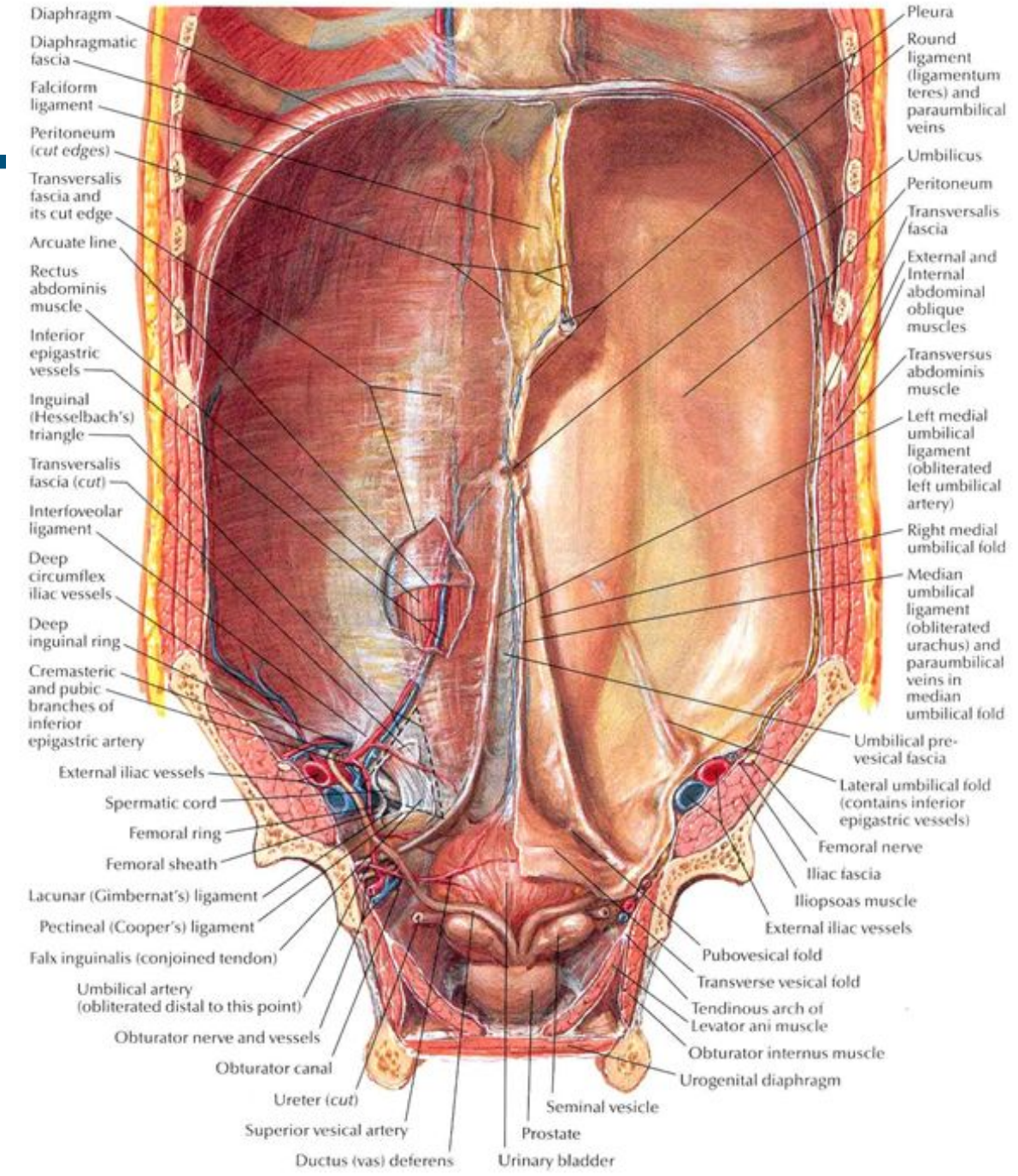
bkobalava@newvision.ge

<https://sites.google.com/view/dr-badri-kobalava-nvu>

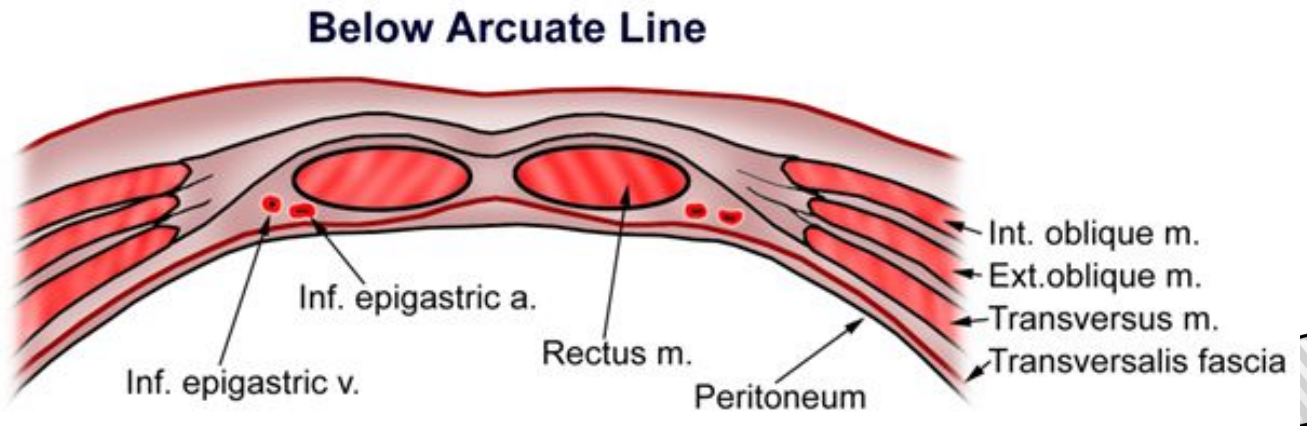
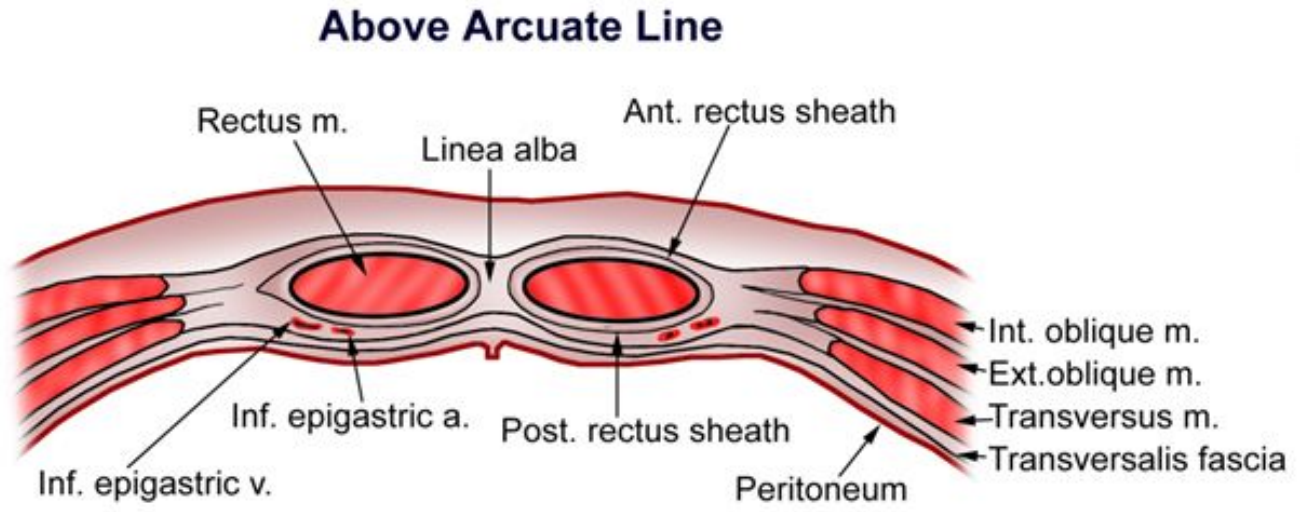


Abdominal wall





⇐ ⇐ Inner view of the anterior abdominal view



Rectus sheath anatomy

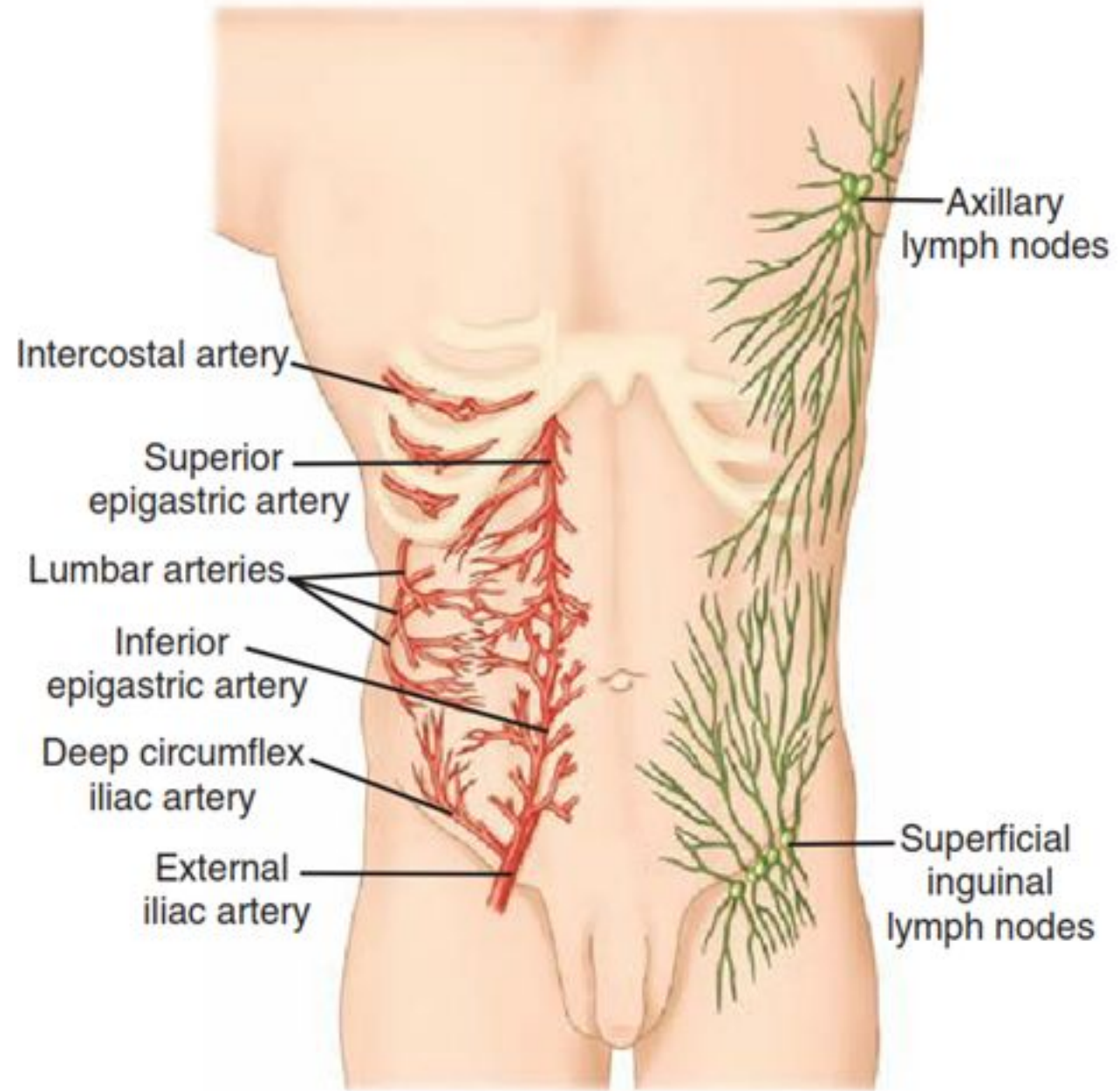
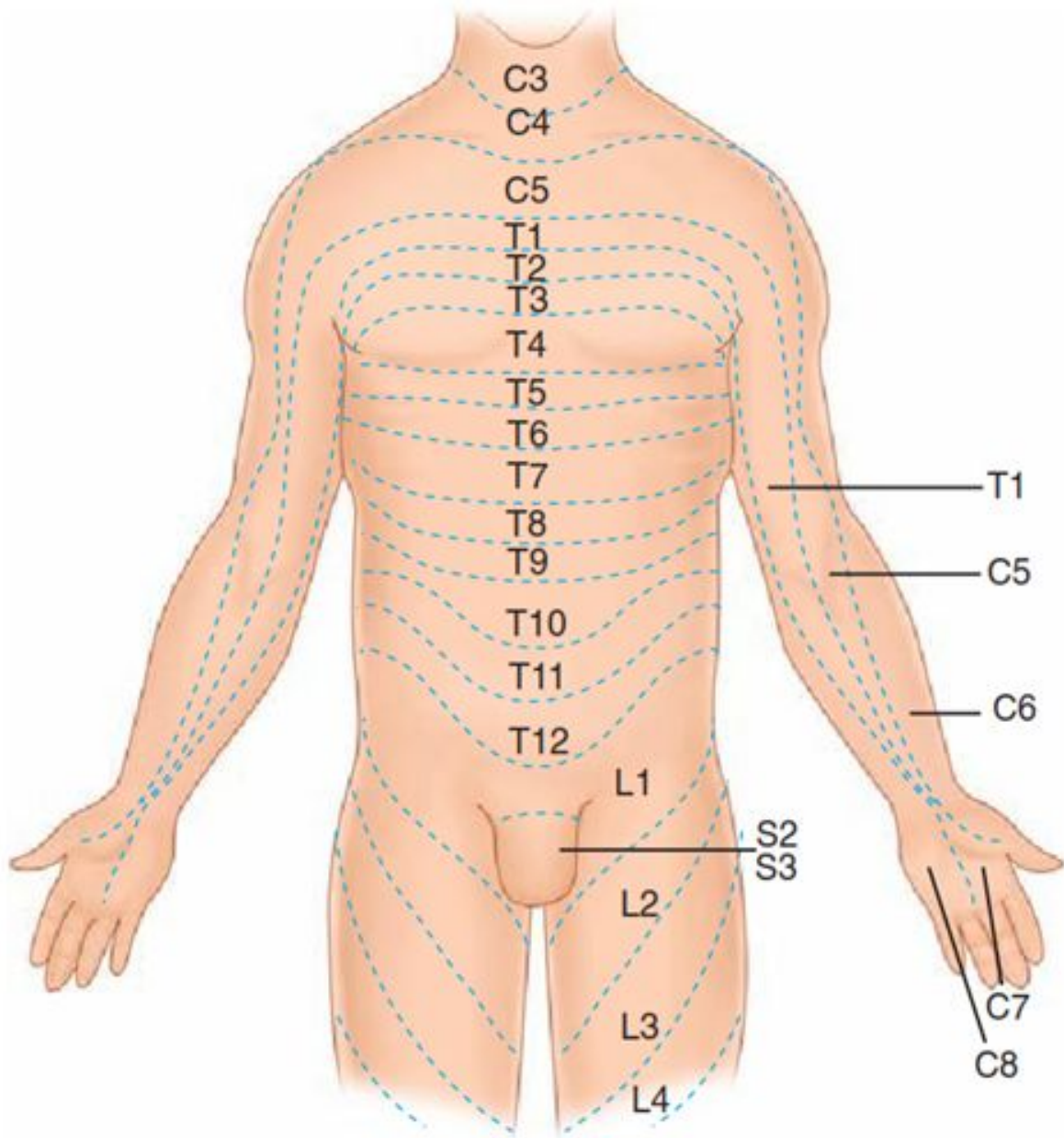
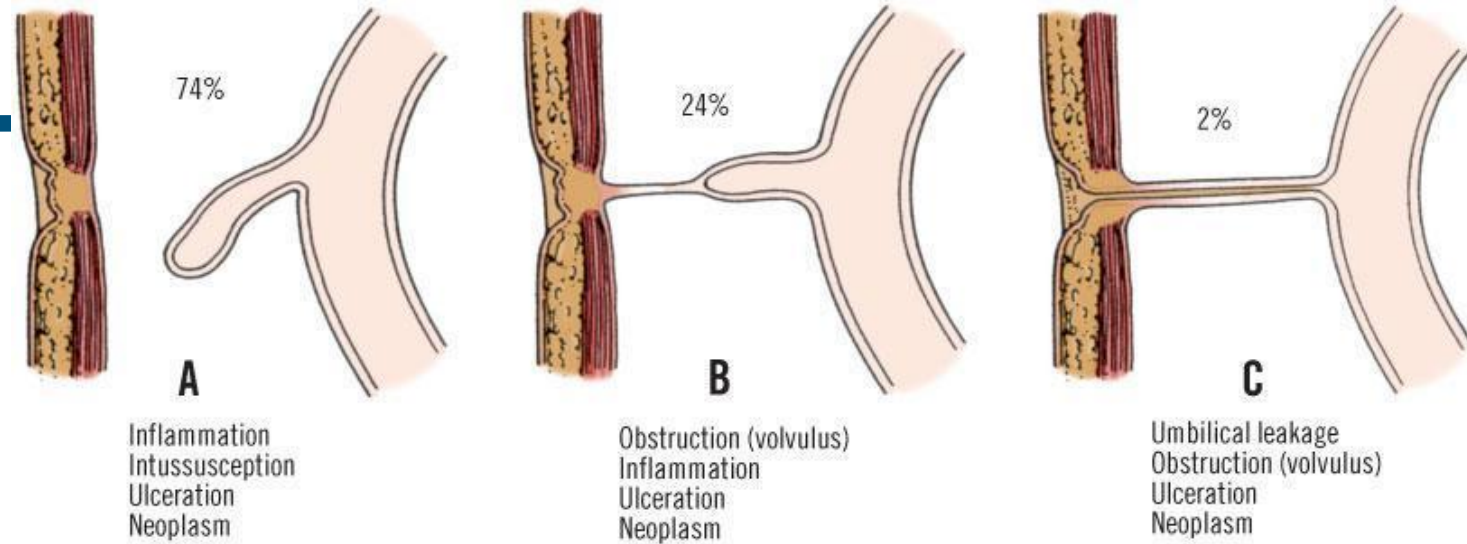
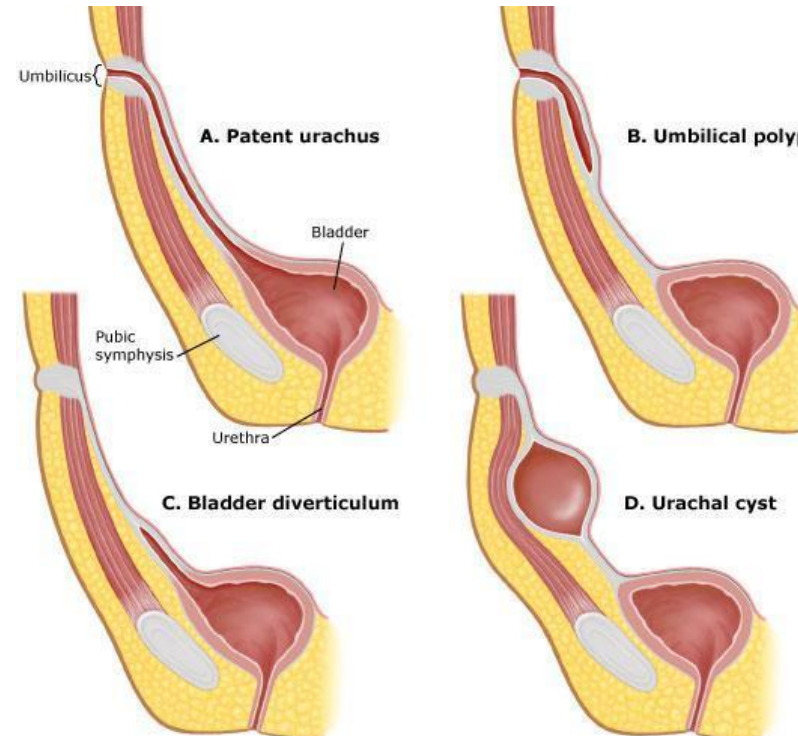


Figure 35-5. Dermatomal sensory innervation of the abdominal

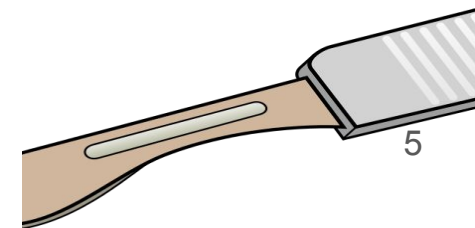
- The vitelline duct connects the embryonic and fetal midgut to the yolk sac. During the third trimester, the vitelline duct regresses
- Remnant - Meckel's diverticulum.
- Vitelline duct fistula, which is associated with drainage of small intestinal contents from the umbilicus
- Vitelline duct (omphalomesenteric) cyst may occur



Copyright ©2006 by The McGraw-Hill Companies, Inc. All rights reserved.

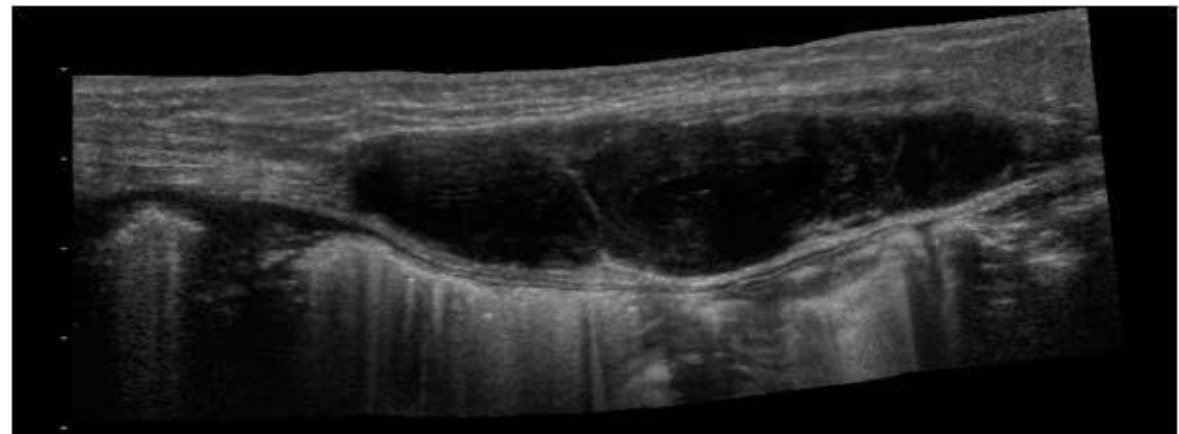
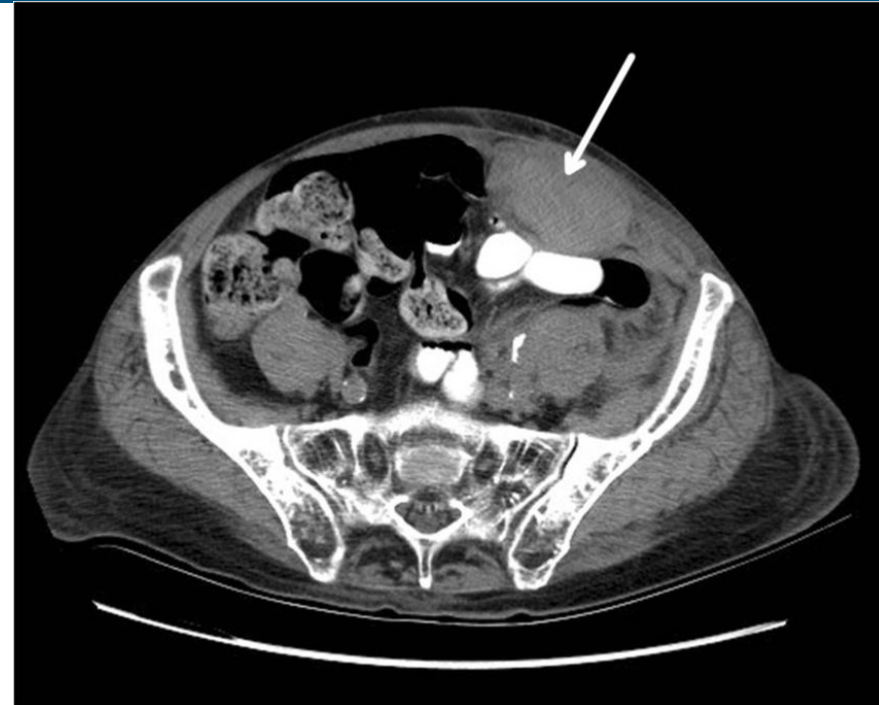


- The urachus is a fibromuscular tubular extension of the allantois



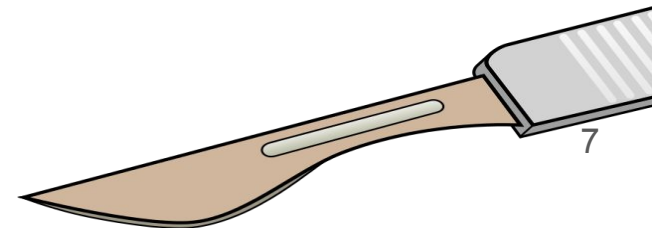
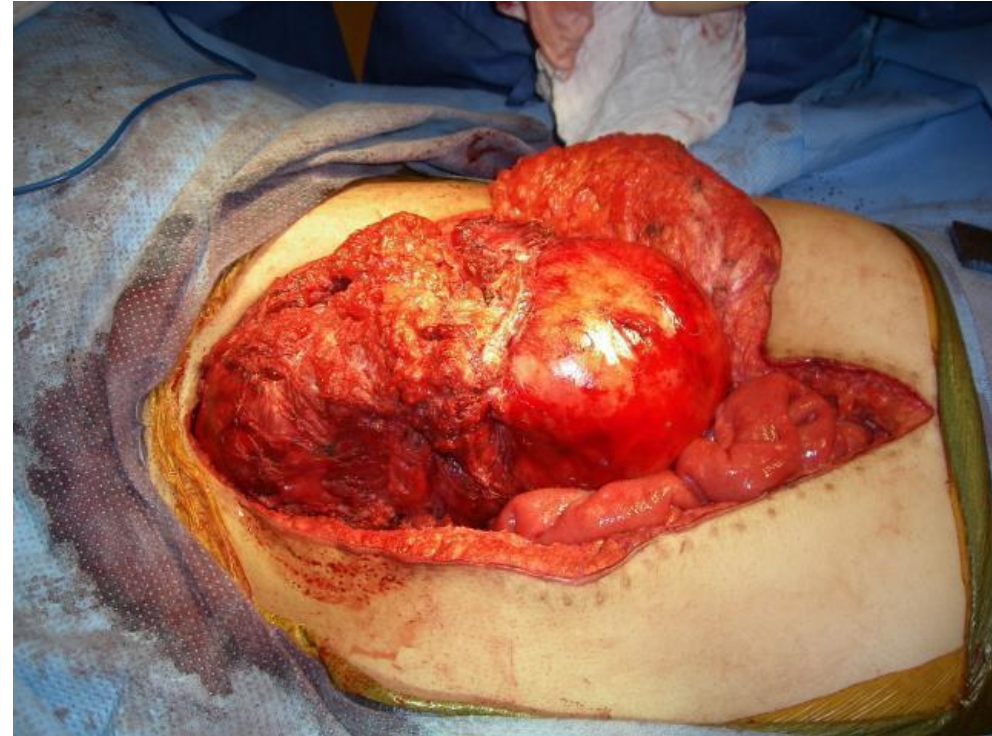
Rectus Sheath Hematoma

- Sudden contraction of the rectus muscles with coughing, sneezing, or any vigorous physical activity
- On anticoagulation therapy
- Sudden onset of unilateral abdominal pain
- Pain typically increases with contraction of the rectus muscles,
- Tender mass may be palpated
- Hemoglobin/hematocrit level and coagulation studies
- Ultrasonography and CT
- Angiographic embolization
- Ligation of any bleeding vessel



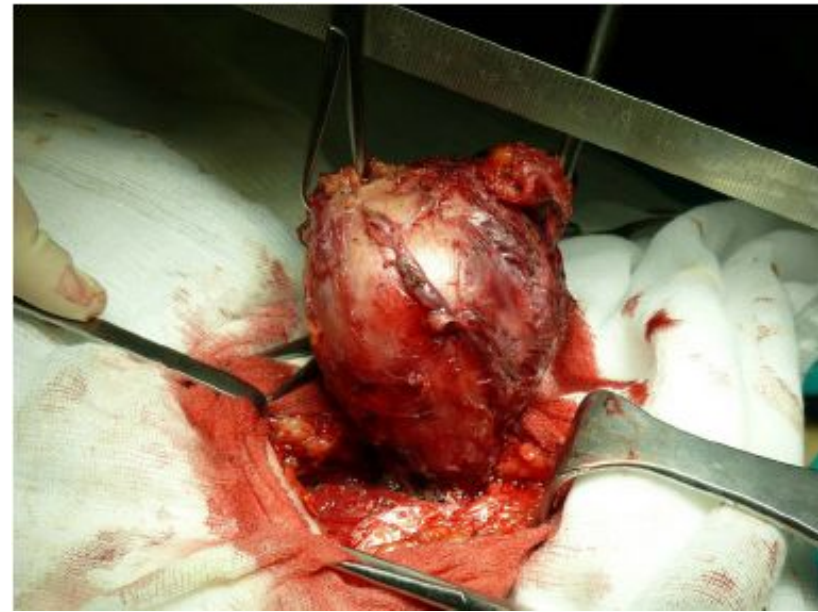Desmoid Tumors

- Fibrous neoplasms originating from the musculoaponeurotic structures
- **Aggressive fibrosis**
- Infiltrative local behavior
- Do not have metastatic potential
- Postpartum women or in surgical scars
- Radical resection with frozen section margins and immediate mesh reconstruction of any consequent abdominal wall defect
- Recurrence rates as high as 80%
- Medical treatment with an antineoplastic agent



Other neoplasms

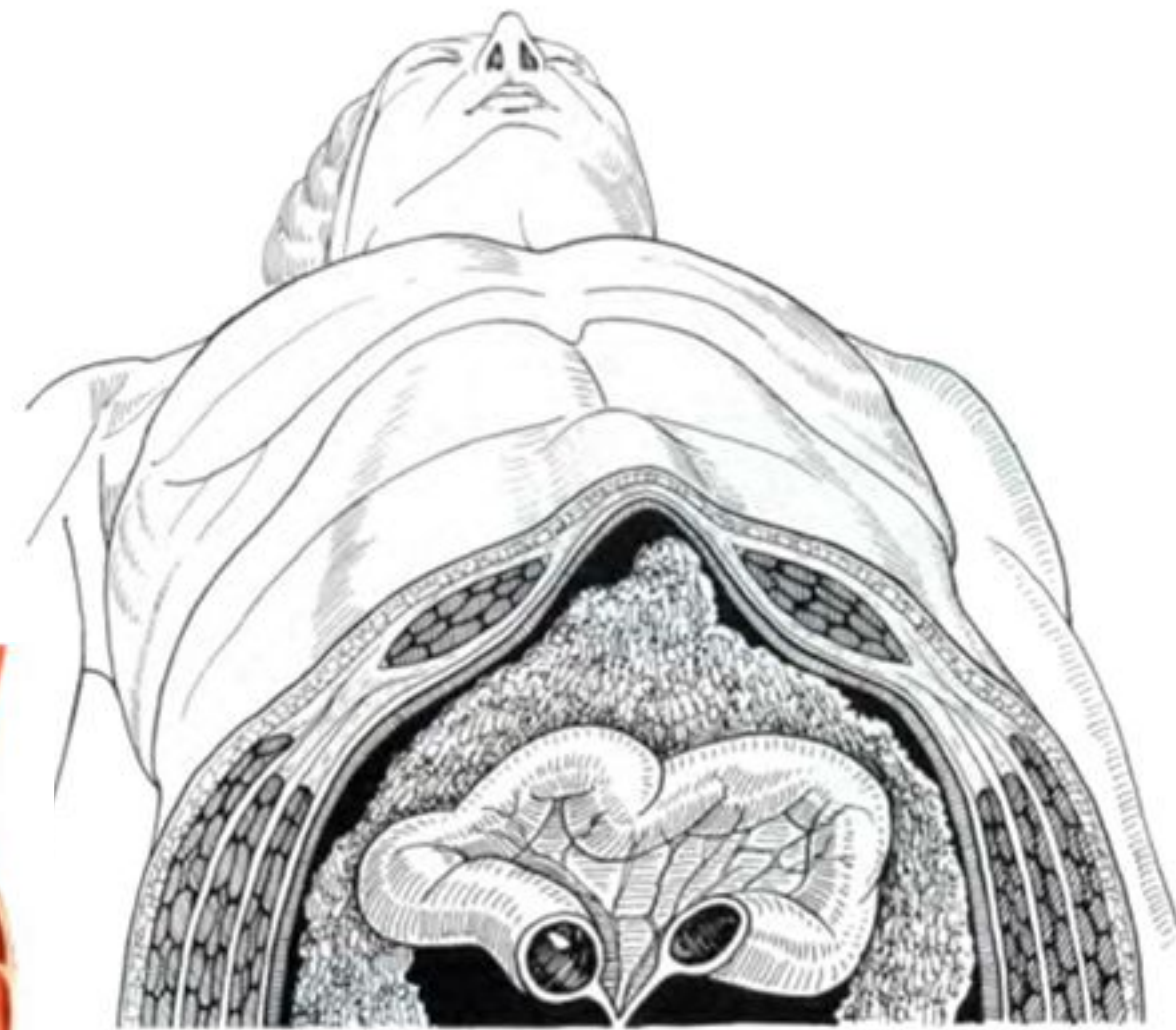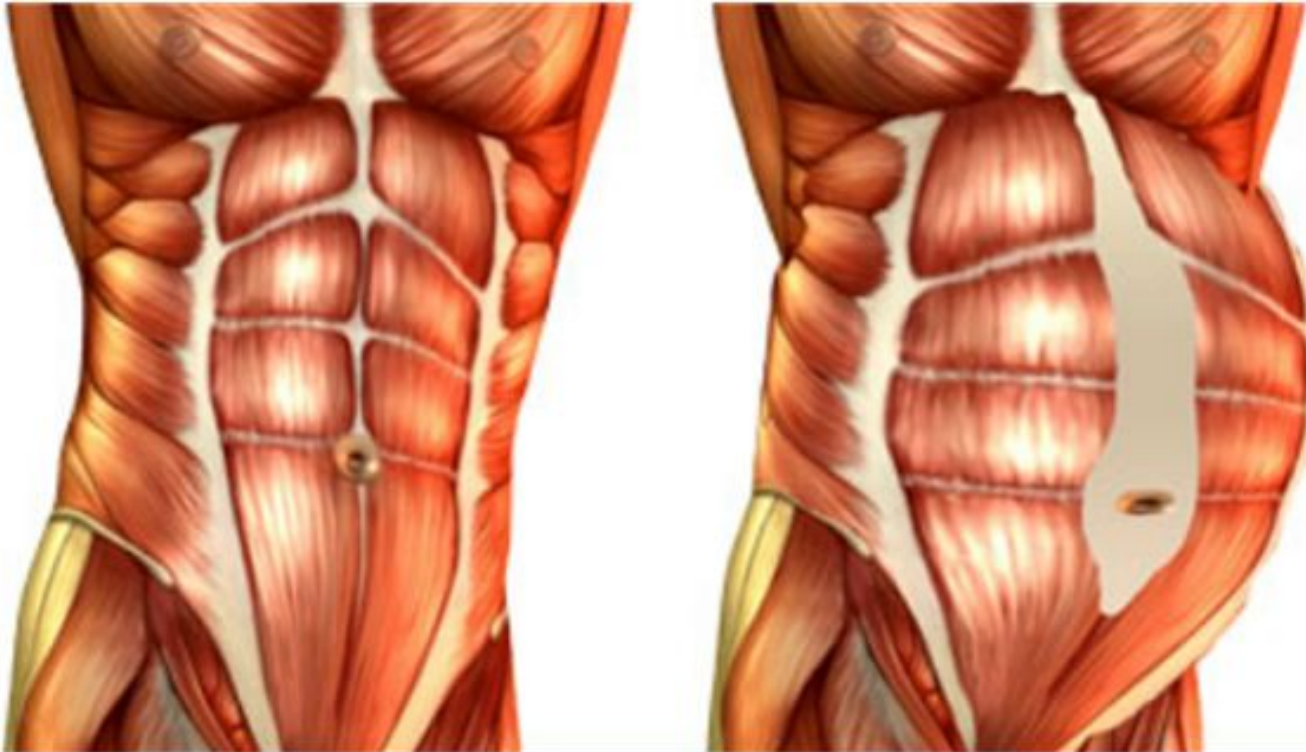- Benign neoplasms including
 - Lipomas
 - Neurofibromas.
- Excision is recommended for symptomatic or enlarging lesions
- Sarcomas are rare (leiomyosarcoma, malignant fibrous histiocytoma, fibrosarcoma, liposarcoma, and rhabdomyosarcoma), dermatofibrosarcoma protuberans, schwannoma, and melanoma.
- Core needle biopsy
- Margins greater than 2 cm, if possible
- Tumor-free margins, applying the same general principles used
- Extensive resection
- Immediate reconstruction with mesh and/or wound coverage with rotational or free myocutaneous flaps



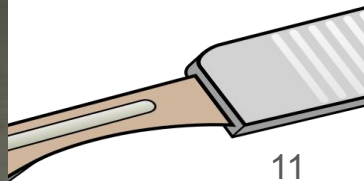
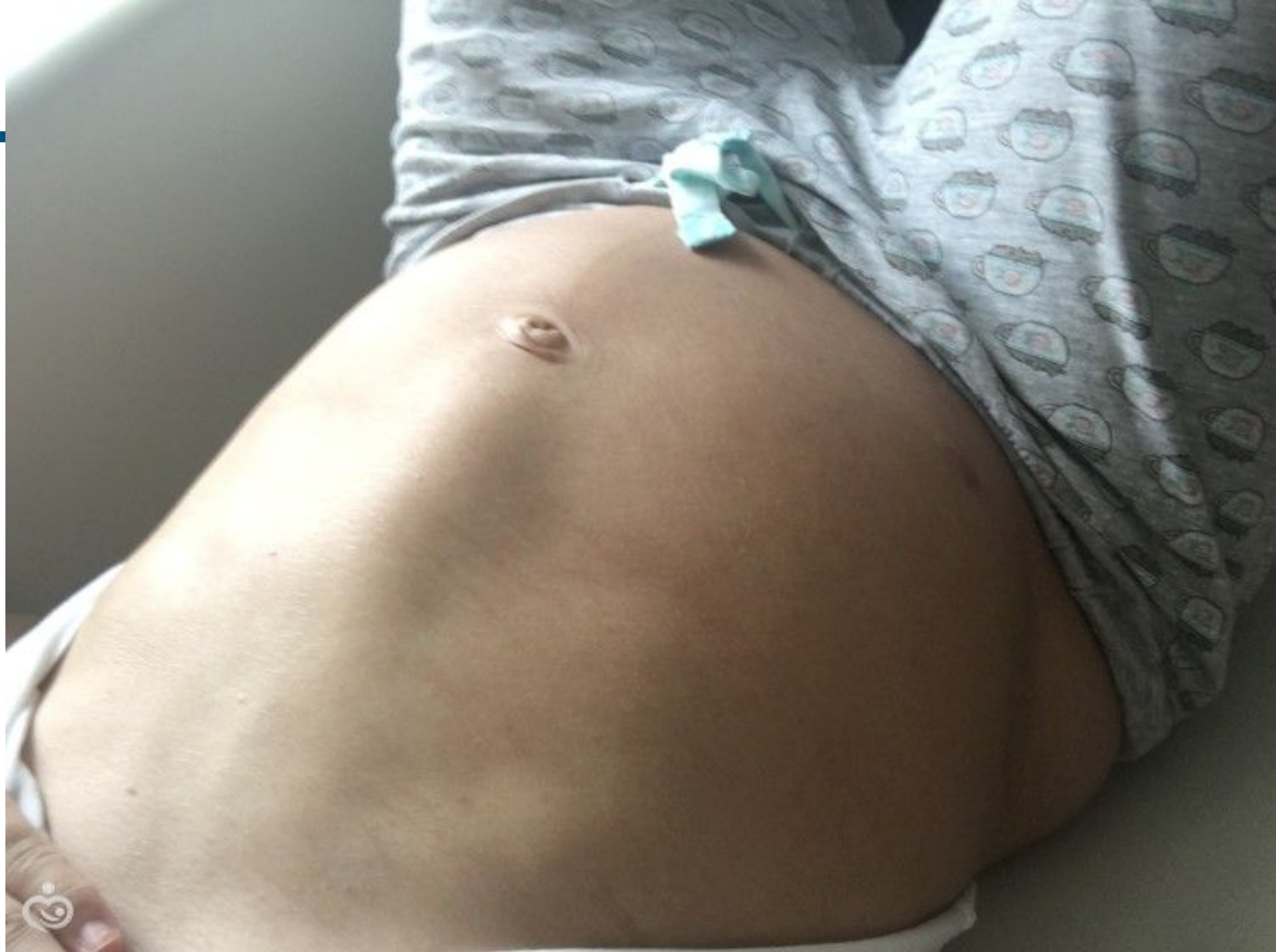Diastasis recti

Diastasis recti

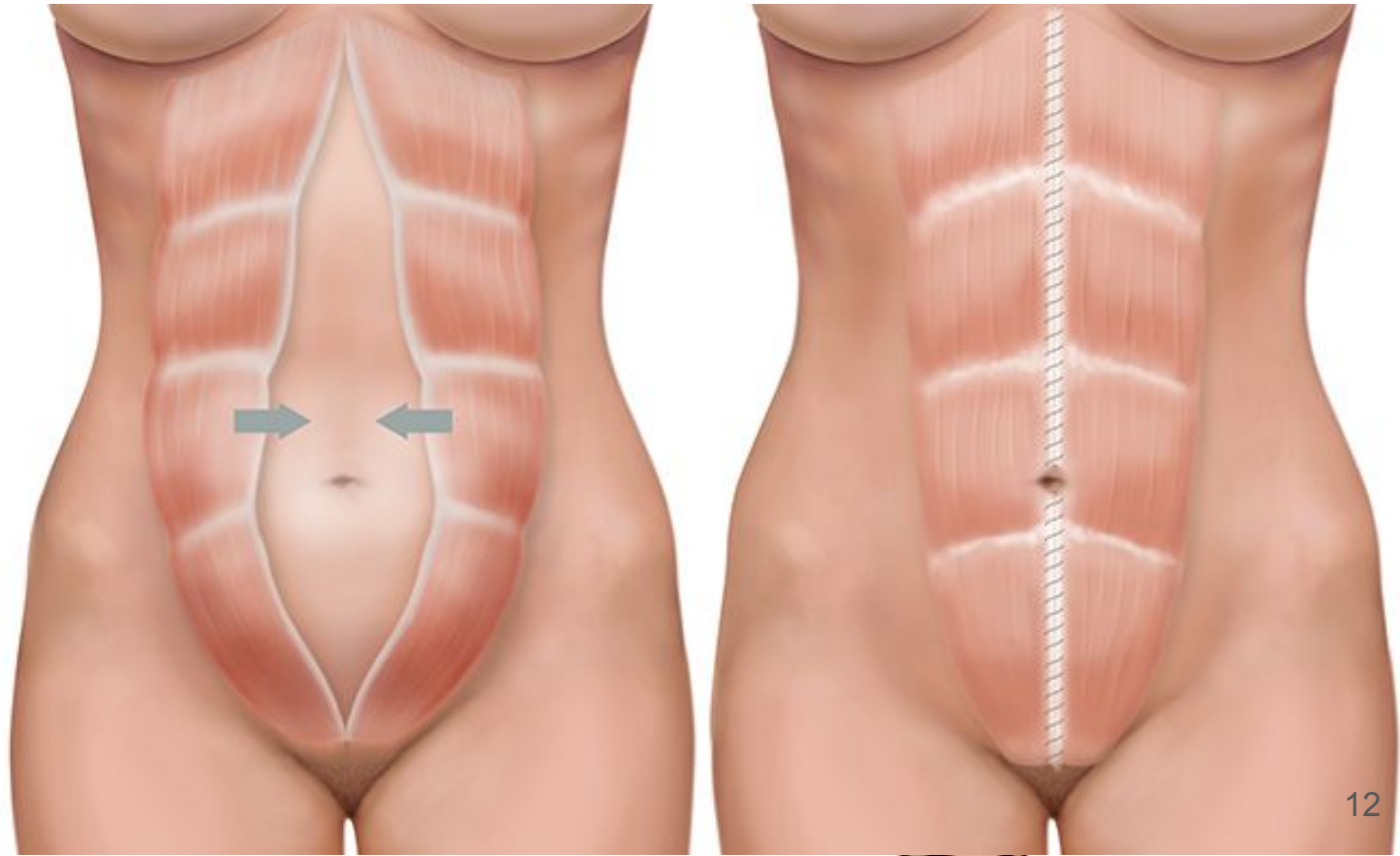
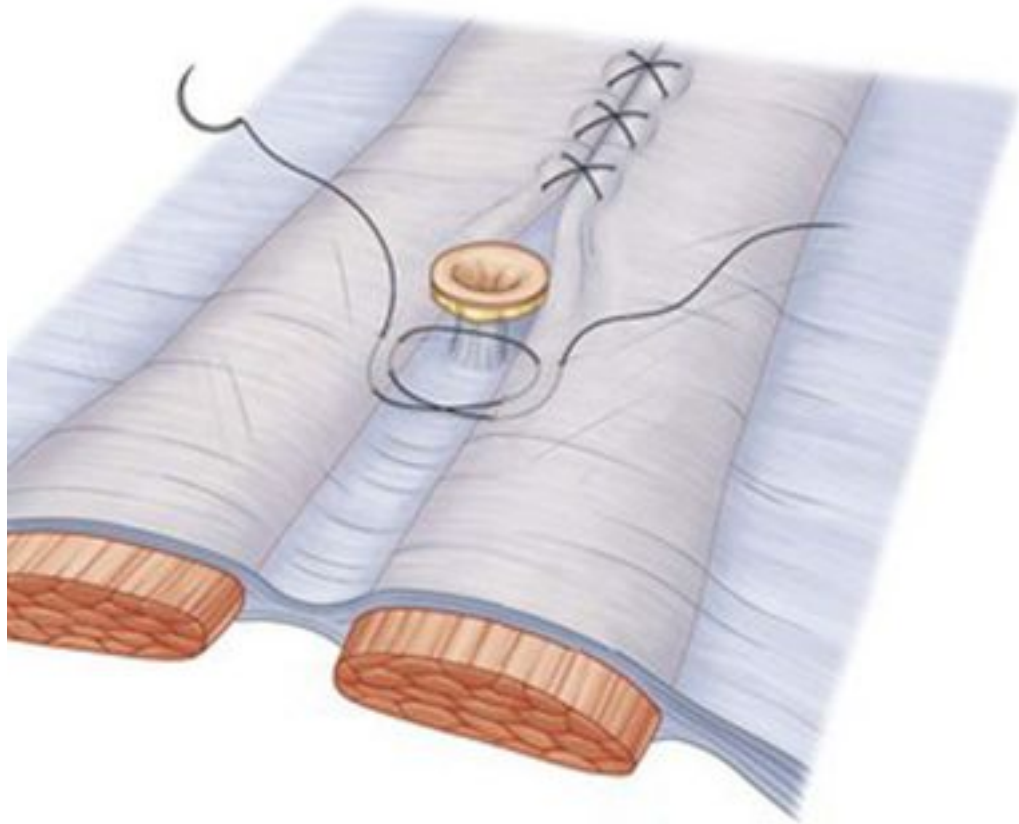
- Bulging of the abdominal wall in the epigastrium
- Mistaken for a ventral hernia



- Advancing age
- After multiple or twin pregnancies
- Surgical correction → plication of the broad midline aponeurosis



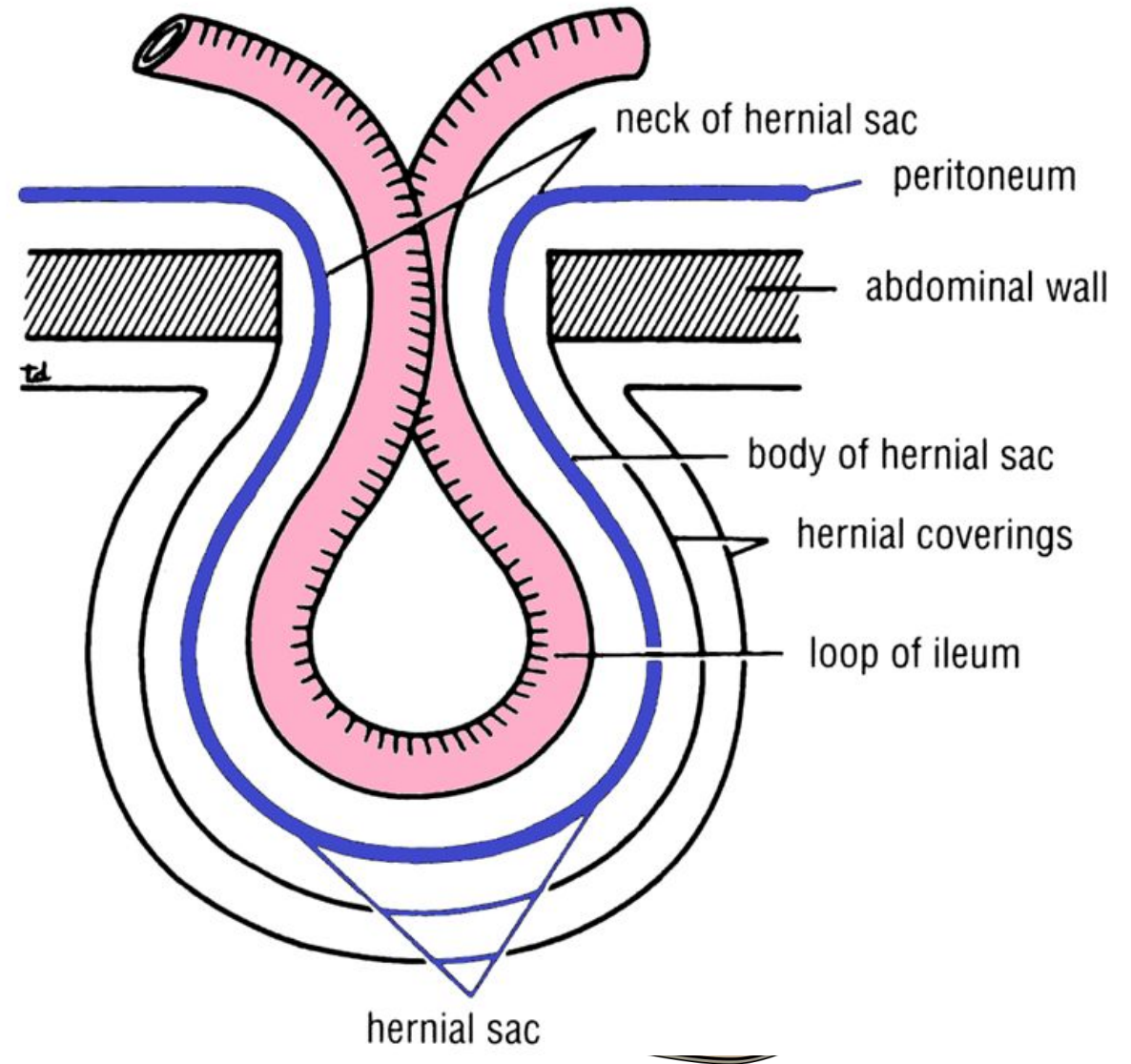
Diastasis recti repair



Hernia

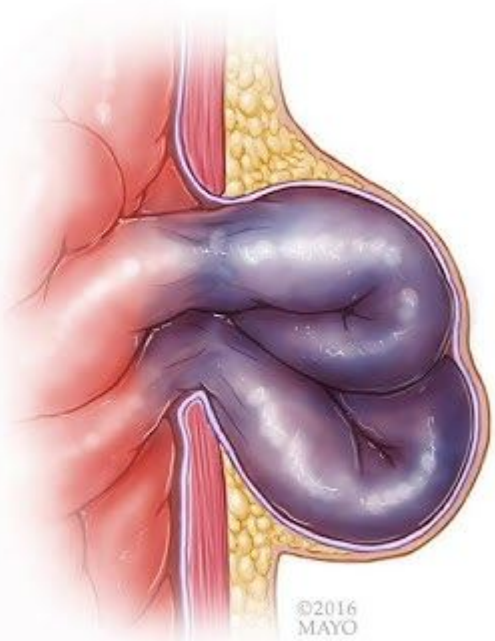
Ventral Hernia

- Defects in the parietal abdominal wall fascia and muscle
 - Abdominal wall incision → incisional hernia
 - Architectural deterioration of the musculoaponeurotic tissues
- Discomfort
- Soft bulge on the anterior abdominal wall
- Positive cough impulse
- A hernia that cannot be reduced → incarcerated=irreducible
- Localized ischemia → Strangulated

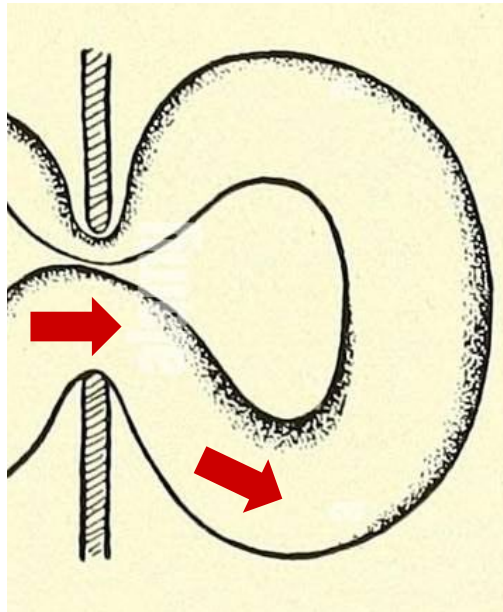


Strangulation

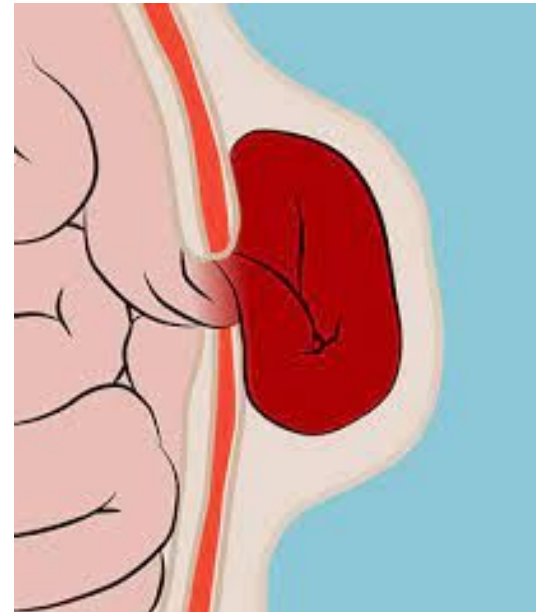
Strangulation Mechanisms



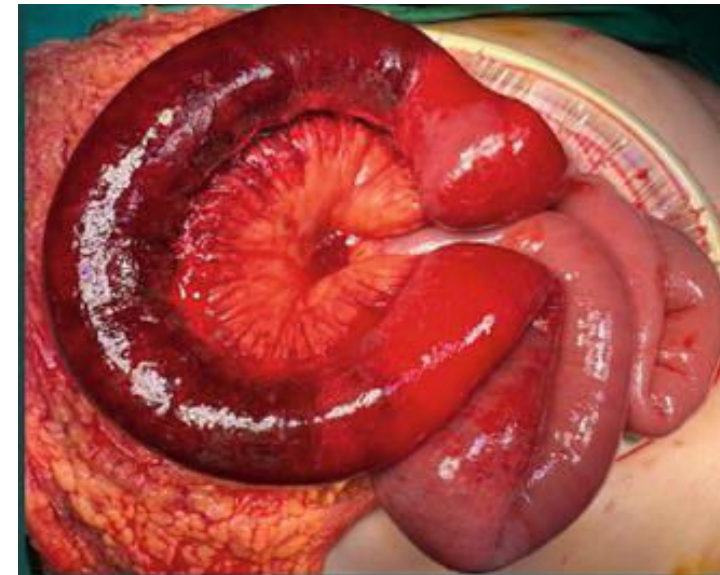
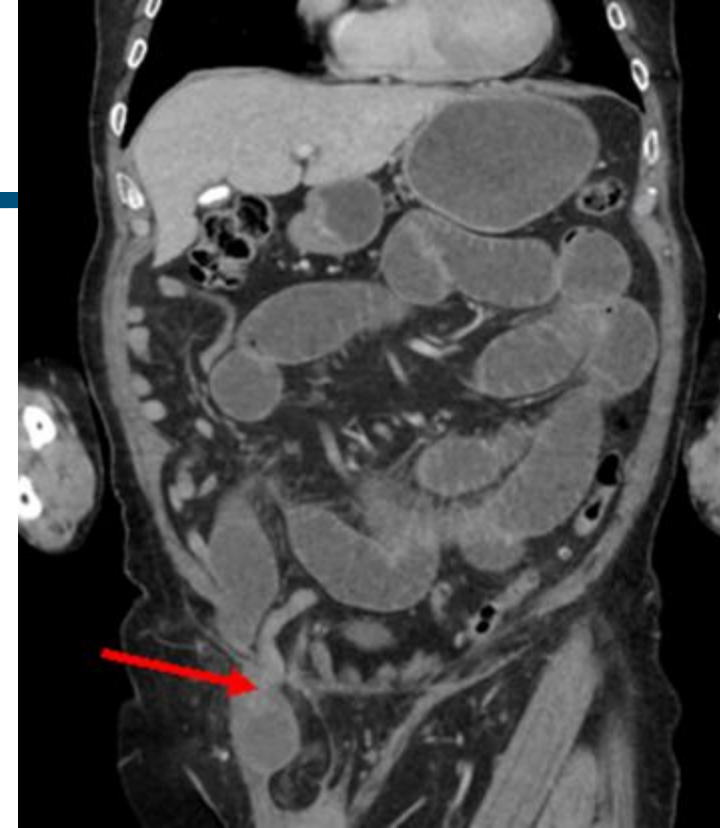
Elastic
Strangulation



Excrement
Strangulation



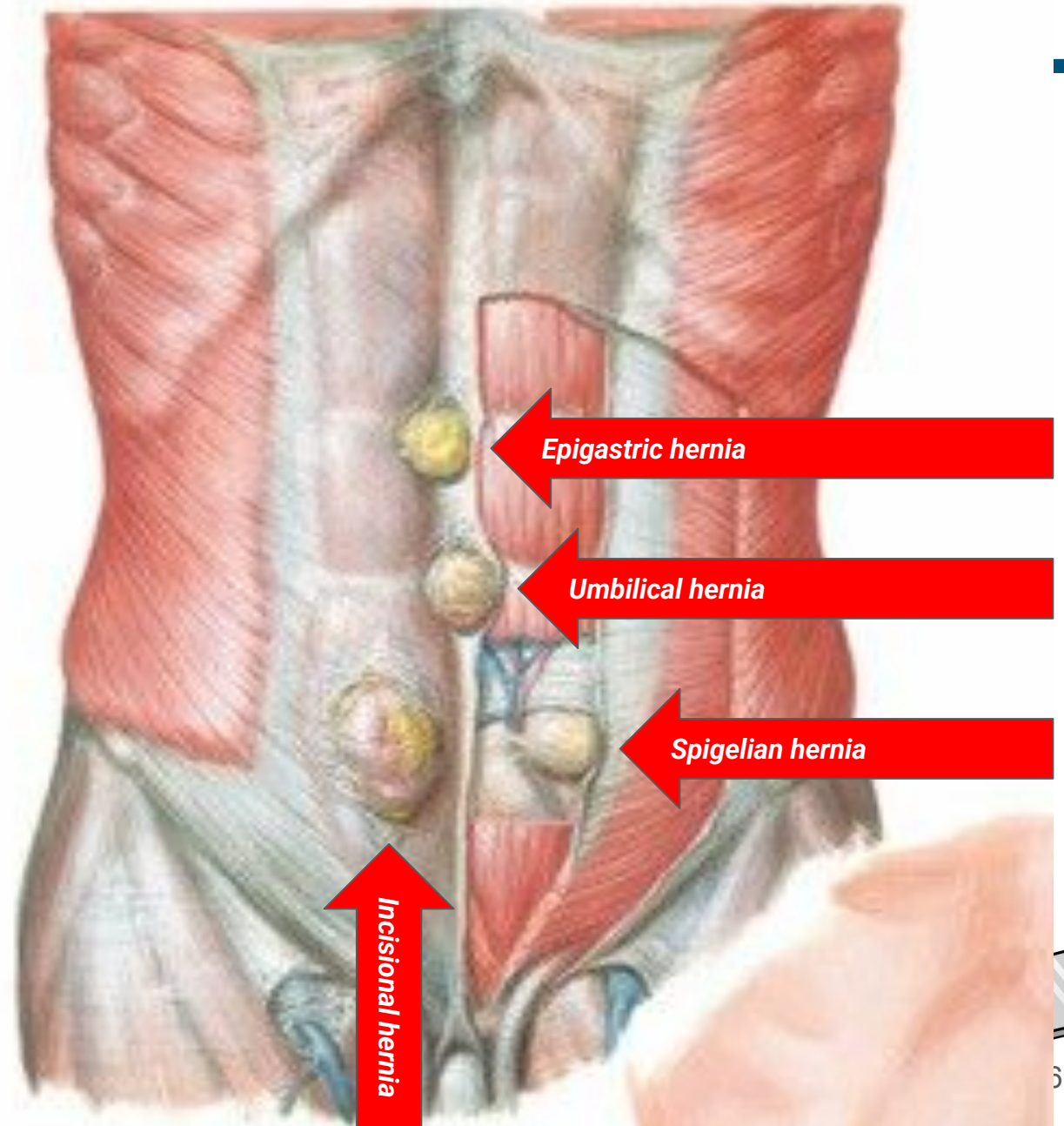
Torsión



ABDOMINAL WALL HERNIAS

- Ventral hernias
 - Epigastric
 - Umbilical
 - Incisional
 - Spigelian
- Groin hernias
 - Inguinal
 - Direct
 - Indirect
 - Combined
 - Femoral
- Pelvic
 - Obturator
 - Sciatic
 - Perineal
- Posterior
 - Lumbar

Ventral Hernias



Ventral hernias

Symptoms:

Bulge

Positive cough impulse

Discomfort

Differential diagnosis of groin hernia

Malignancy
Lymphoma
Retroperitoneal sarcoma
Metastasis
Testicular tumor
Primary testicular
Varicocele
Epididymitis
Testicular torsion
Hydrocele
Ectopic testicle
Undescended testicle
Femoral artery aneurysm or pseudoaneurysm
Lymph node
Sebaceous cyst
Hidradenitis
Cyst of the canal of Nuck (female)
Saphenous varix
Psoas abscess
Hematoma
Ascites

Incisional

Nonincisional

- Epigastric
- Spigelian hernias
- Umbilical
 - –10% of all newborns
 - –Common in premature infants
 - –Most congenital umbilical hernias close spontaneously by 5 years.

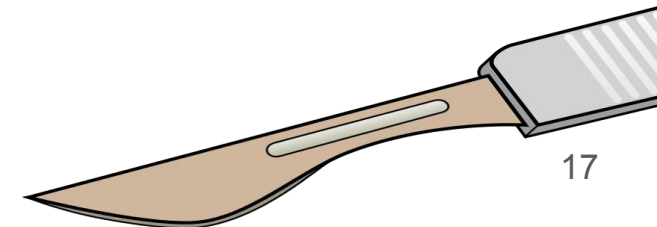
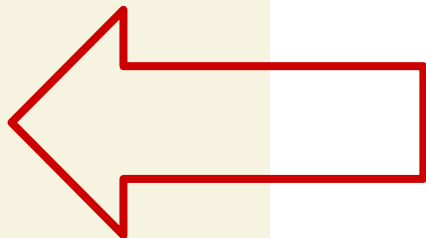


Table 37-4

Connective tissue disorders associated with groin herniation

Osteogenesis imperfecta
 Cutis laxa (congenital elastolysis)
 Ehlers-Danlos syndrome
 Hurler-Hunter syndrome
 Marfan's syndrome
 Congenital hip dislocation in children
 Polycystic kidney disease
 α_1 -Antitrypsin deficiency
 Williams syndrome
 Androgen insensitivity syndrome
 Robinow's syndrome
 Serpentine fibula syndrome
 Alport's syndrome
 Tel Hashomer camptodactyly syndrome
 Leriche's syndrome
 Testicular feminization syndrome
 Rokitansky-Mayer-Küster syndrome
 Goldenhar's syndrome
 Morris syndrome
 Gerhardt's syndrome
 Menkes' syndrome
 Kawasaki disease
 Pfannenstiel syndrome
 Beckwith-Wiedemann syndrome
 Rubinstein-Taybi syndrome
 Alopecia-photophobia syndrome



Causes of the Hernia

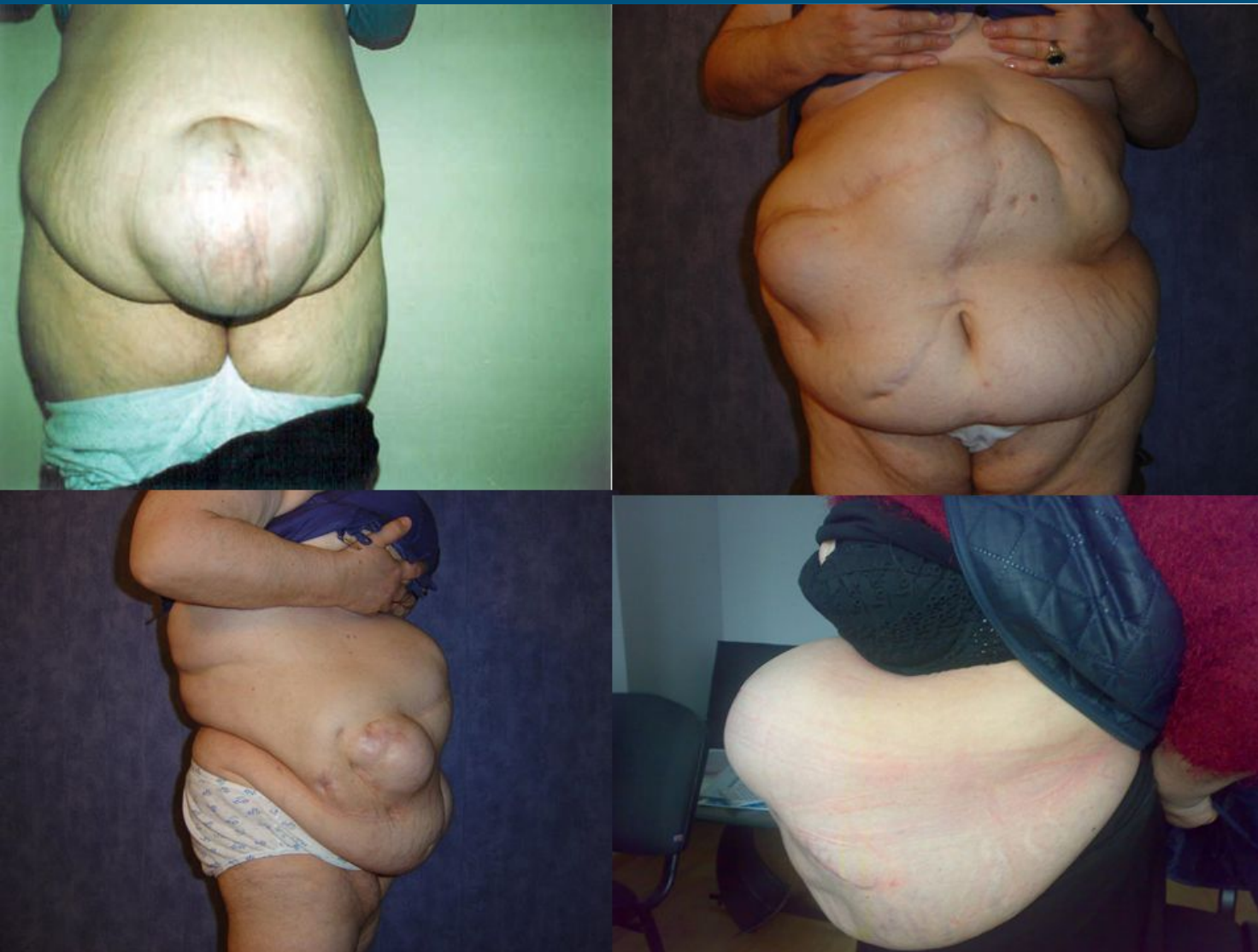1. Weakness of the abdominal wall
 - a. Congenitally imperfect connective tissue
 - b. Denervation of the abdominal wall
 - c. Devascularization of the abdominal wall
2. Damage of the abdominal wall structures
 - a. Elevation of the intra-abdominal pressure
 - b. Surgery
 - c. Trauma



Table 37-3

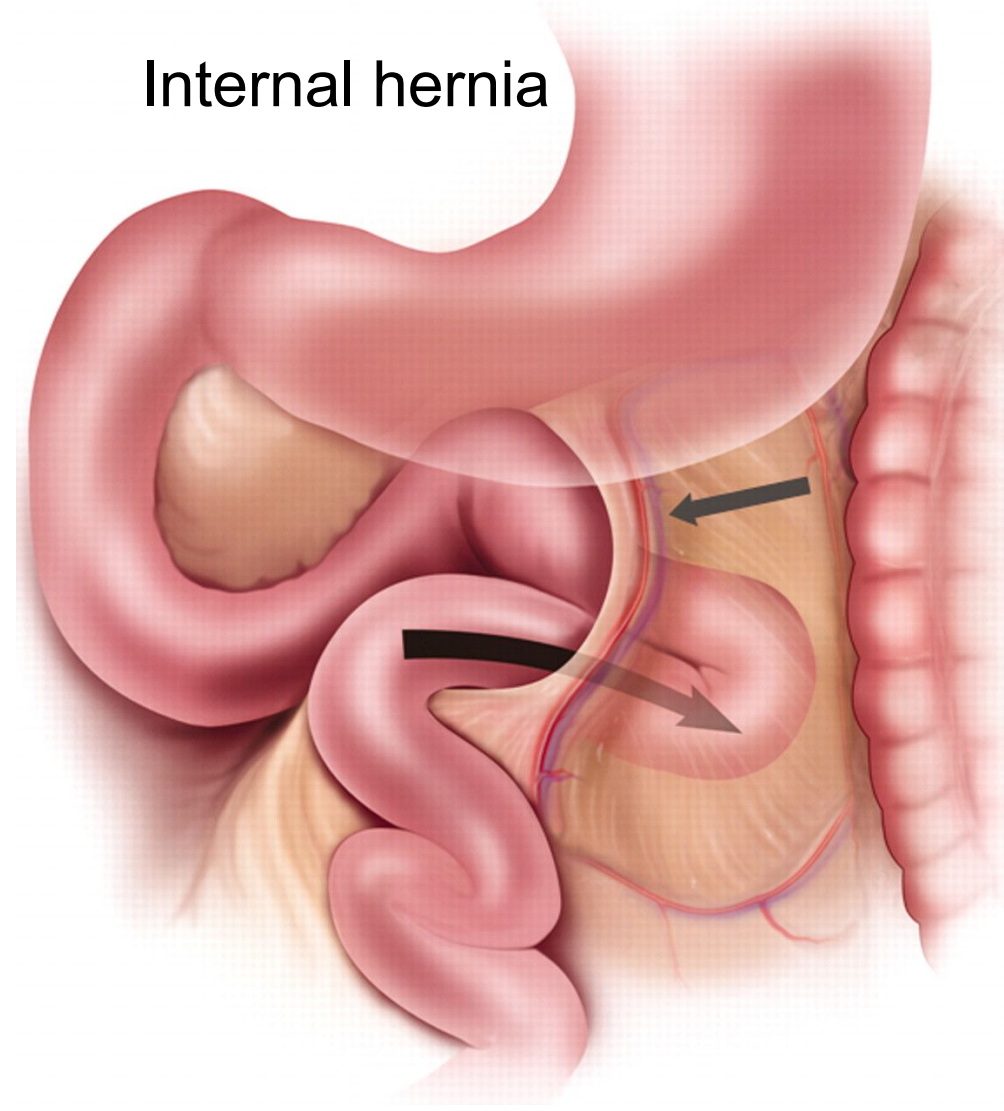
Presumed causes of groin herniation

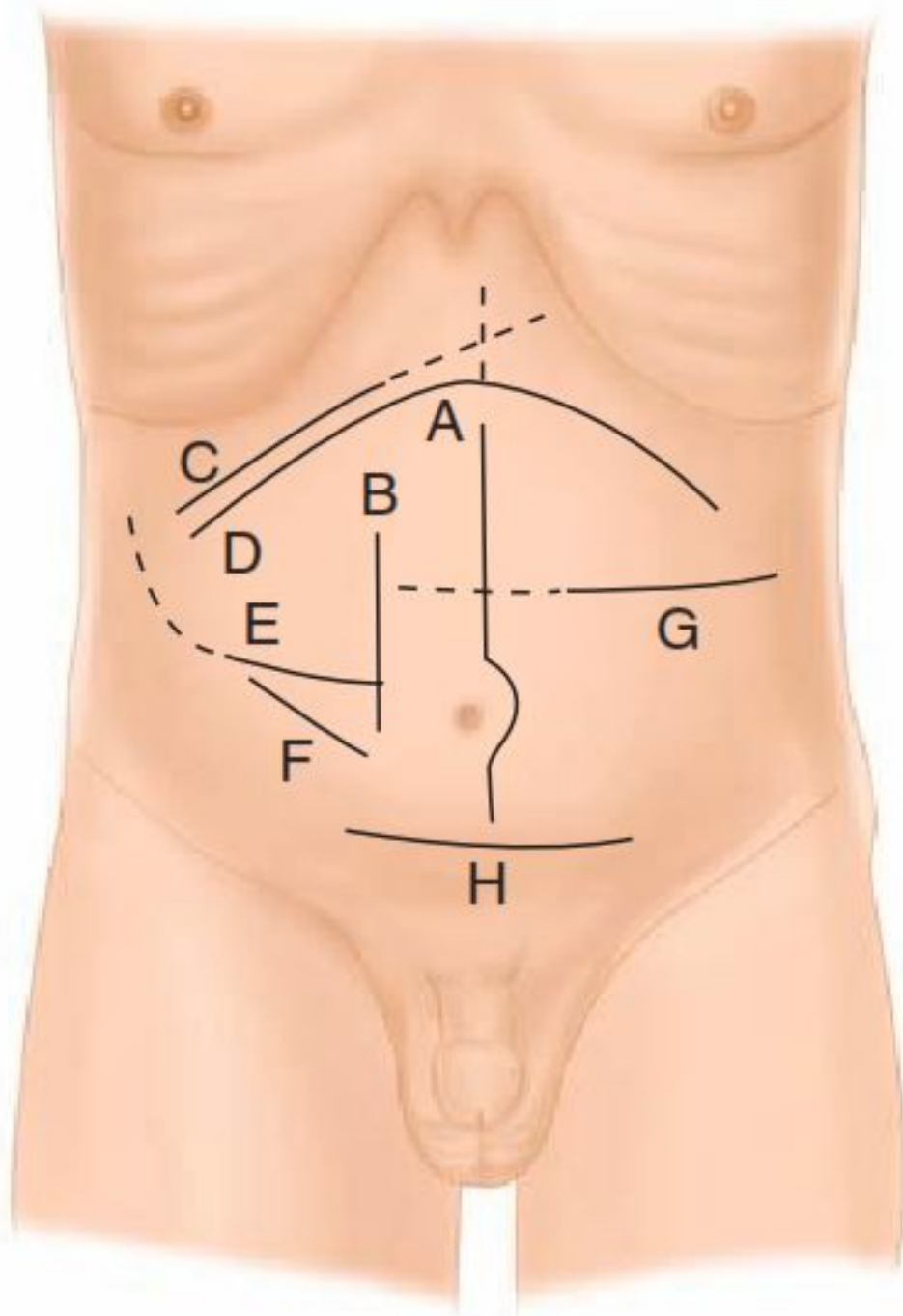
Coughing
 Chronic obstructive pulmonary disease
 Obesity
 Straining
 Constipation
 Prostatism
 Pregnancy
 Birthweight <1500 g
 Family history of a hernia
 Valsalva's maneuver
 Ascites
 Upright position
 Congenital connective tissue disorders
 Defective collagen synthesis
 Previous right lower quadrant incision
 Arterial aneurysms
 Cigarette smoking
 Heavy lifting
 Physical exertion



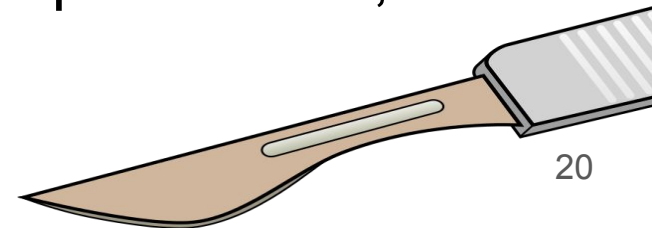
Incisional Hernia

Internal hernia

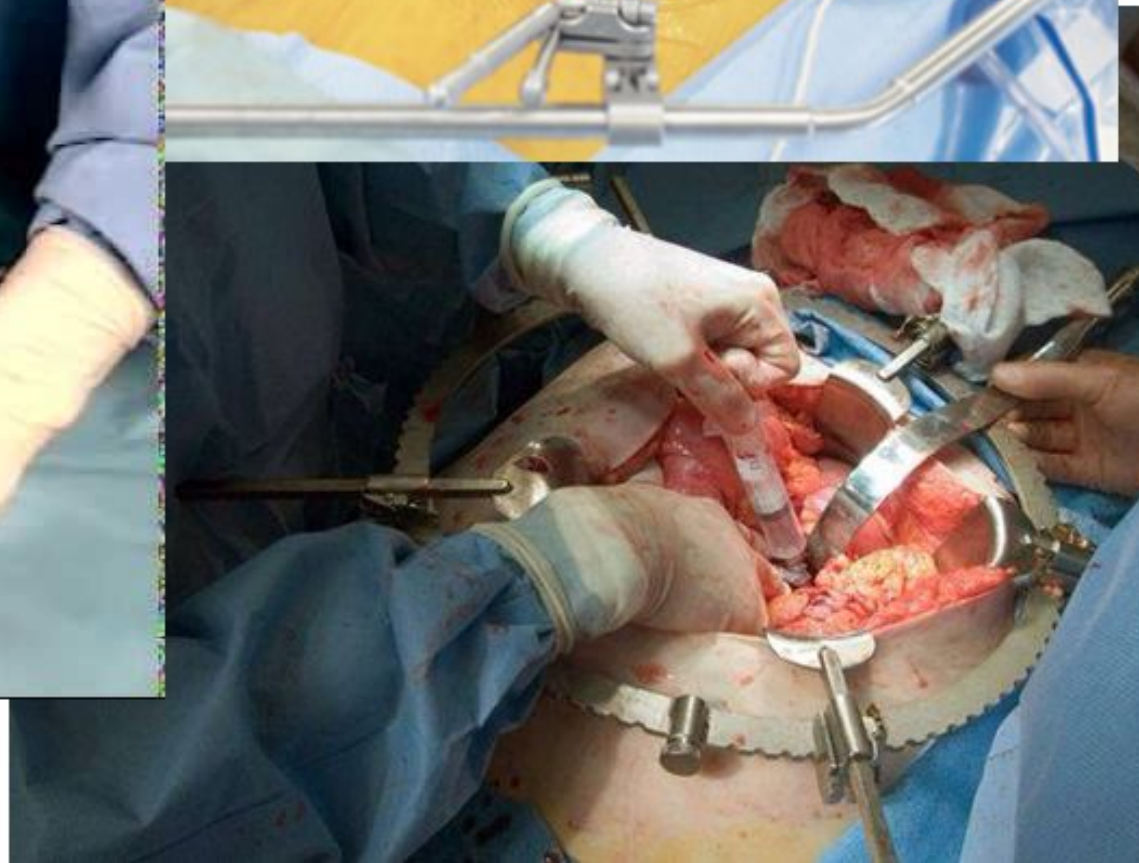
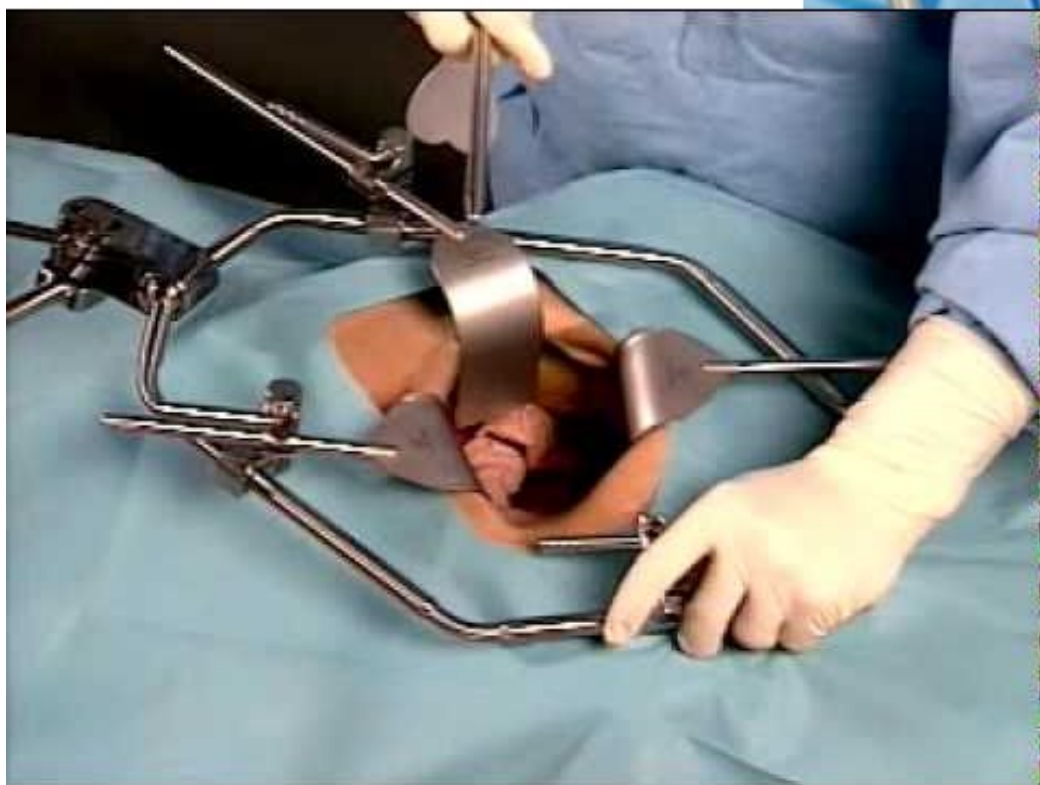
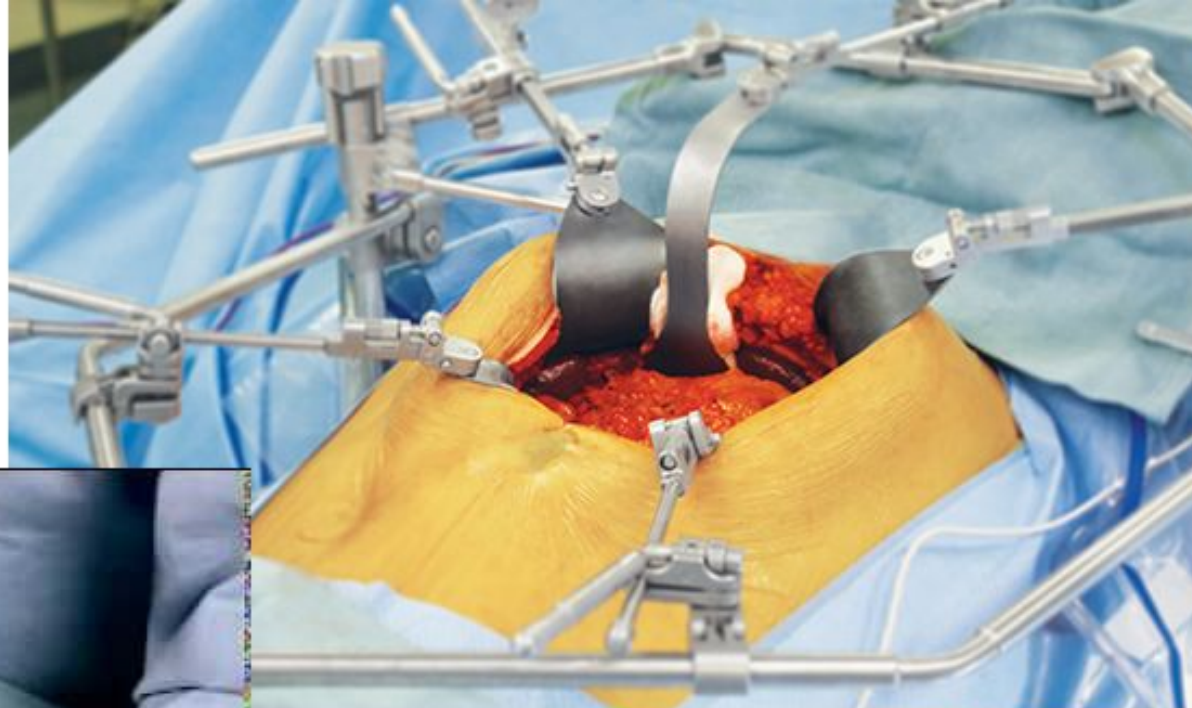


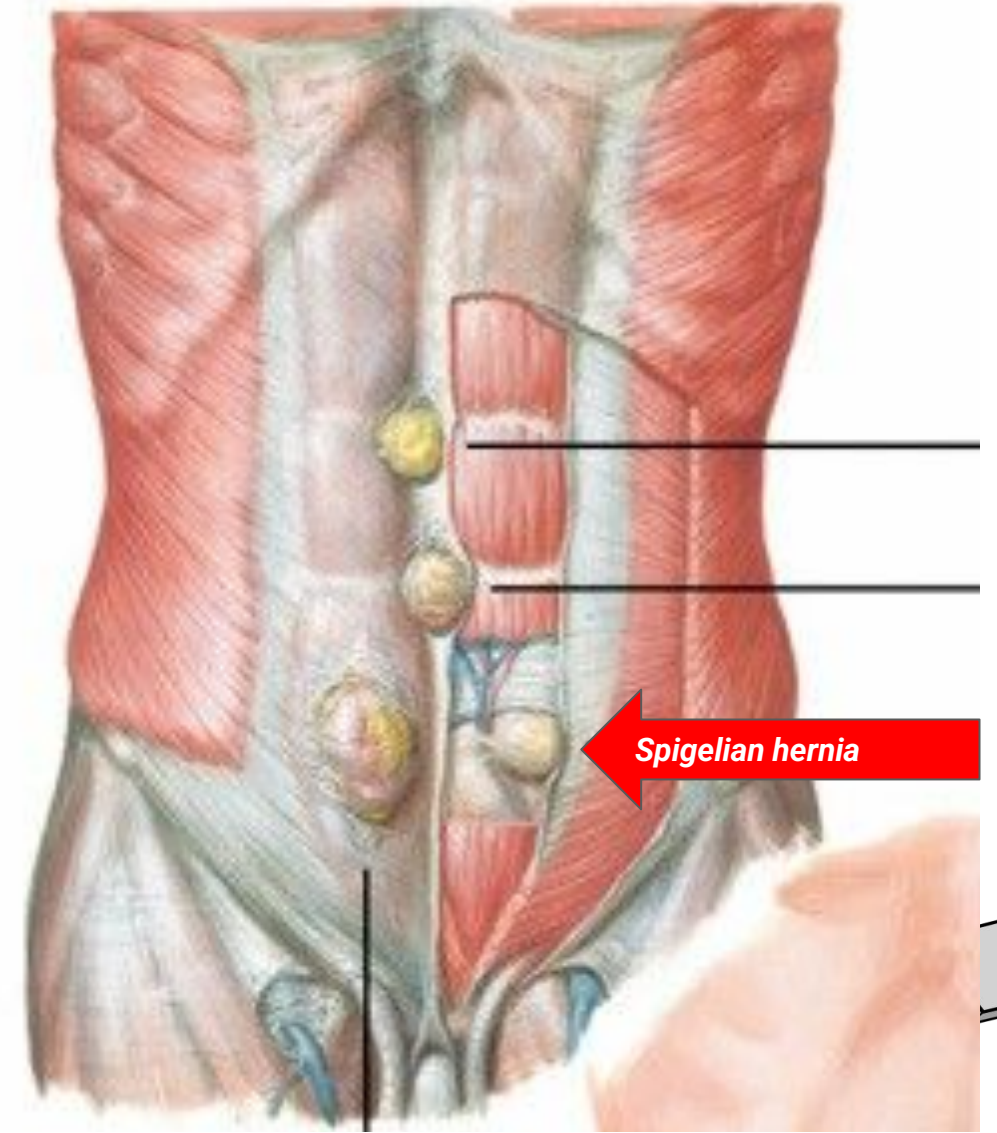
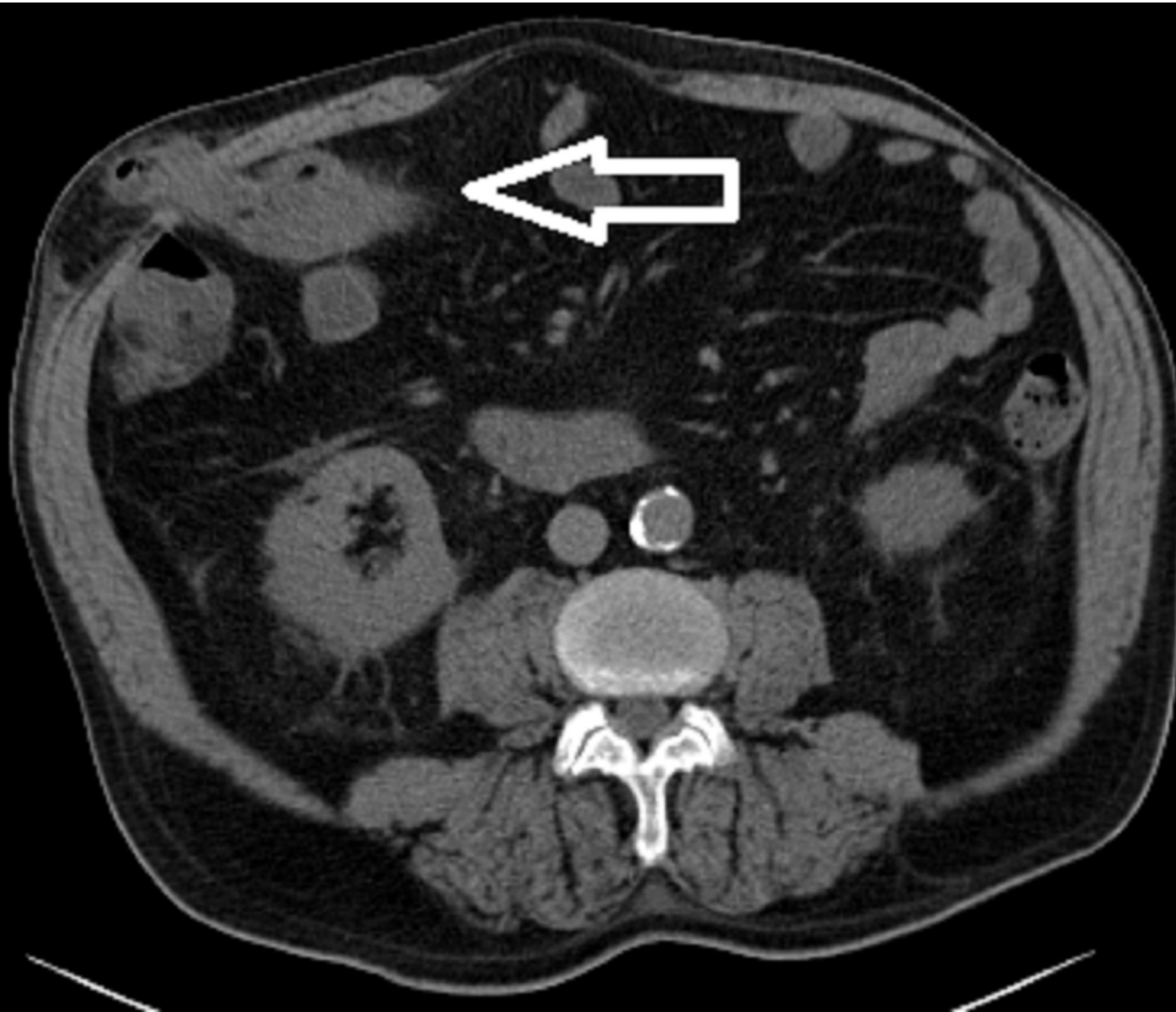
- Midline incisions
- Paramedian
- Incisions lateral to the midline made with transverse or oblique orientations
- McBurney incision for appendectomy
- Subcostal incisions on the right (Kocher incision for cholecystectomy) or left (for splenectomy)
- Pfannenstiel incision, used commonly for pelvic procedures,



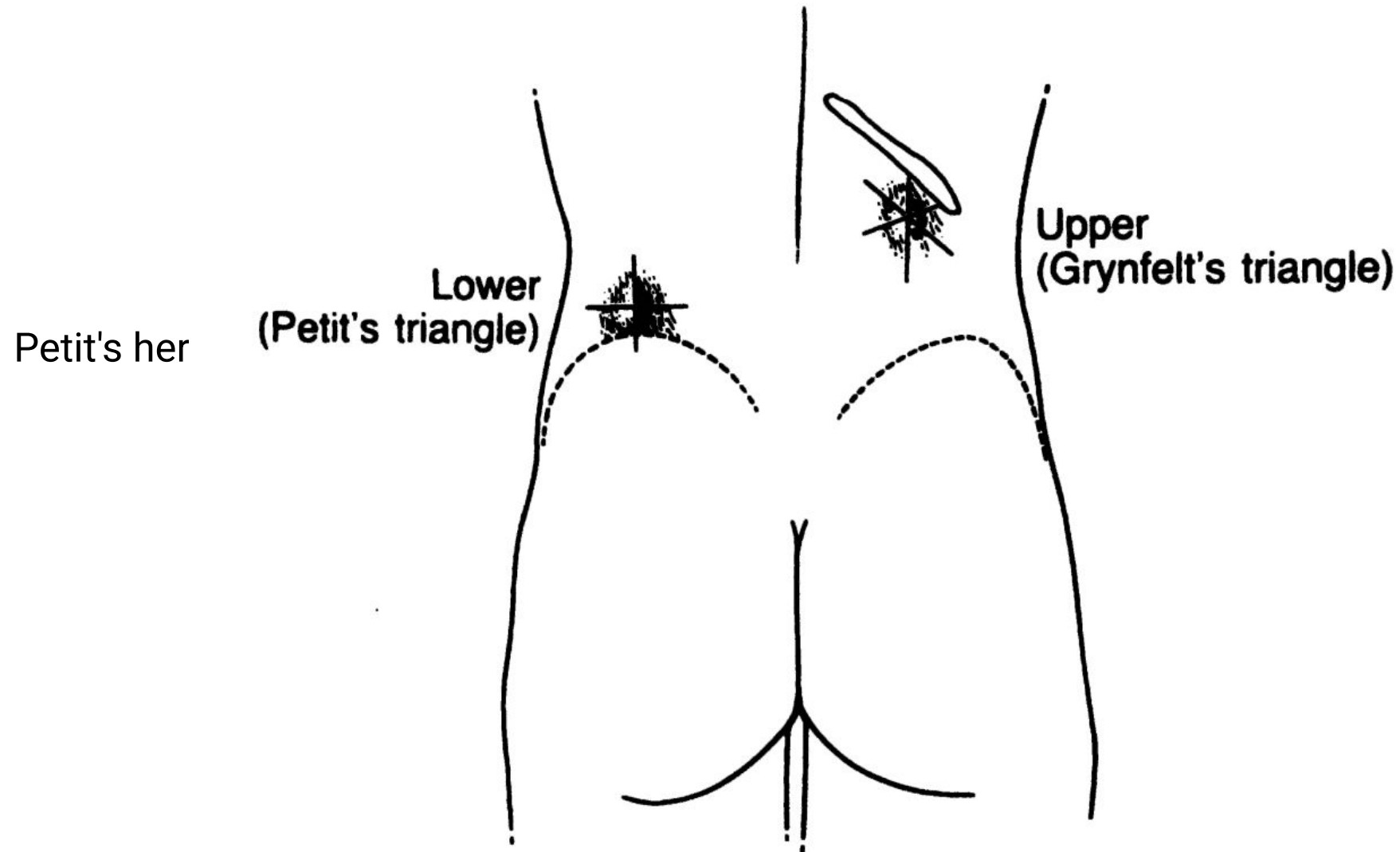
Bookwalter,
Omni-Tract and
Thompson retractors



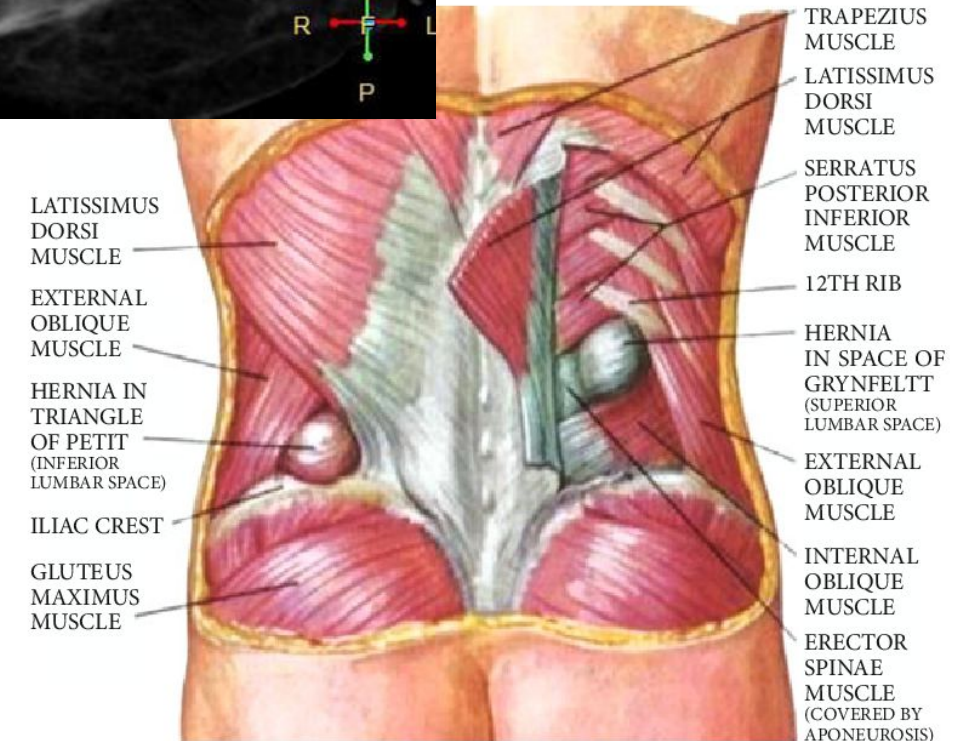
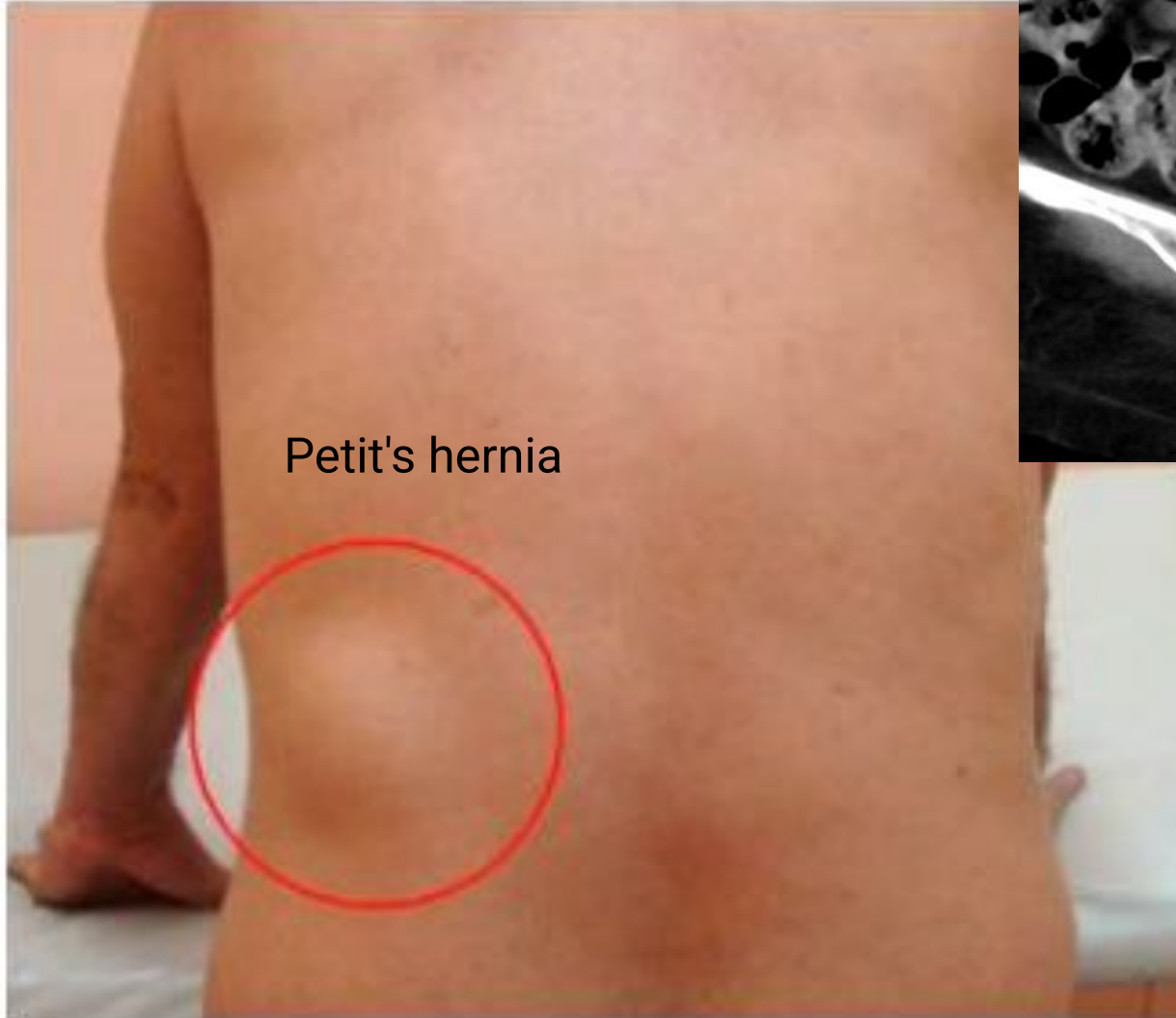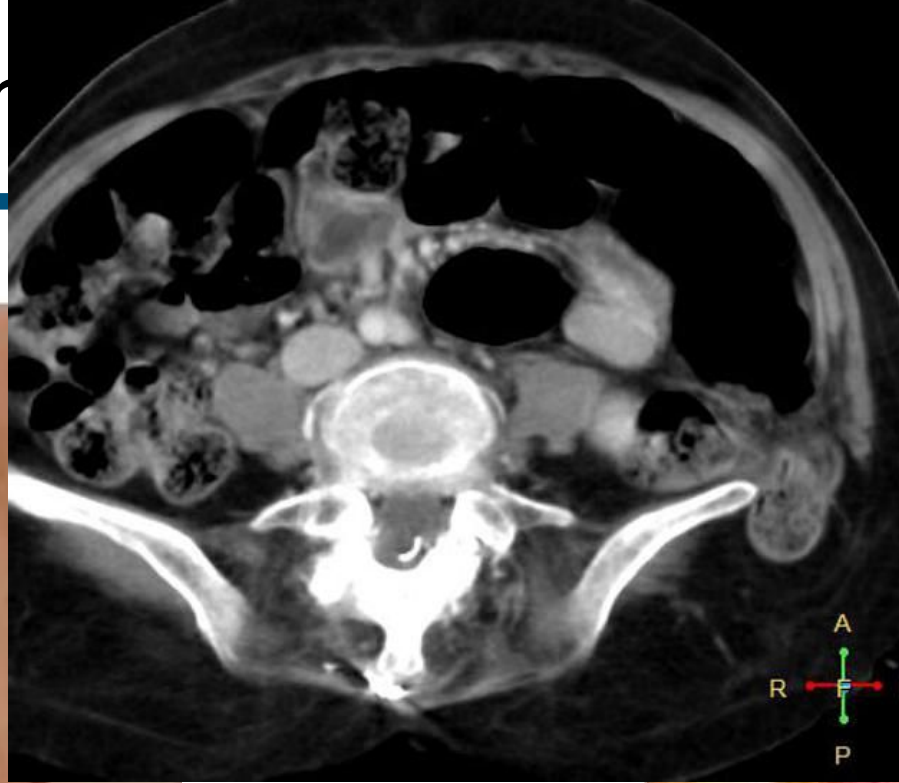Spigelian hernia



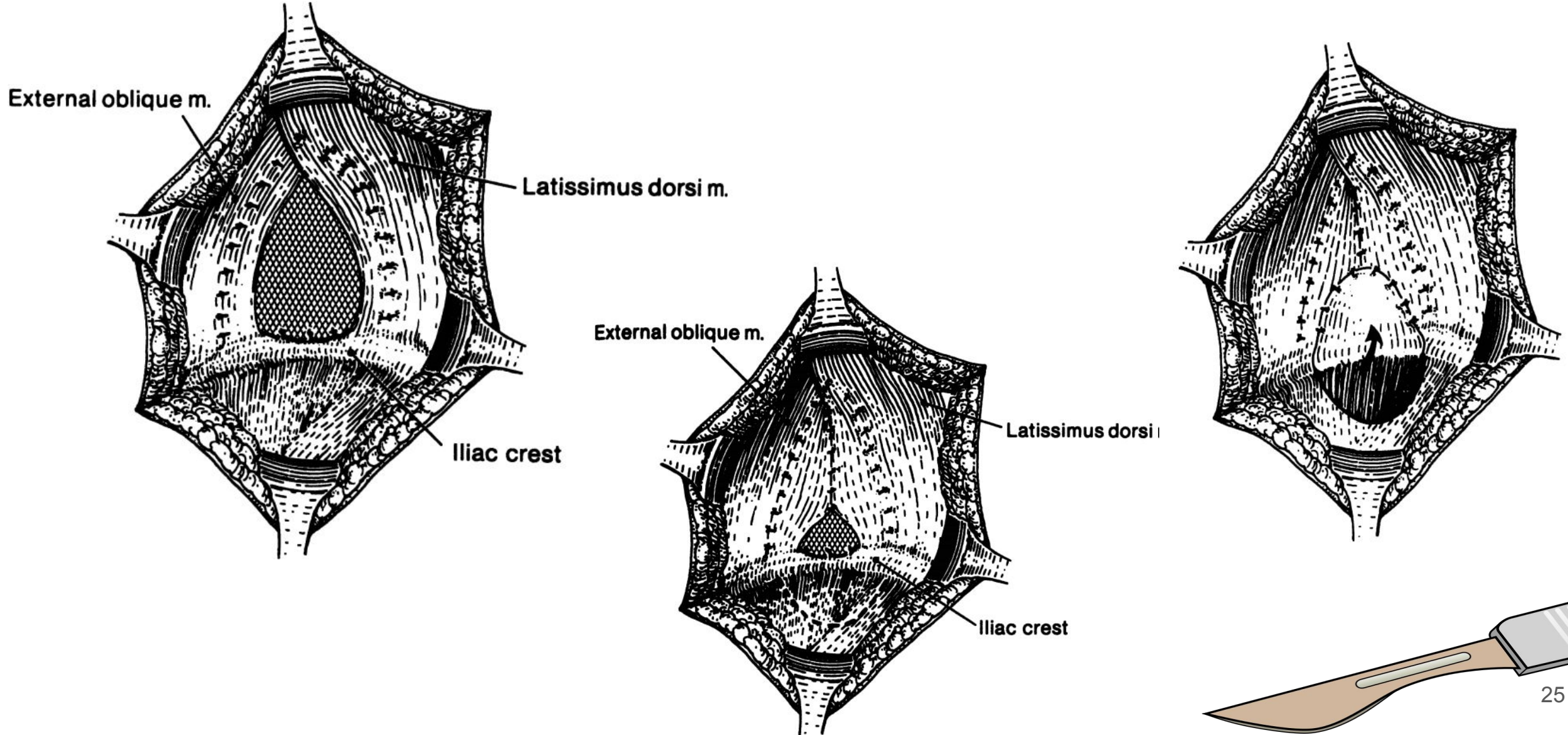
Lumbar Hernia



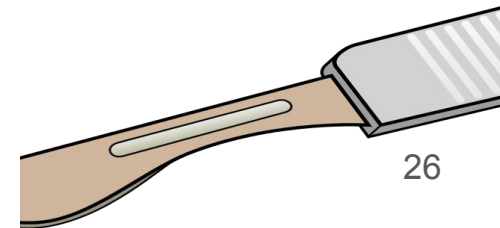
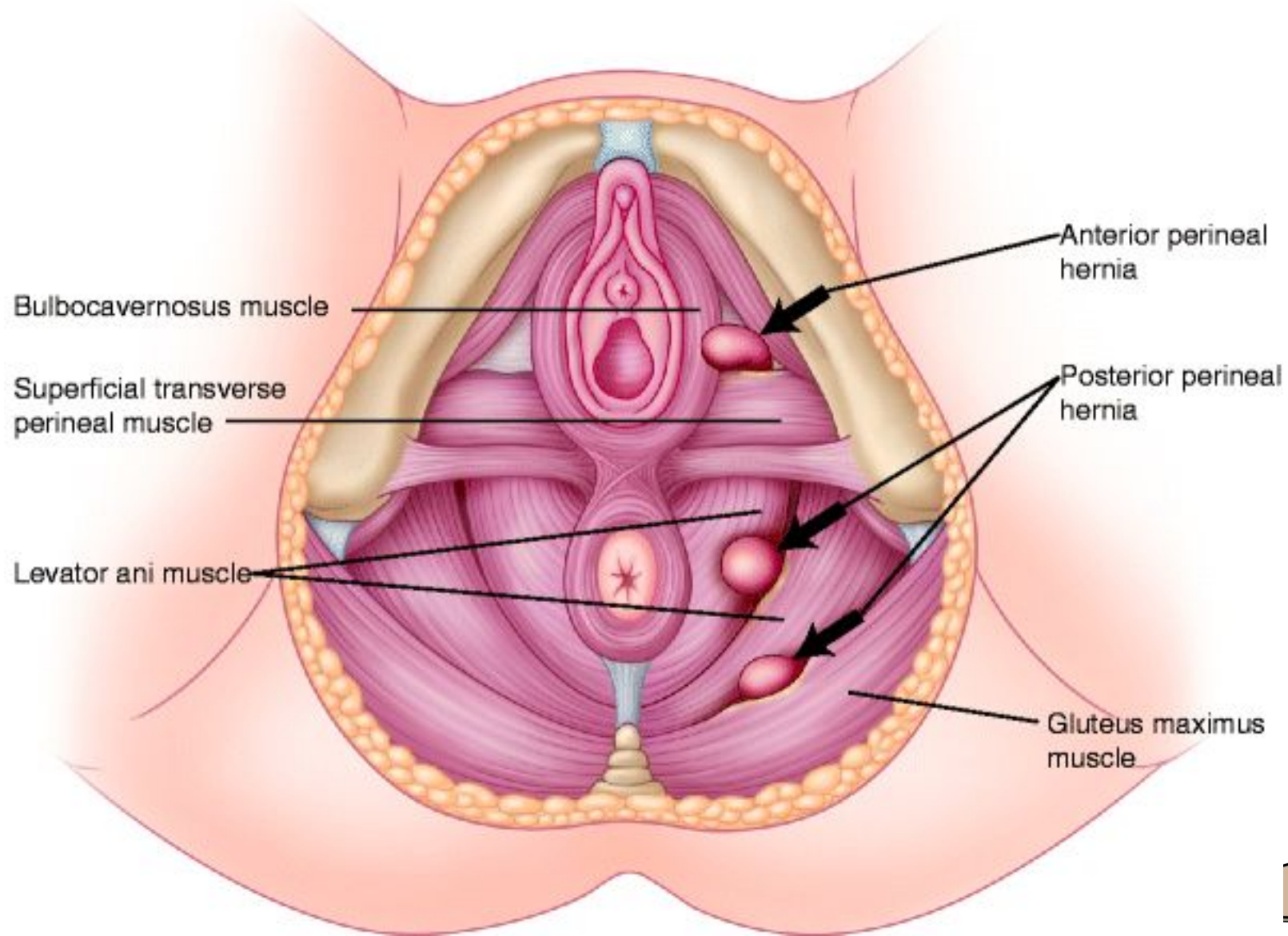
Lumbar Hern



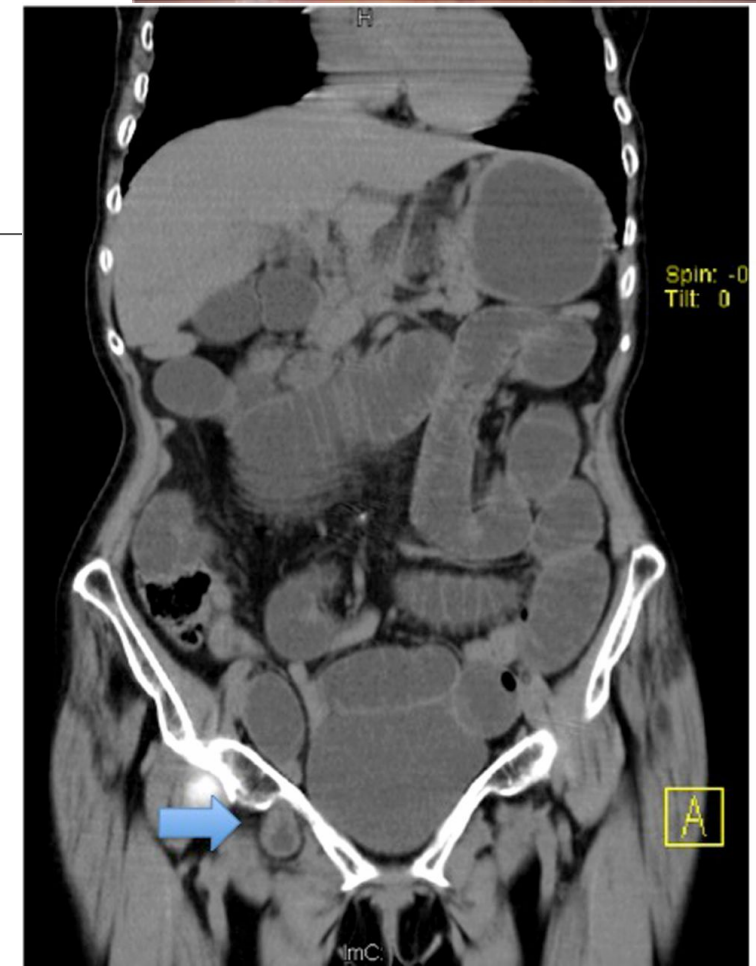
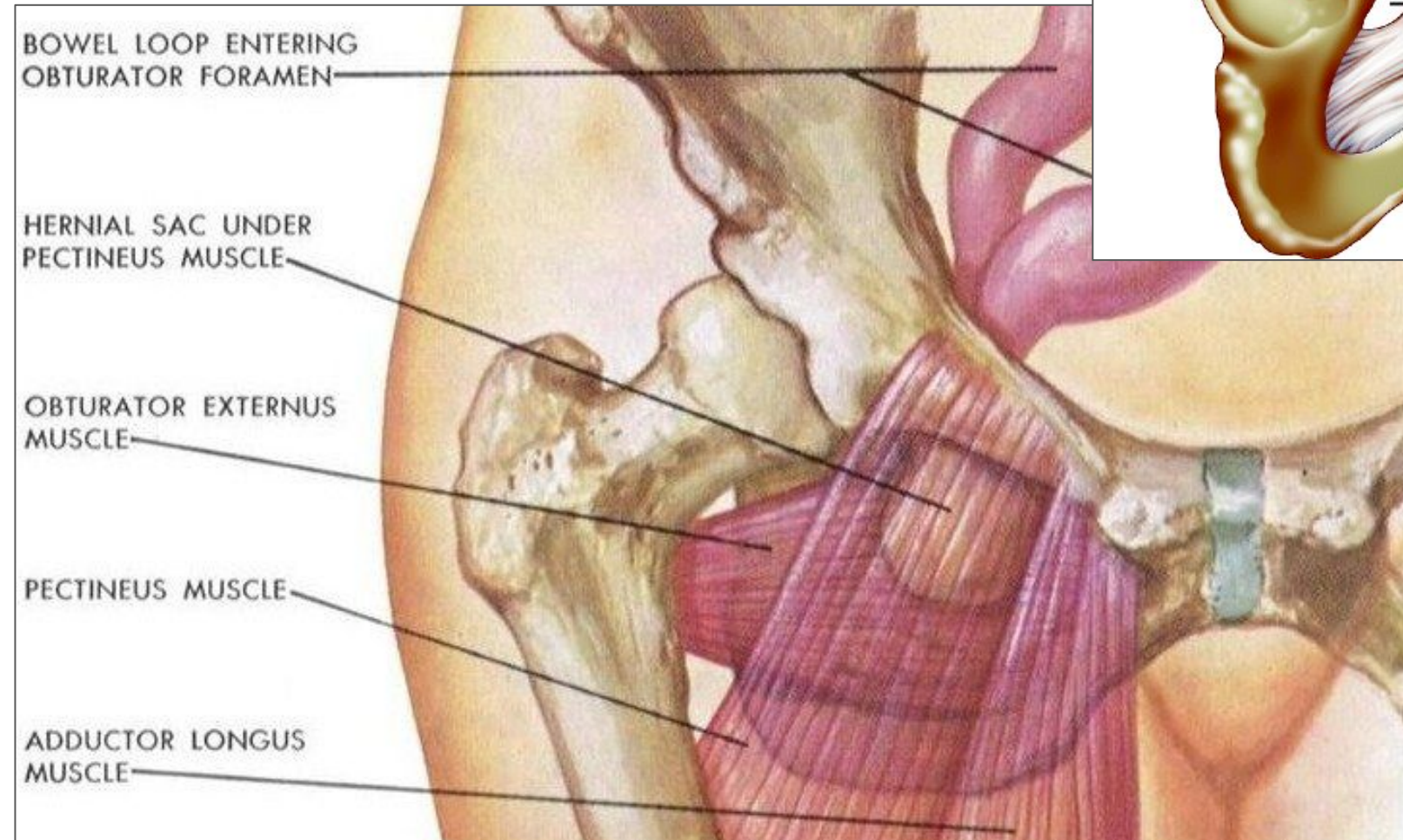
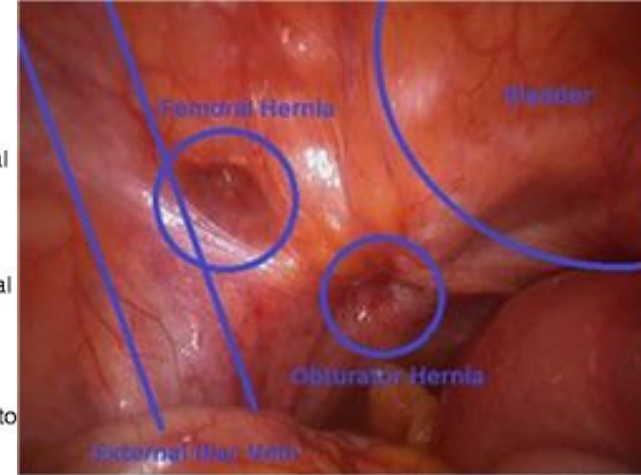
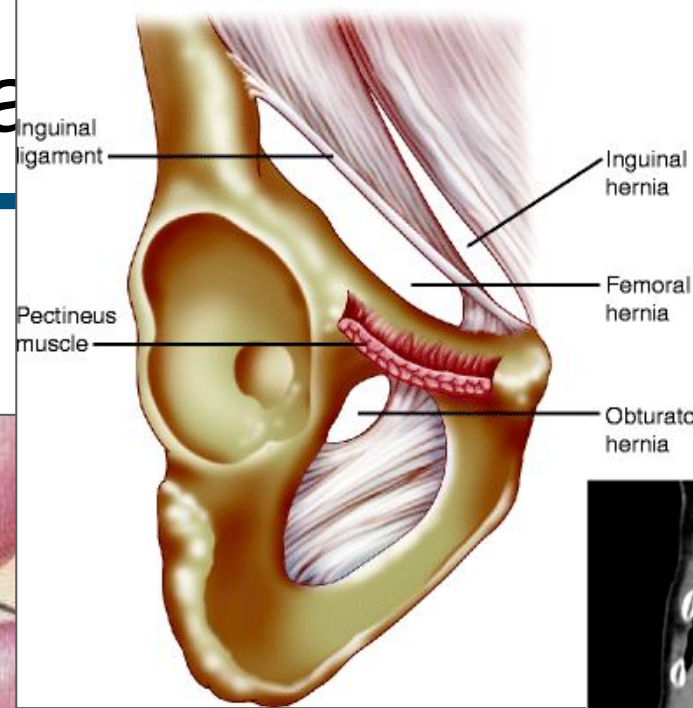
Lumbar Hernia Repair



Pelvic hernias

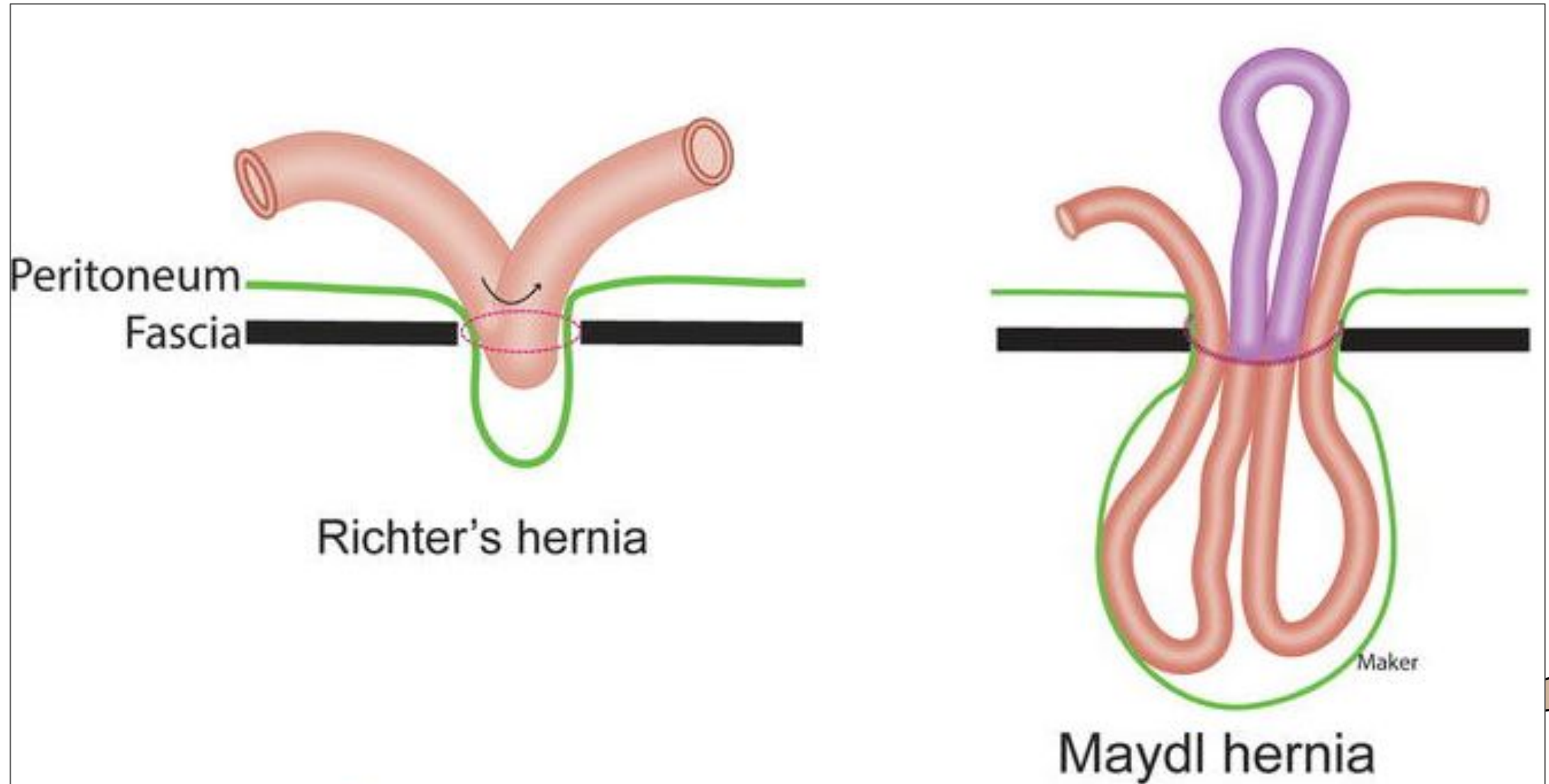


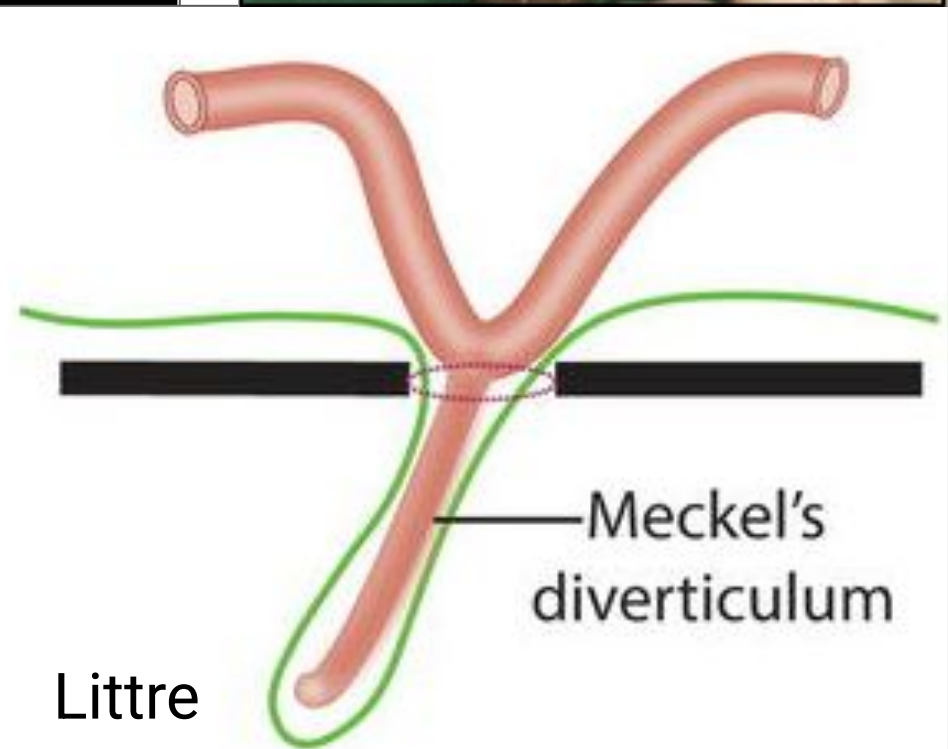
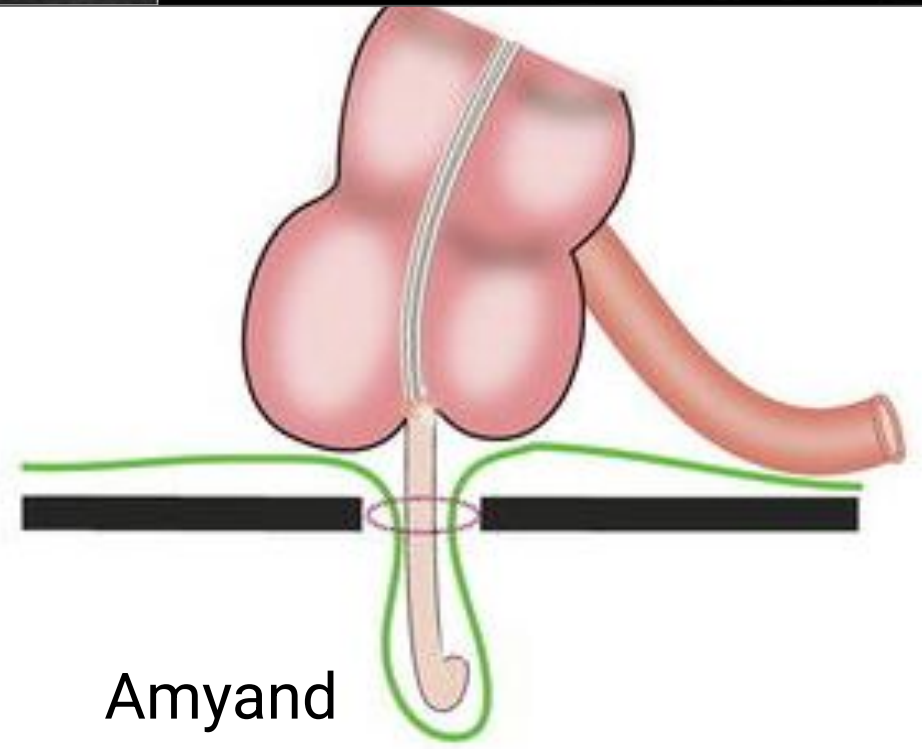
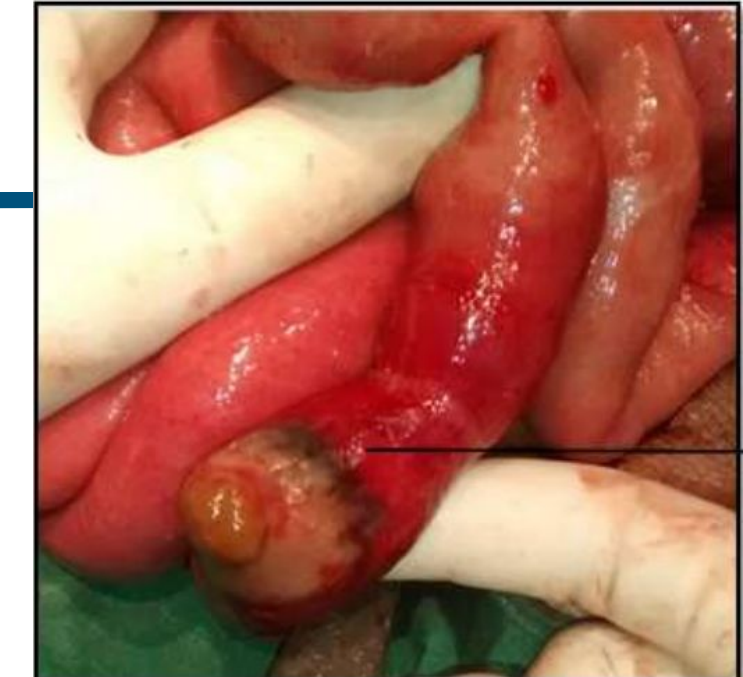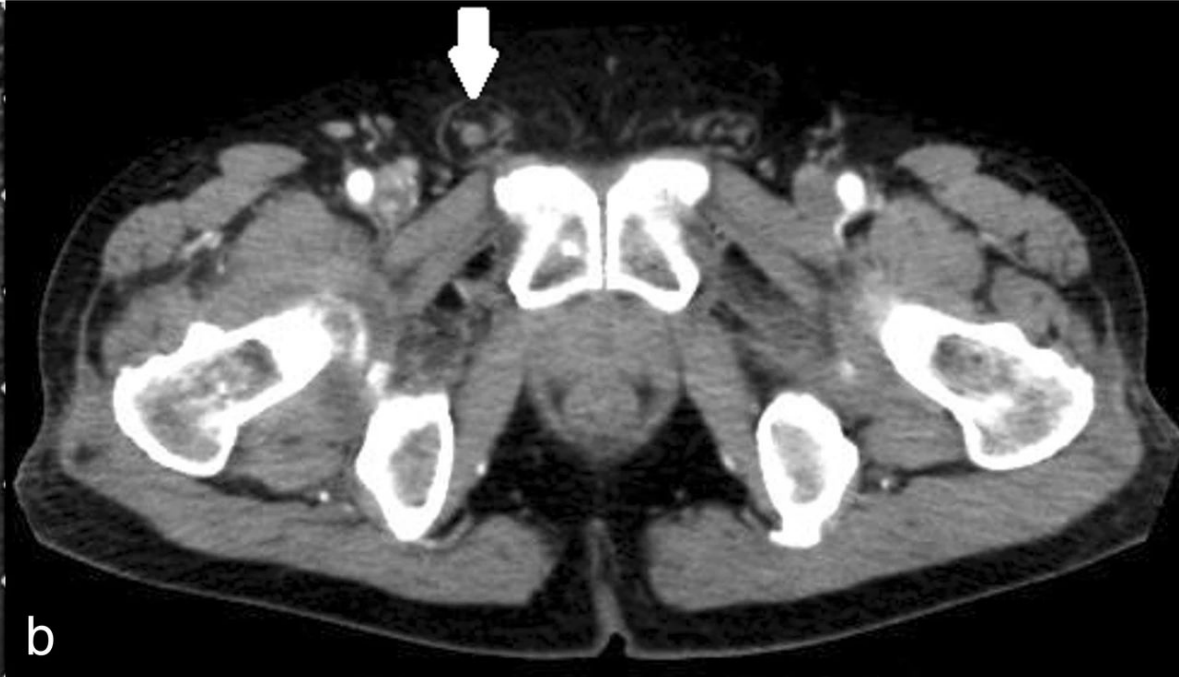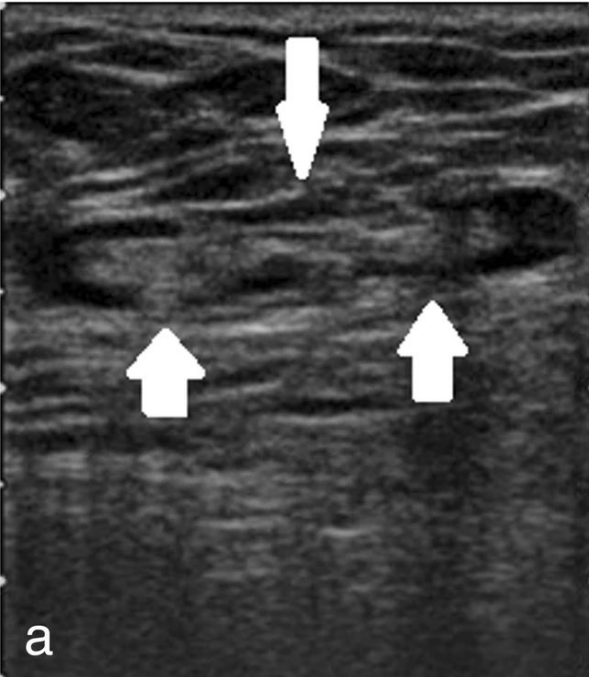
Obturator hernia



Special types of the strangulated hernia

Special types

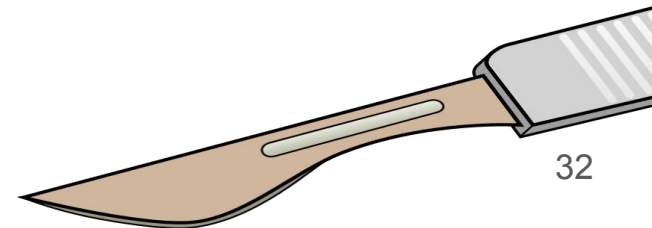




Ventral hernia treatment

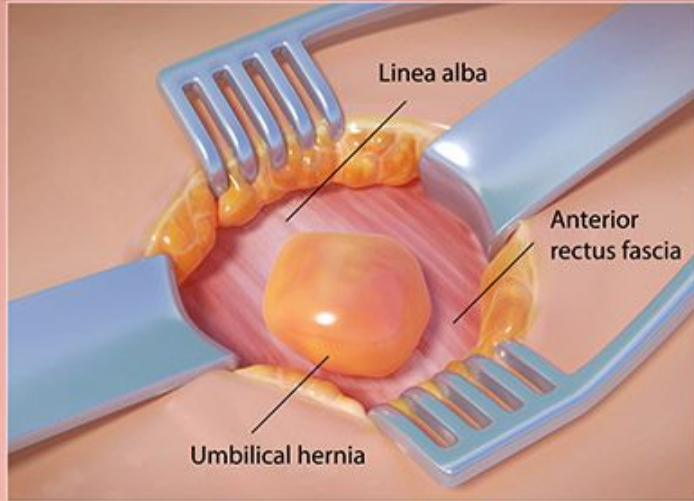
Umbilical Hernia

1. Small, asymptomatic→follow clinically.
2. Primary sutured repair (Tissue repair)
3. Placement of prosthetic mesh for larger defects (>2 cm) using open or laparoscopic methods.

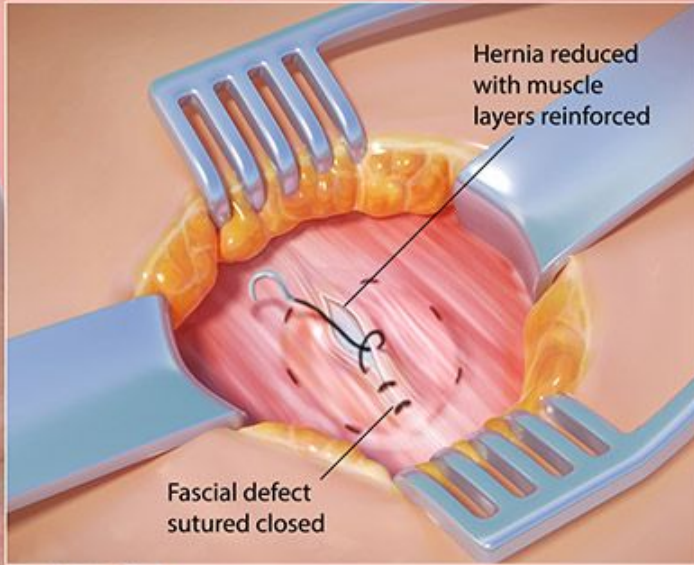


Primary sutured repair (Tissue repair)

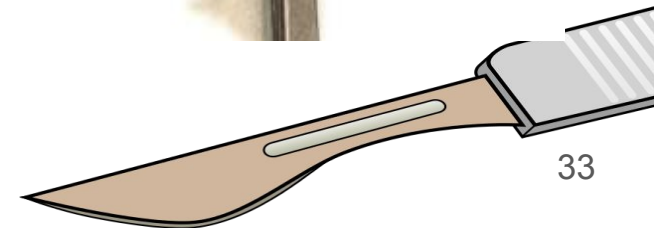
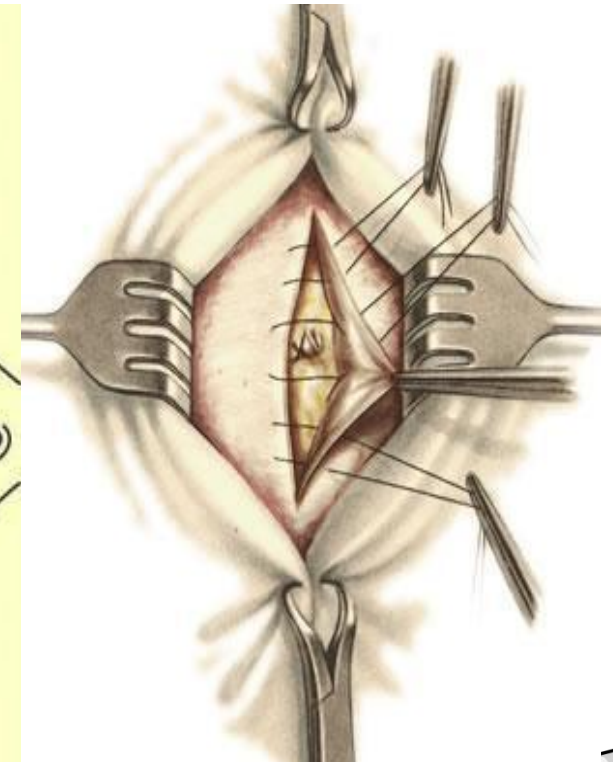
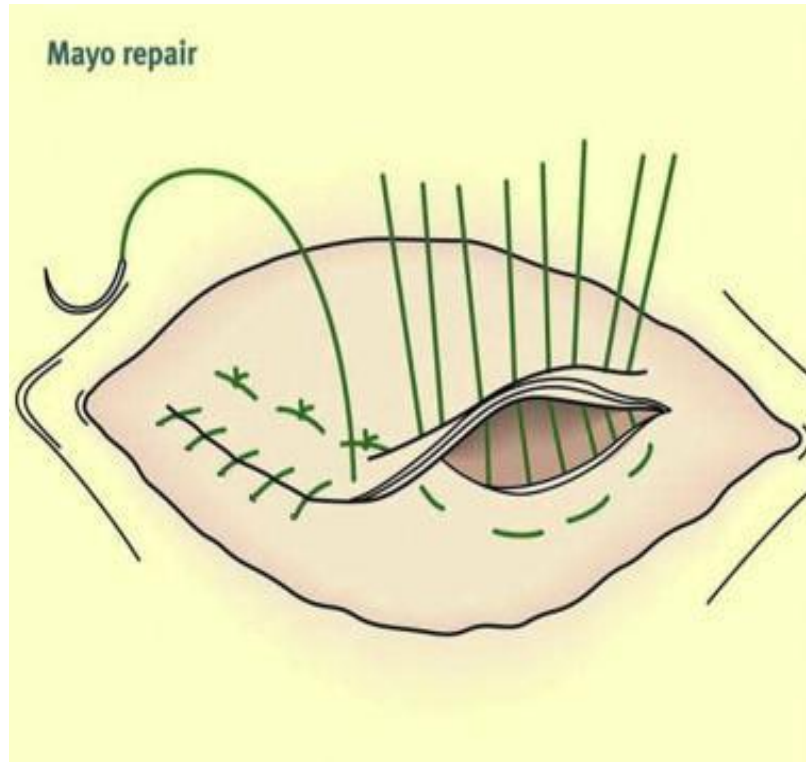
Exposing the hernia



Suturing the fascial layer

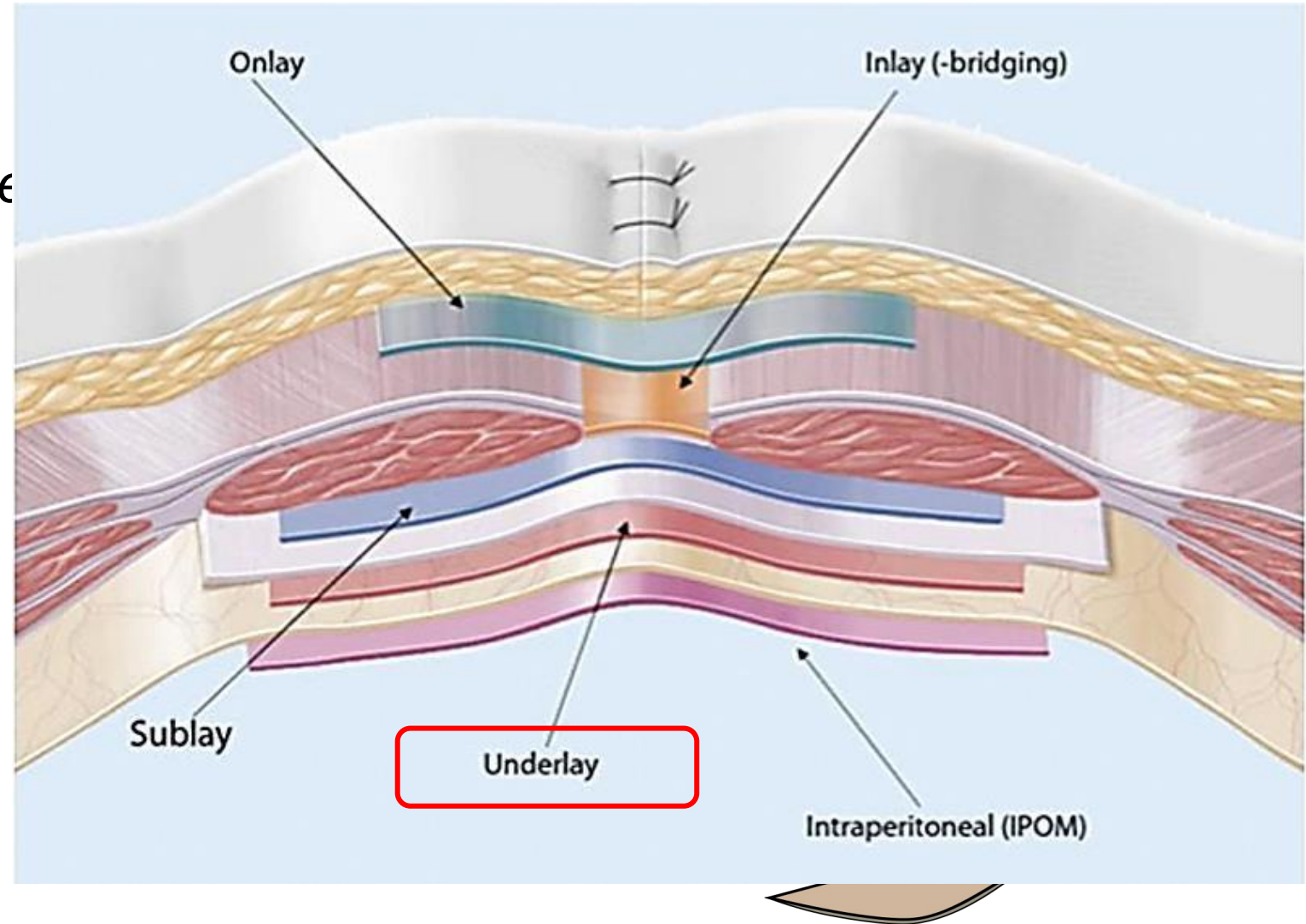
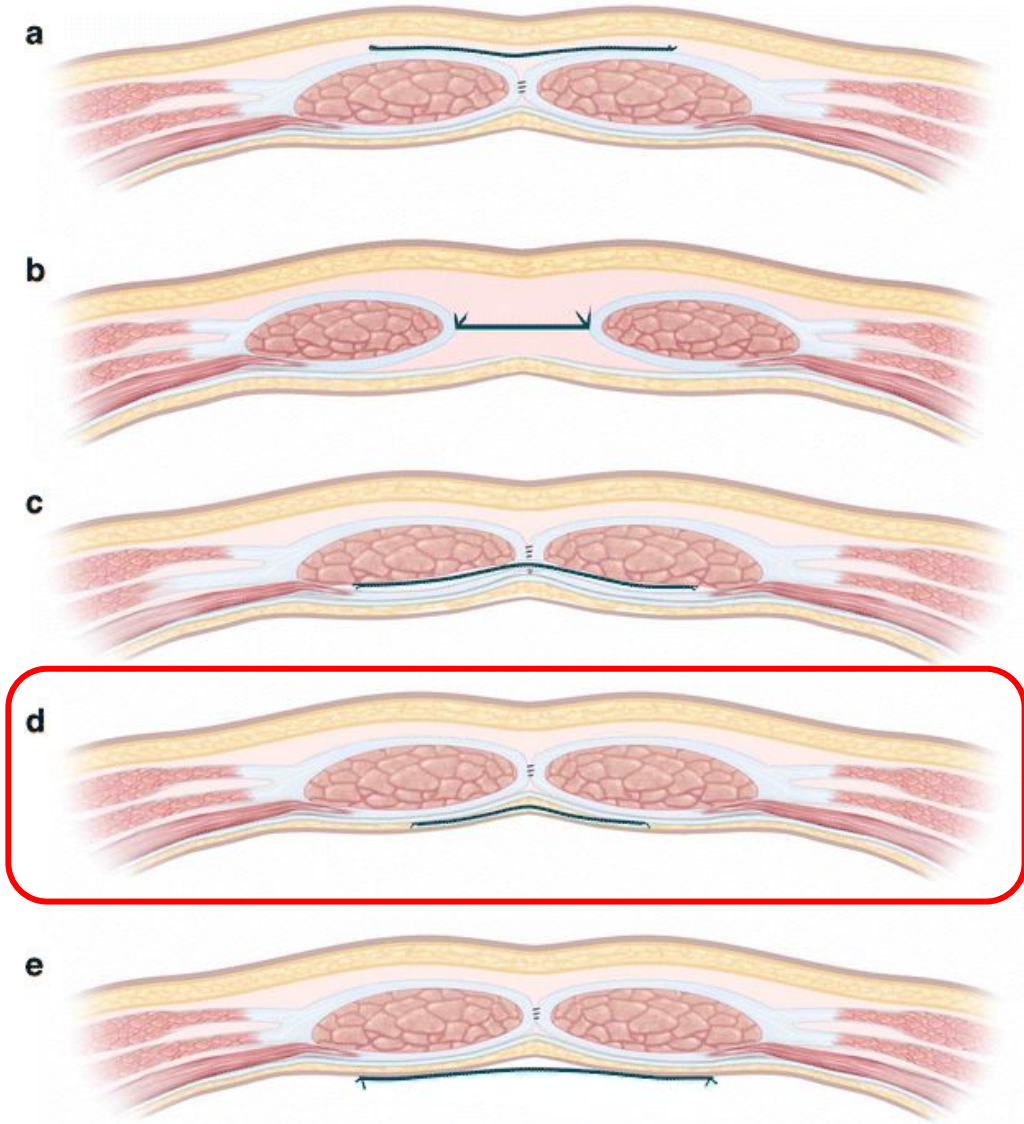


Mayo repair

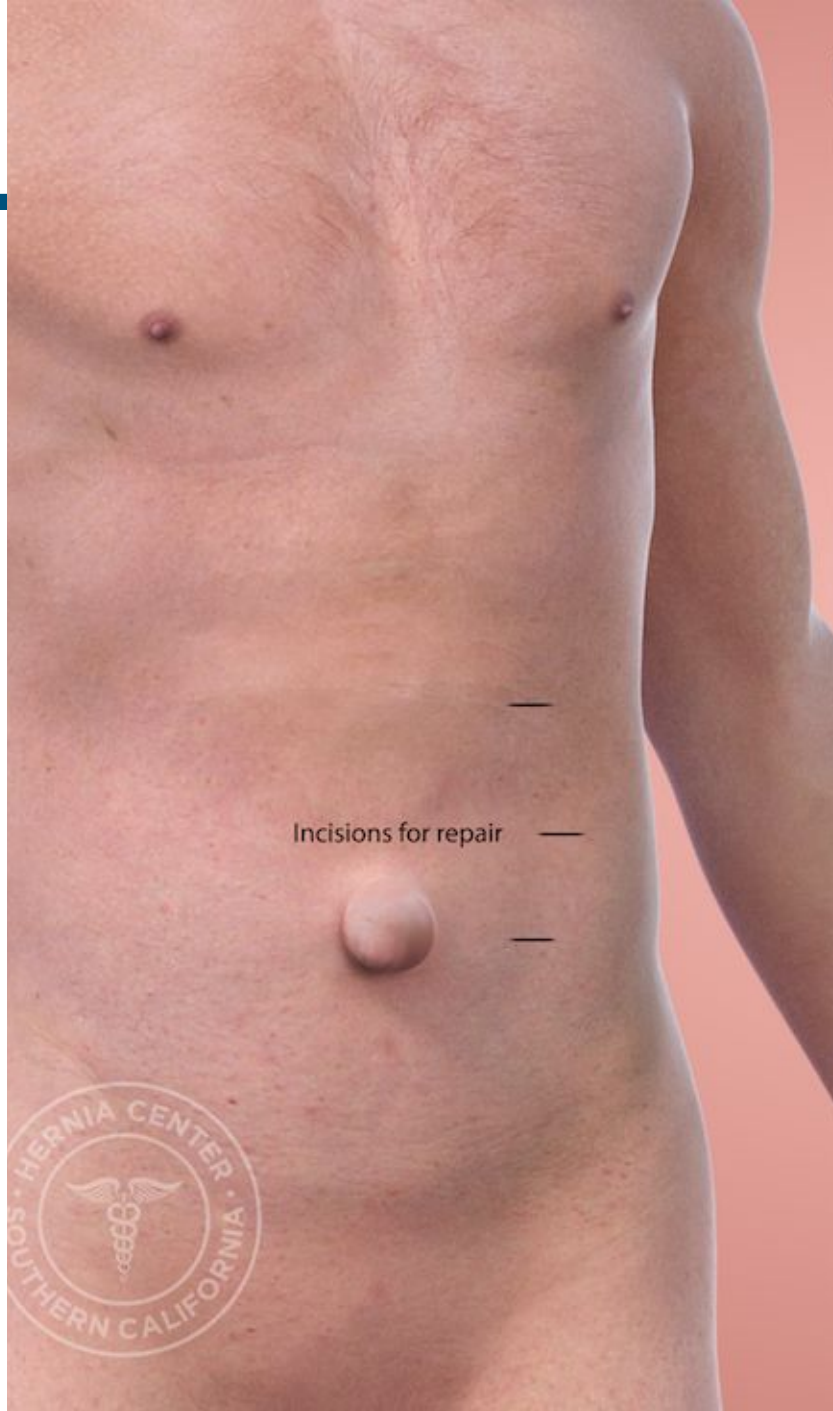


Principles of the mesh deployment

Underlay mesh deployment to the fascial defect

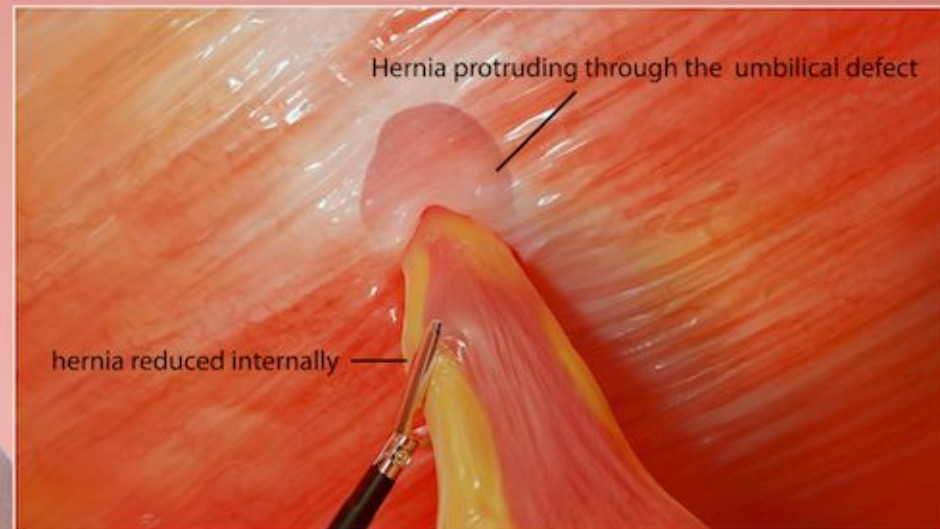


Laparoscopic mesh repair

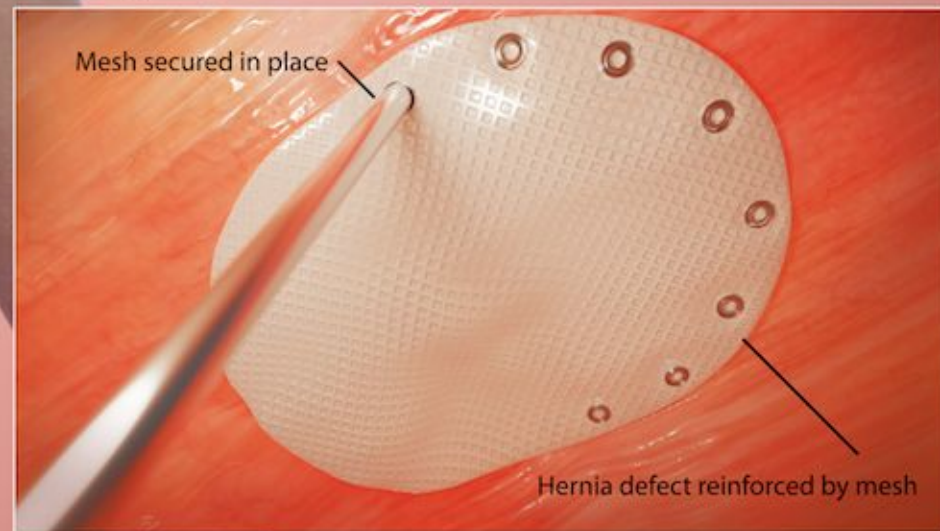


Laparoscopic Umbilical Hernia Surgery

Reducing the hernia



Reinforcing the defect



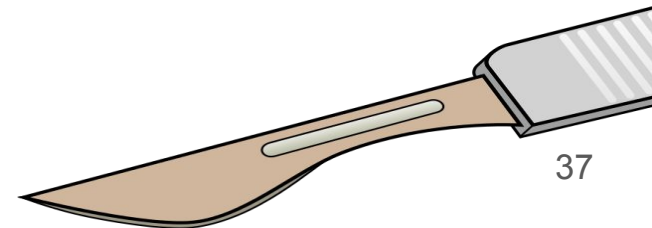
Ventral hernia repair

Ventral hernia repair

Often it's quite difficult to approximate edges of the hernia defect. Therefore intraabdominal pressure on the mesh leads to dehiscence and failure.

Following methods are used to bring rectus muscles towards midline and place mesh endoprosthesis:

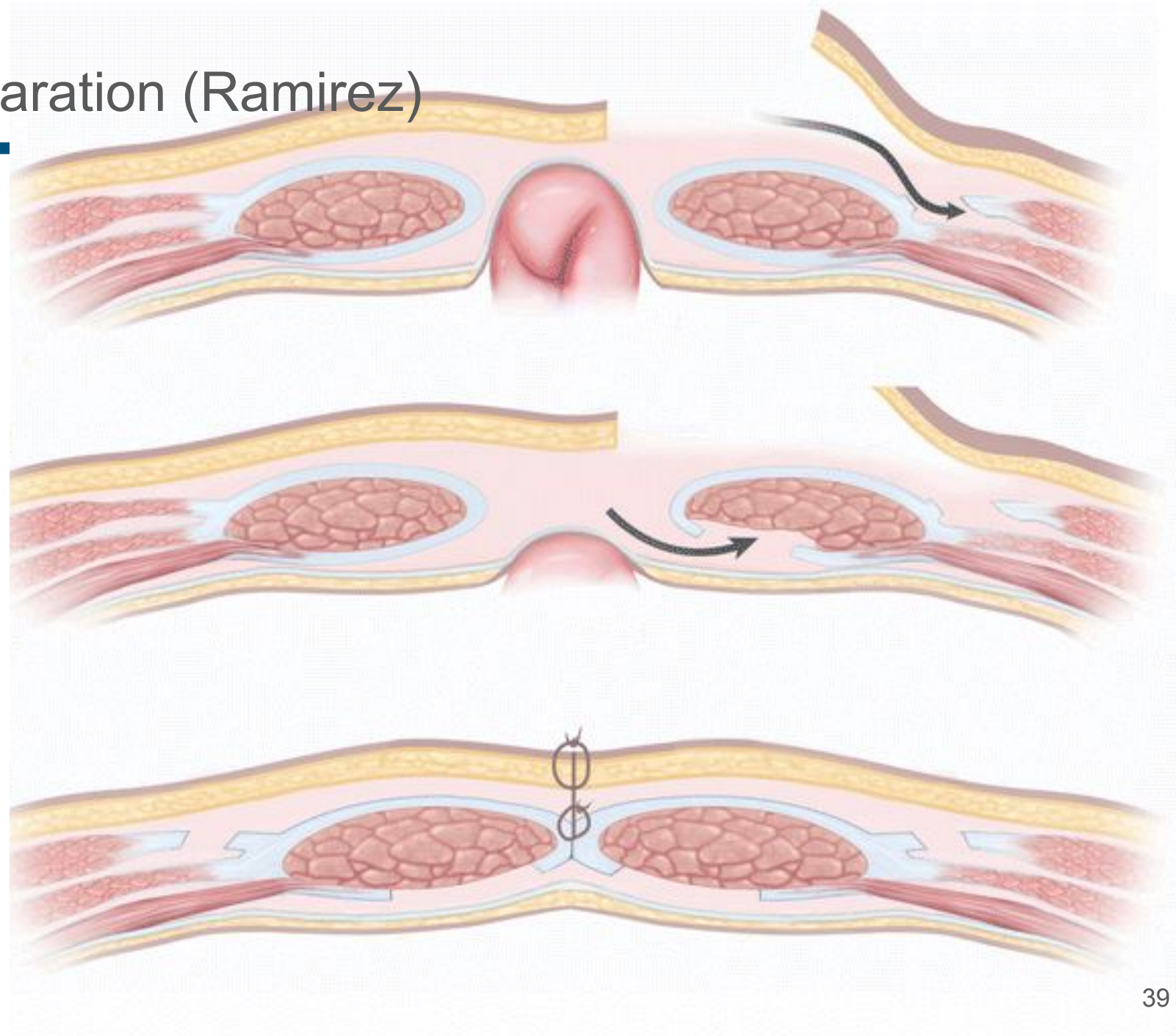
1. Anterior component separation (Ramirez)
2. Rives-Stoppa repair
3. Posterior component separation
4. Posterior component separation with TAR (Transversus abdominis release)



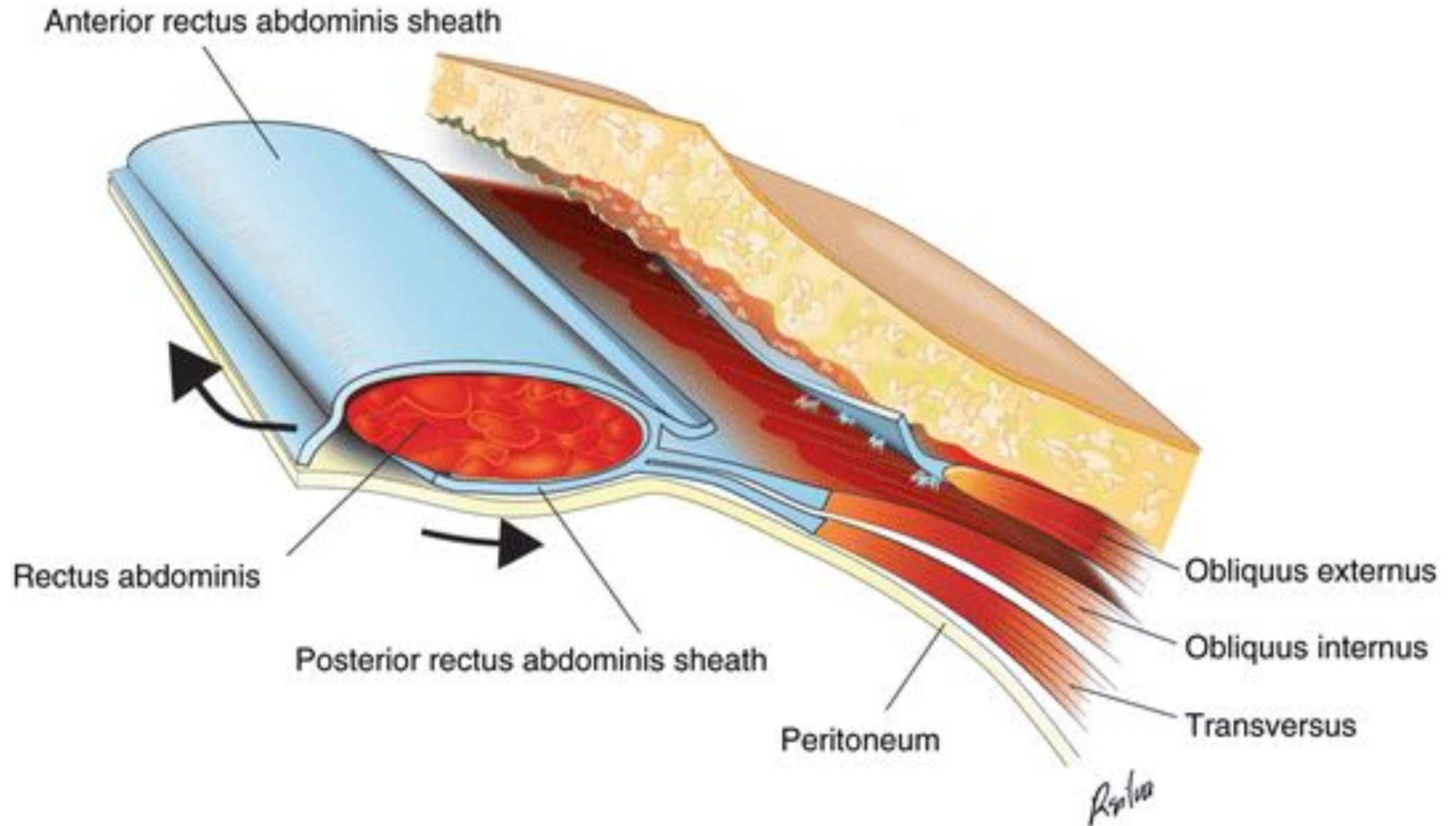
① Anterior component separation
(Ramirez)

Anterior component separation (Ramirez)

1. Skin flap development;
2. Transection of the external oblique aponeurosis;
3. Section of the posterior rectus sheath;
4. Fascial closure.

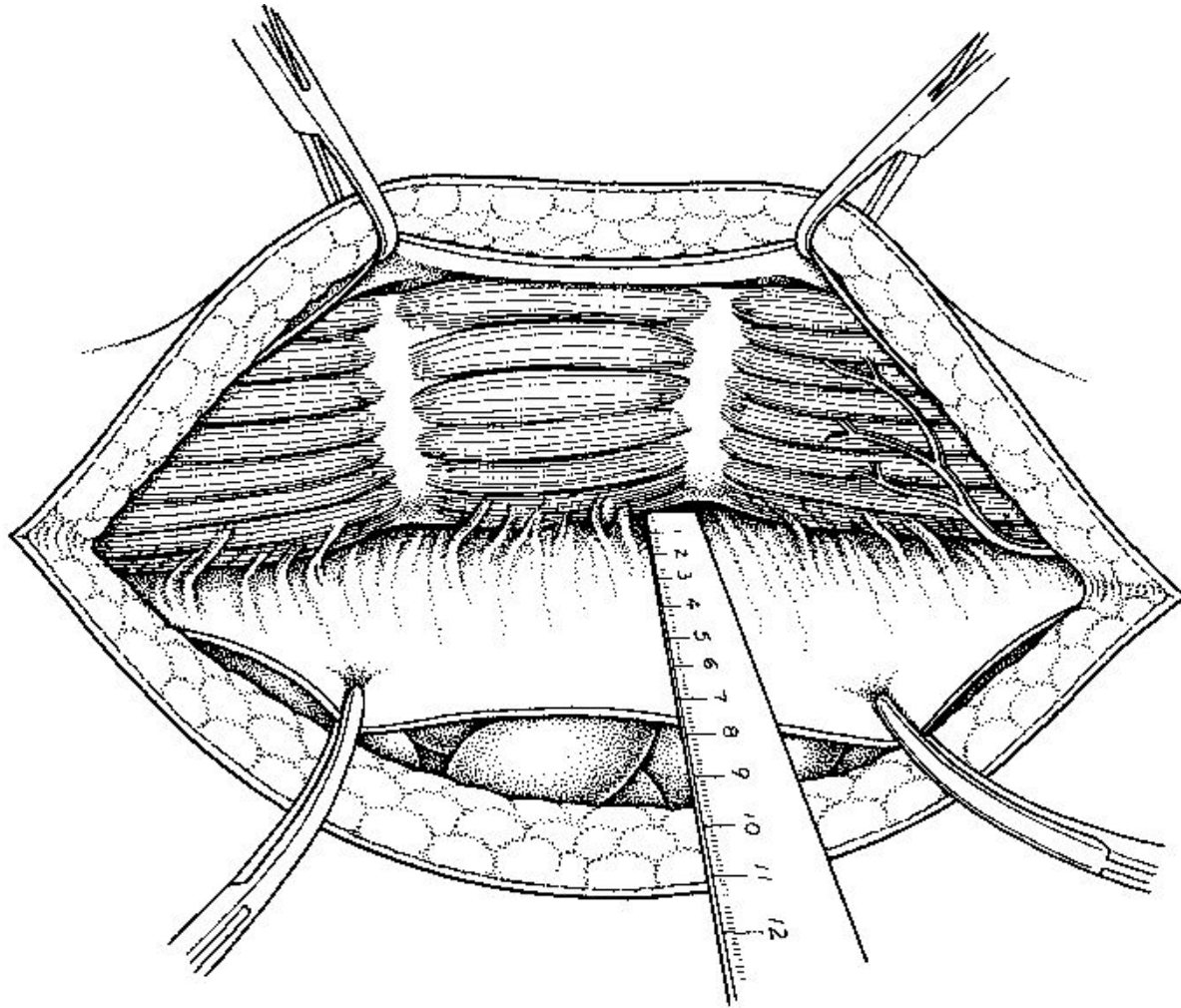


Anterior component separation (Ramirez)

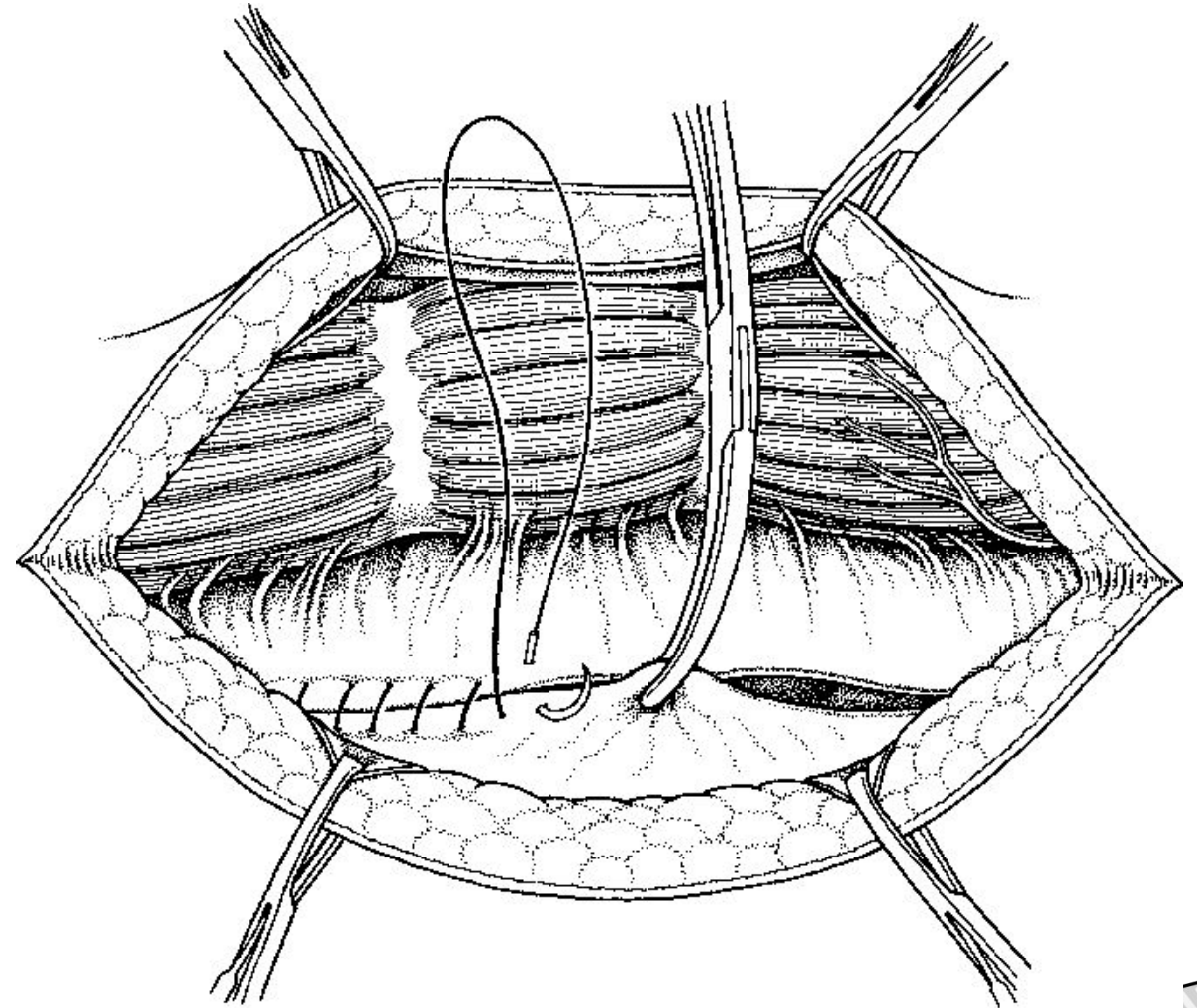


② Rives-Stoppa Repair

② Rives-Stoppa repair

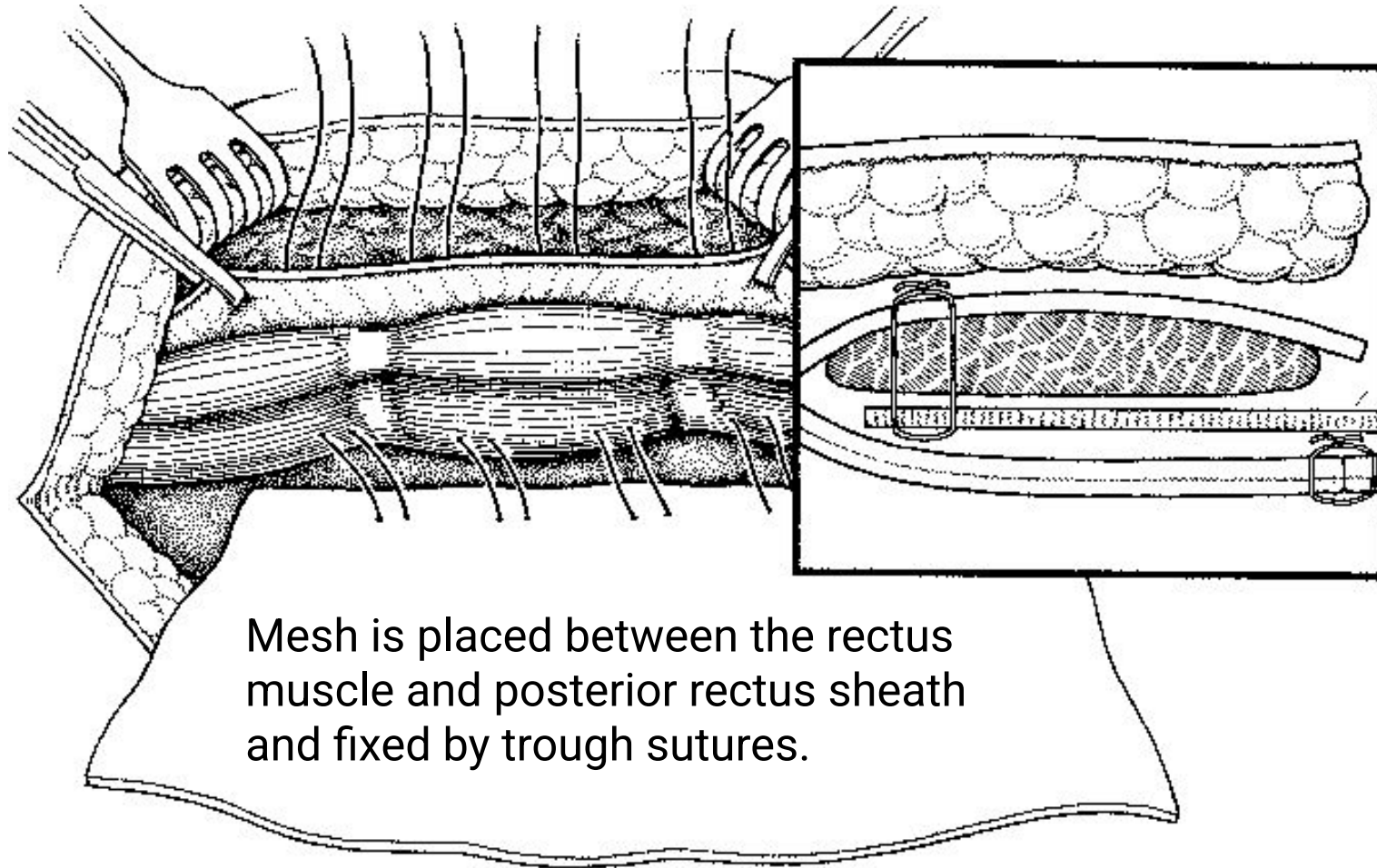


Pocket is created between the rectus muscle and posterior rectus sheath



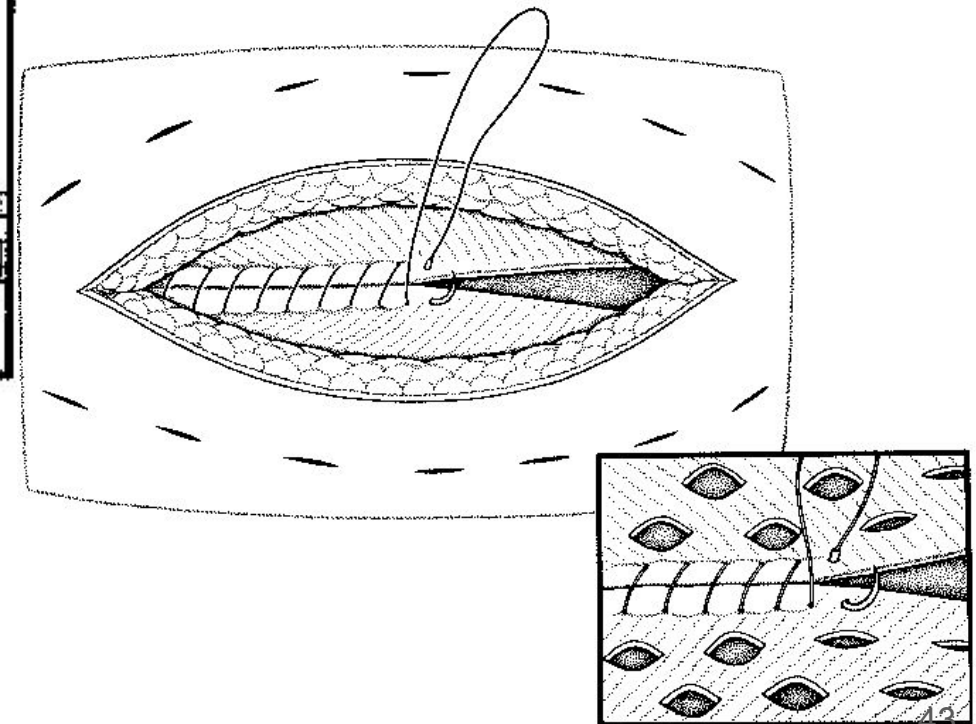
Posterior rectus sheath is sutured

② Rives-Stoppa repair

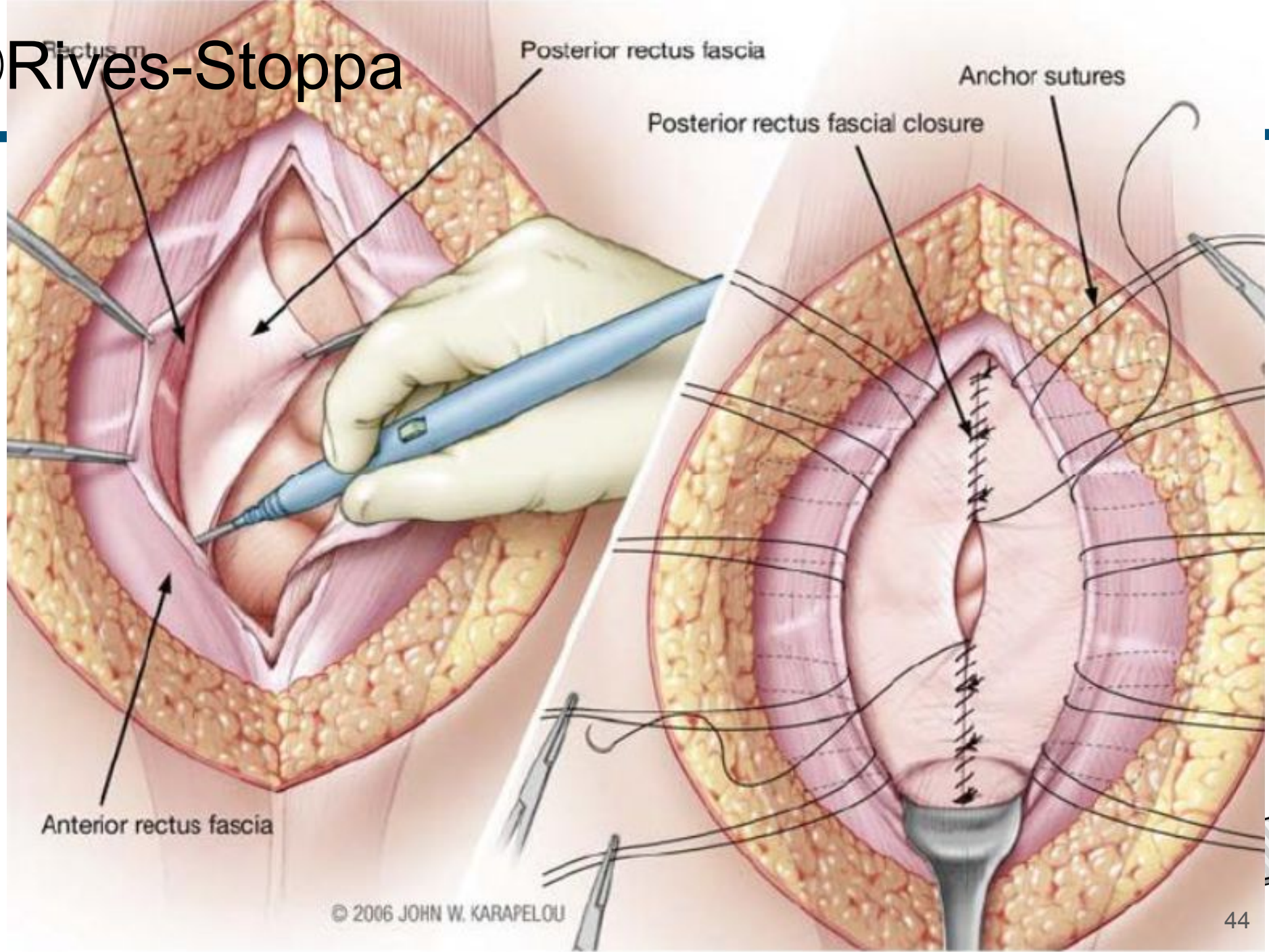


Mesh is placed between the rectus muscle and posterior rectus sheath and fixed by trough sutures.

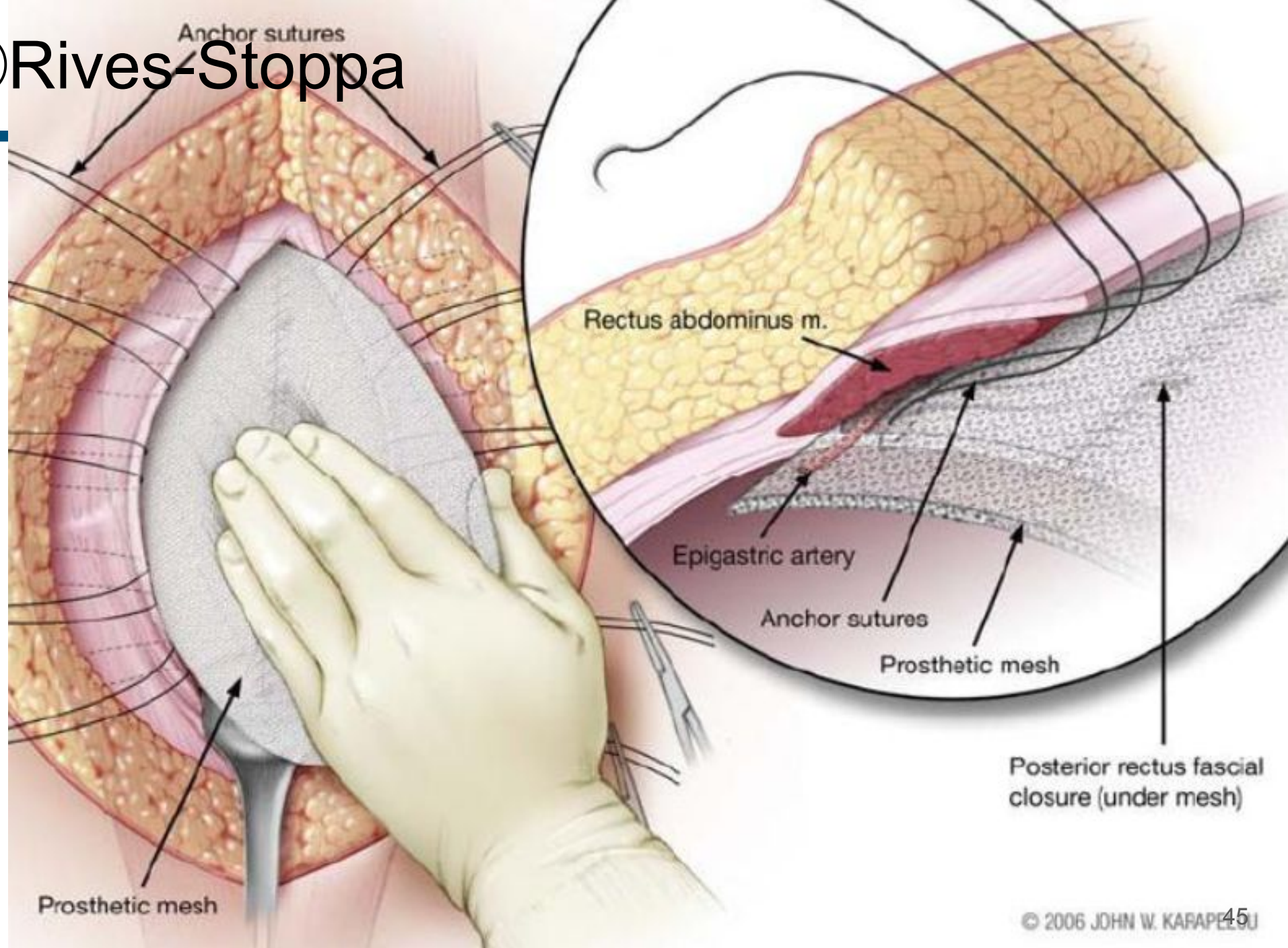
Anterior rectus sheath is sutured



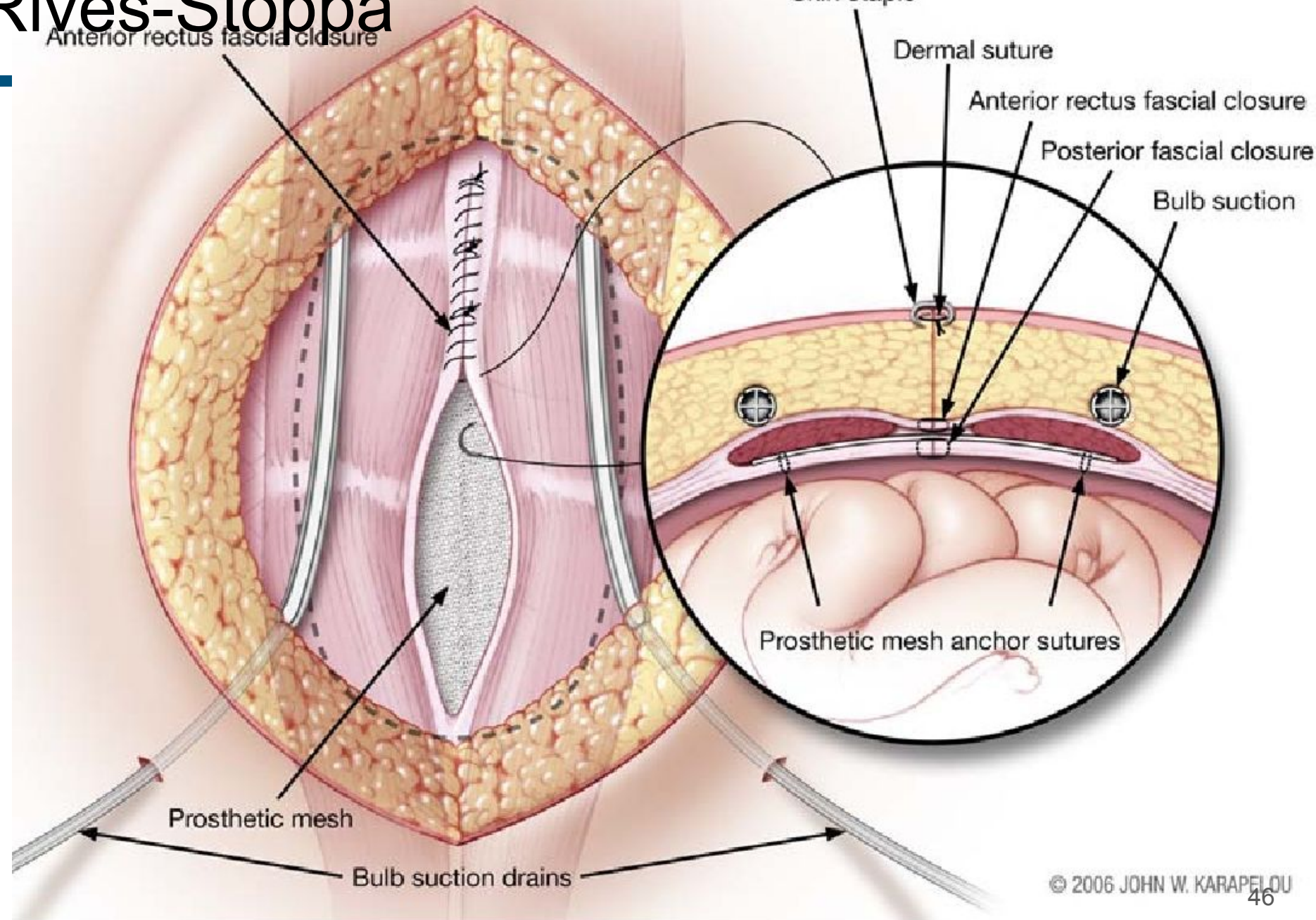
② Rives-Stoppa



② Rives-Stoppa

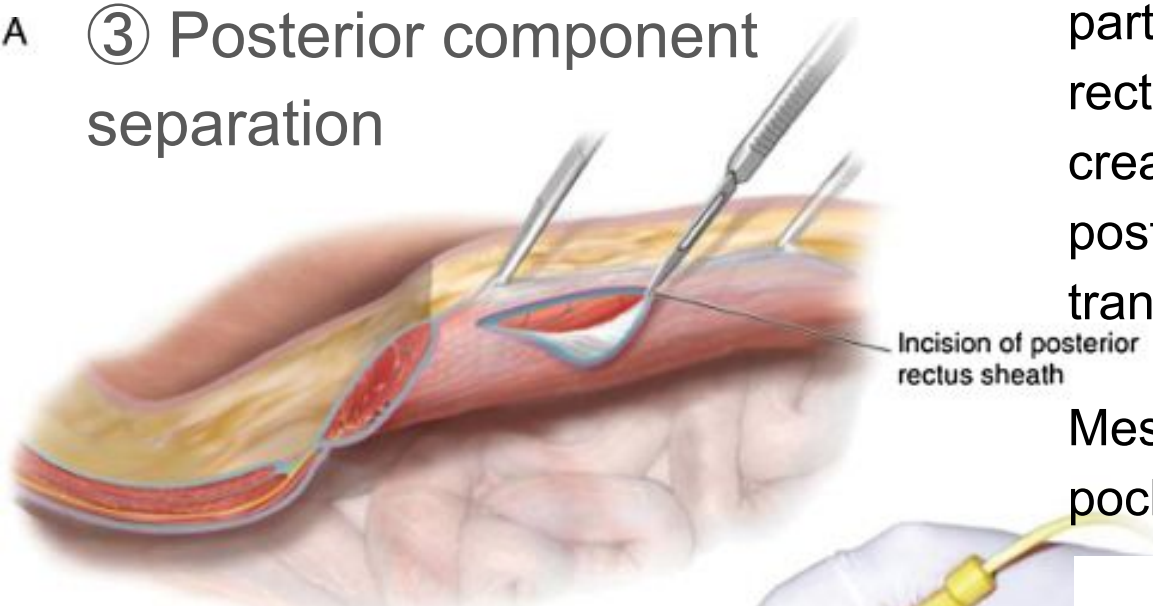


② Rives-Stoppa



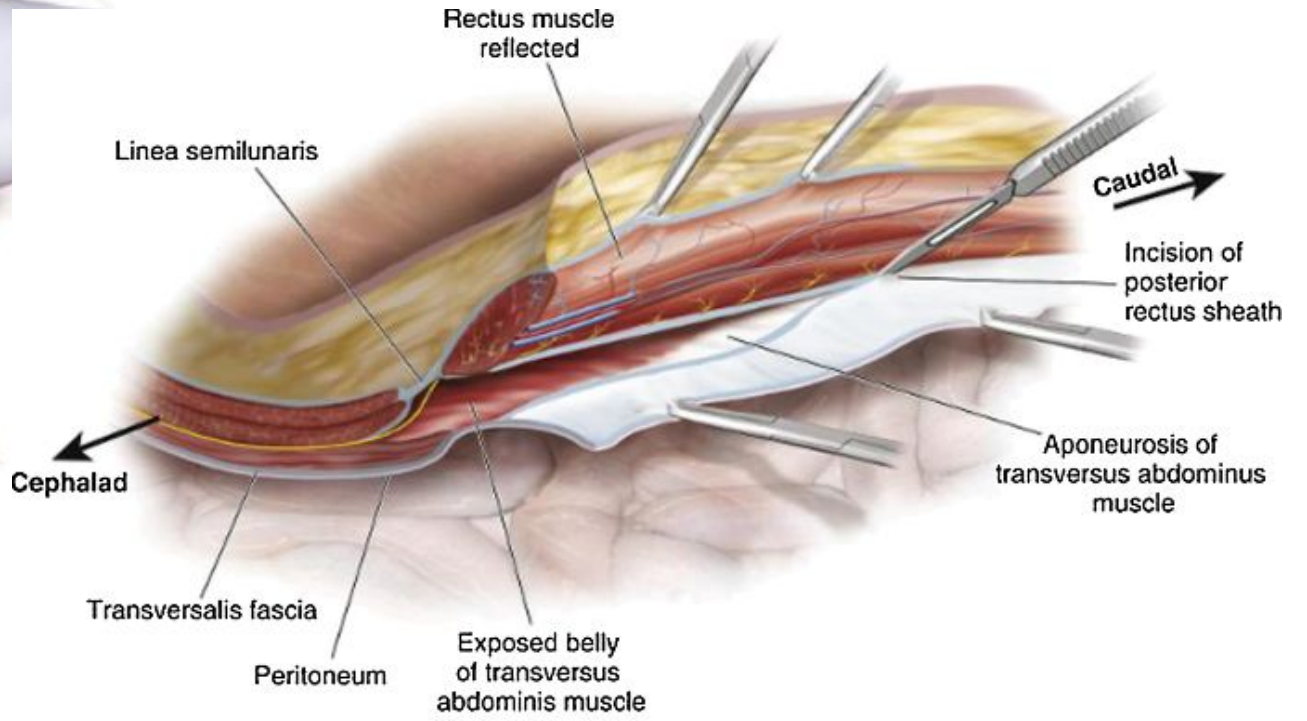
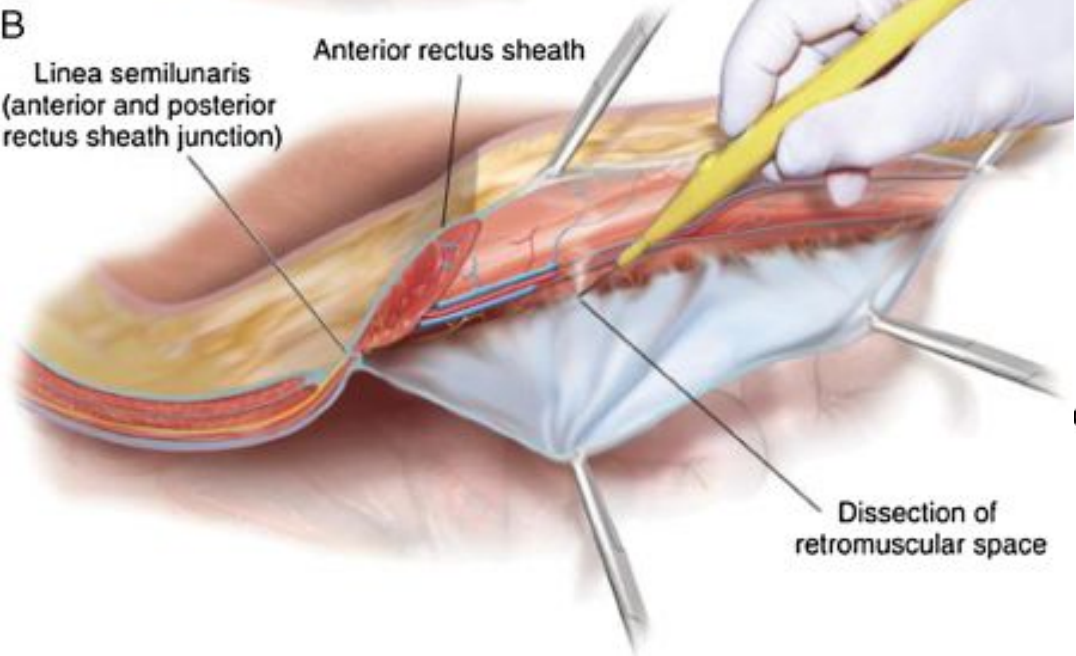
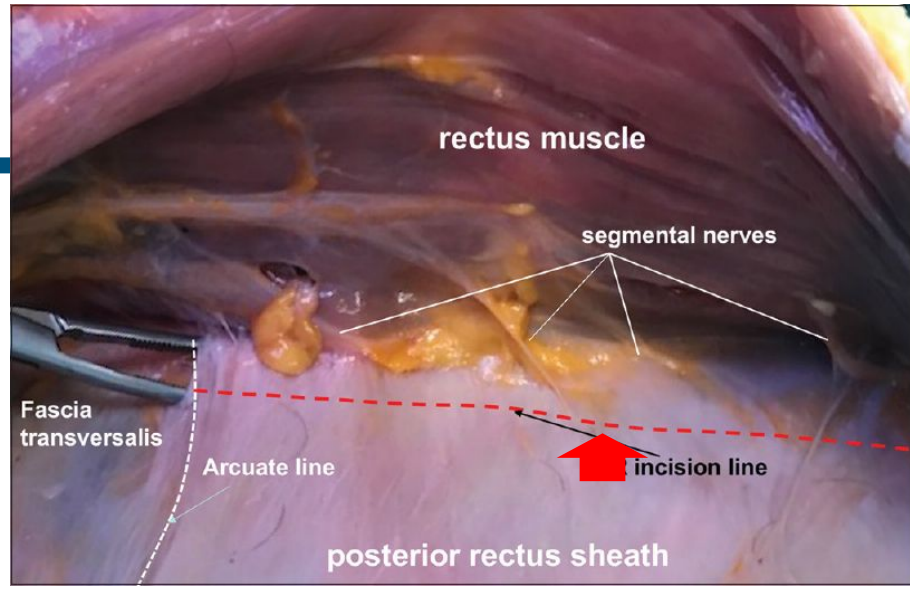
③ Posterior Component Separation

A ③ Posterior component separation



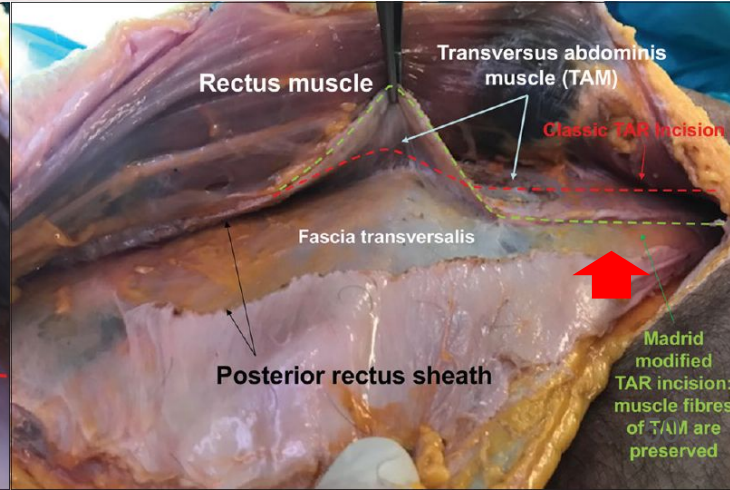
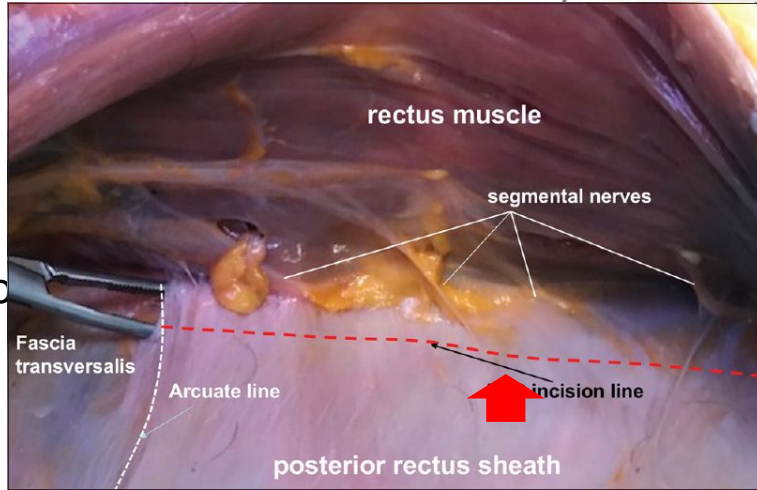
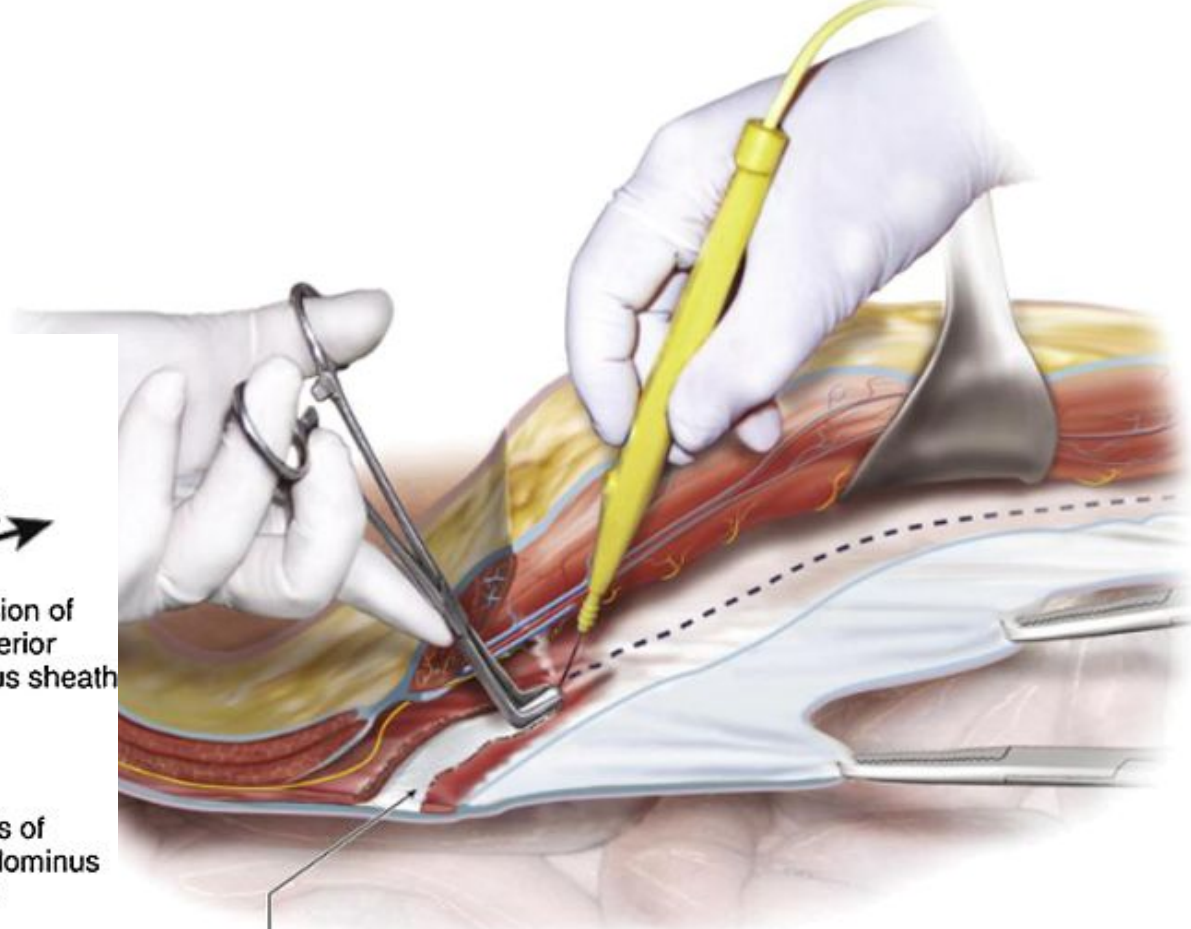
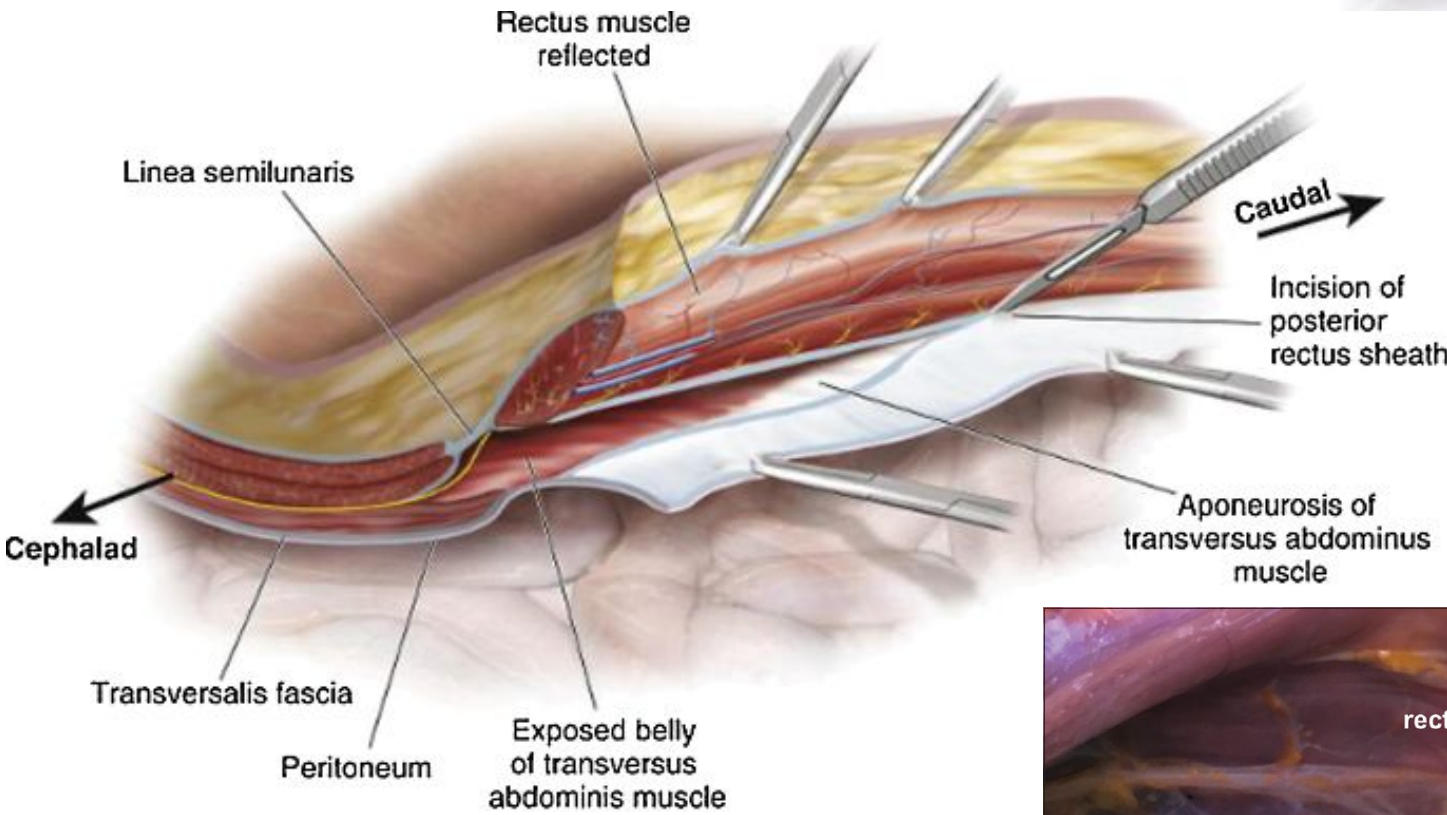
Cutting most lateral part of the posterior rectus sheath pocket is created between posterior oblique and transversalis muscles.

Mesh is placed in that pocket.

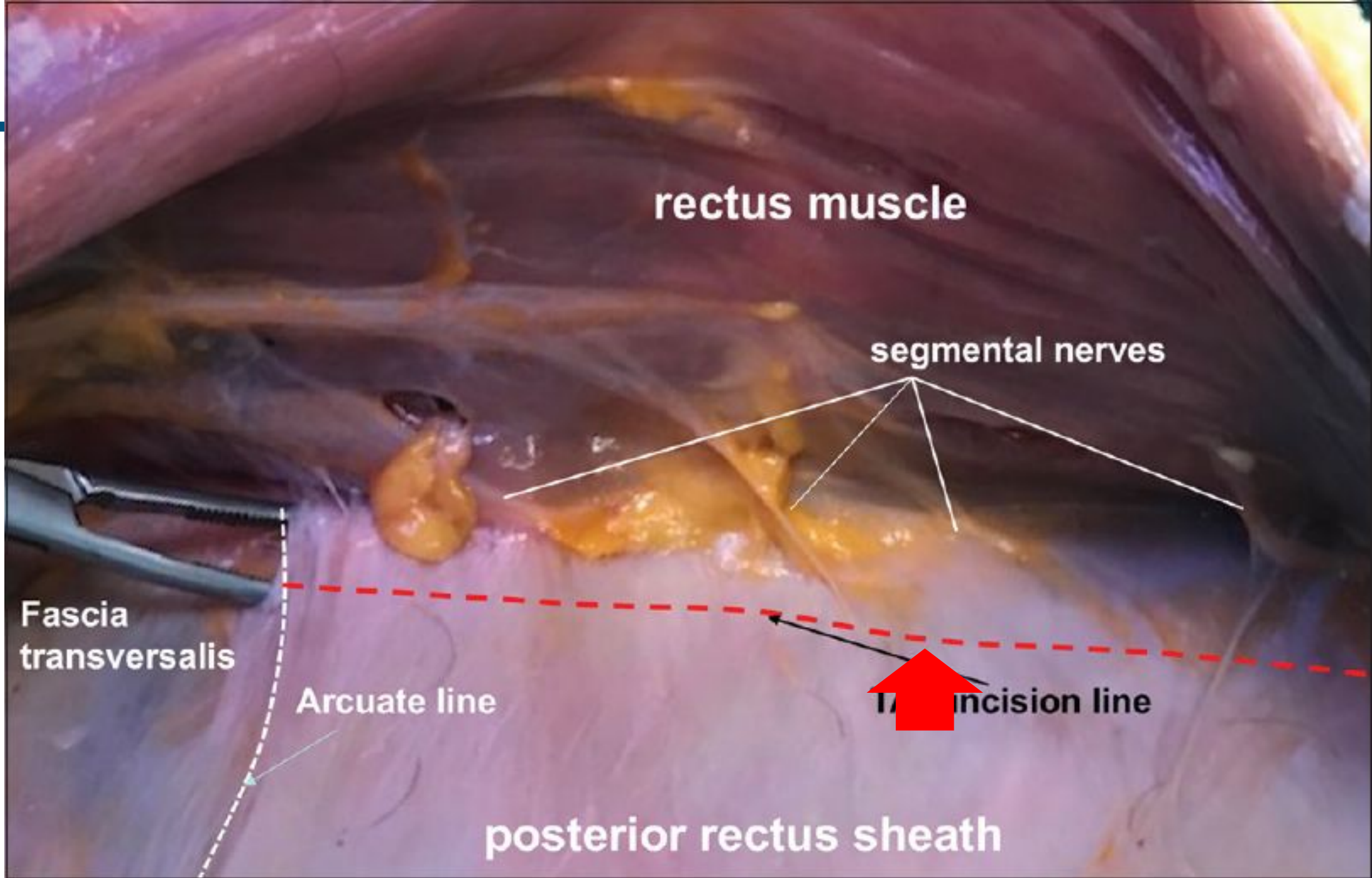


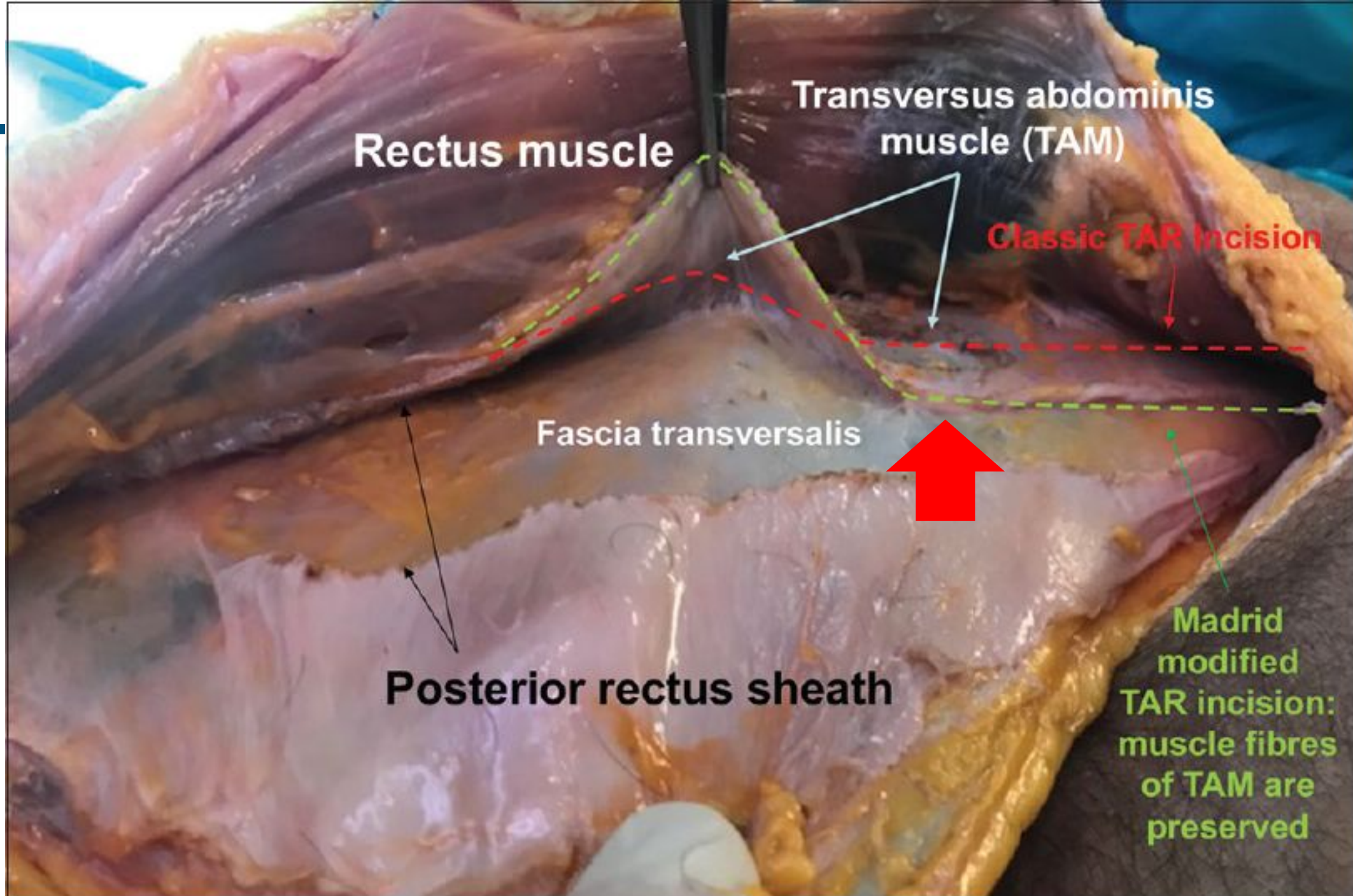
③ Posterior Component Separation with
TAR (transversus abdominis release)

④ Posterior component separation with TAR (transversus abdominis release)

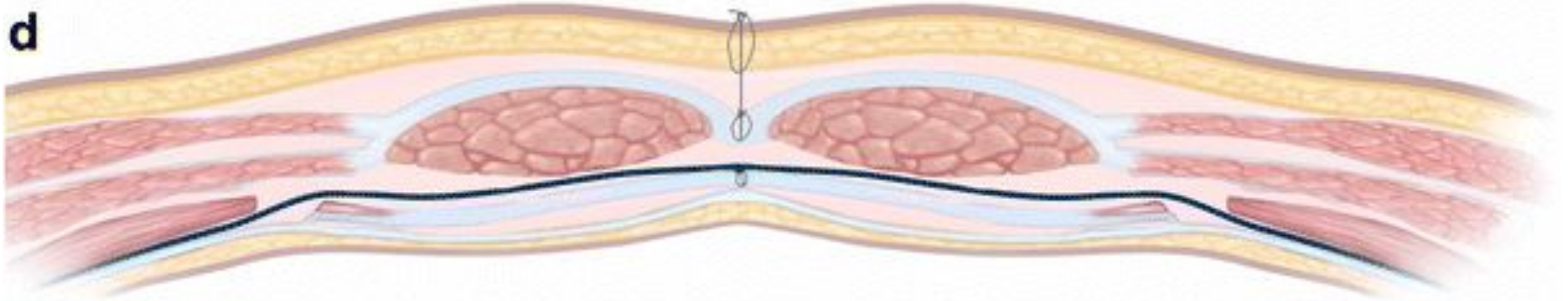


After performing the posterior component separation, medial edge of the transversalis muscle is transected to make pocket between transversalis muscle and transversalis fascia. The mesh is placed in this pocket if necessary.





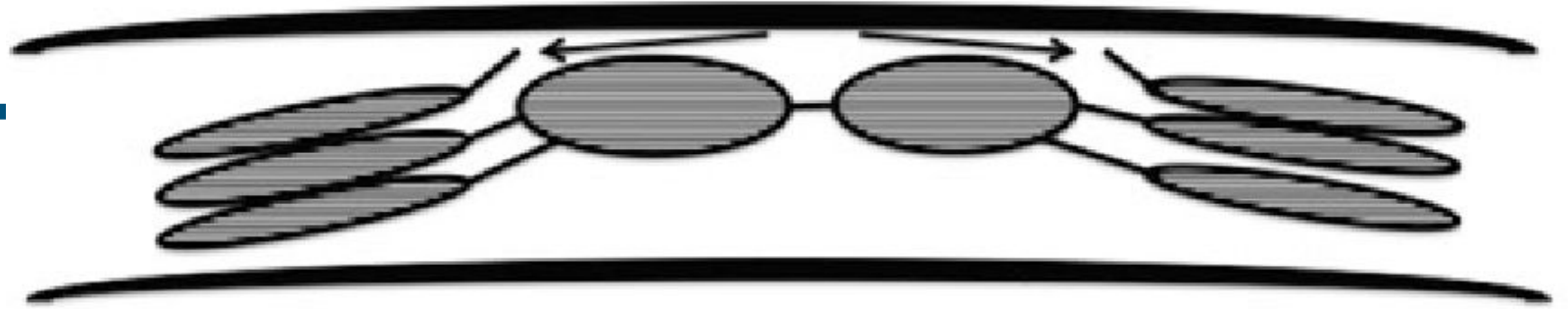
Mesh position after the posterior component separation with TAR (Sublay)



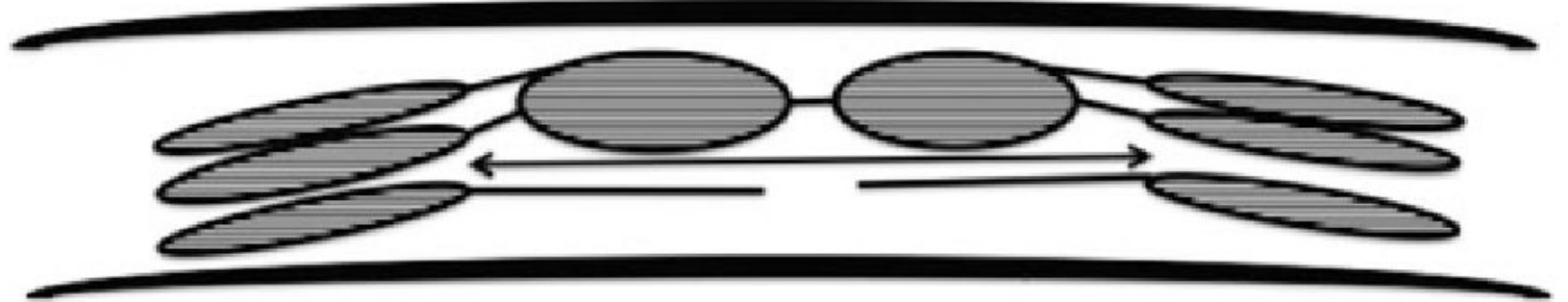
“Posterior” component separation achieved by longitudinal incision along the transversus muscles, the “Transversus abdominus release”. This repair has been strengthened by a mesh in the “sublay” position

Final overview of methods:

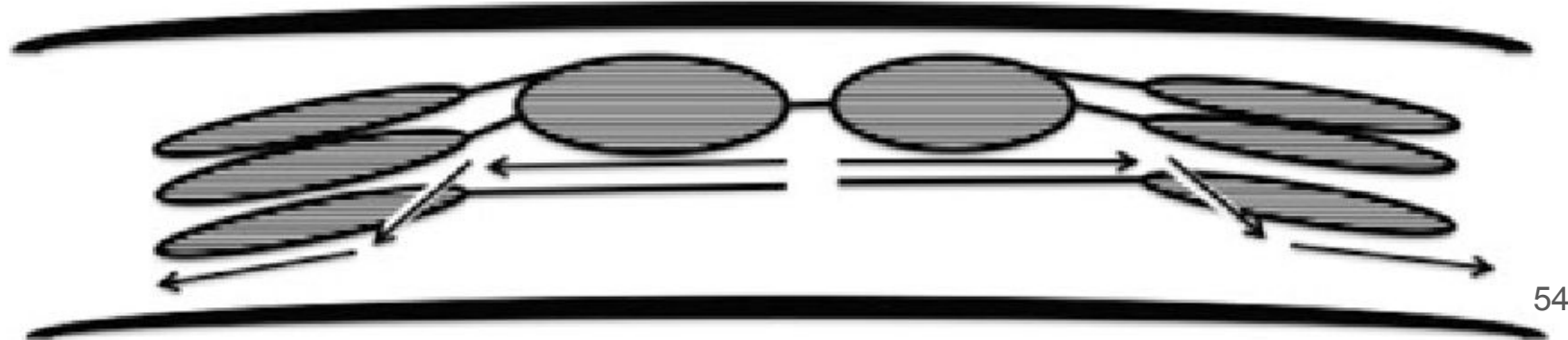
ANTERIOR COMPONENT SEPARATION



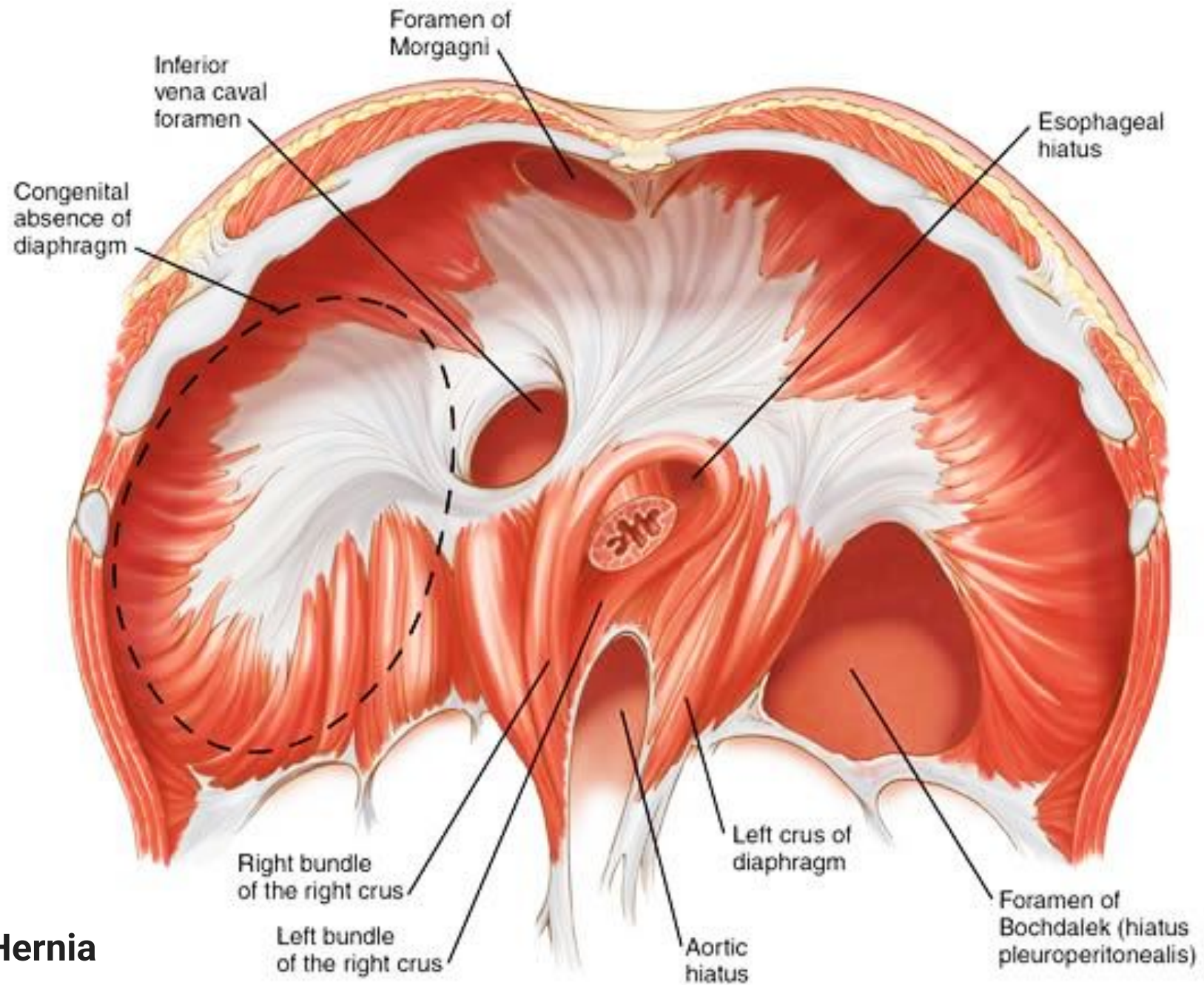
POSTERIOR COMPONENT SEPARATION



POSTERIOR COMPONENT SEPARATION WITH TAR

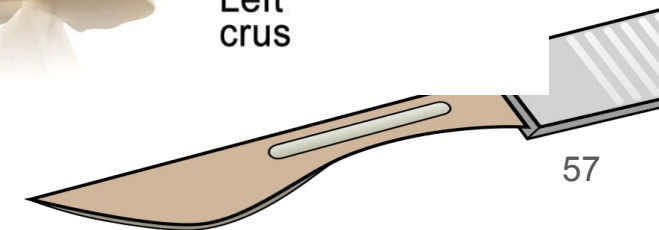
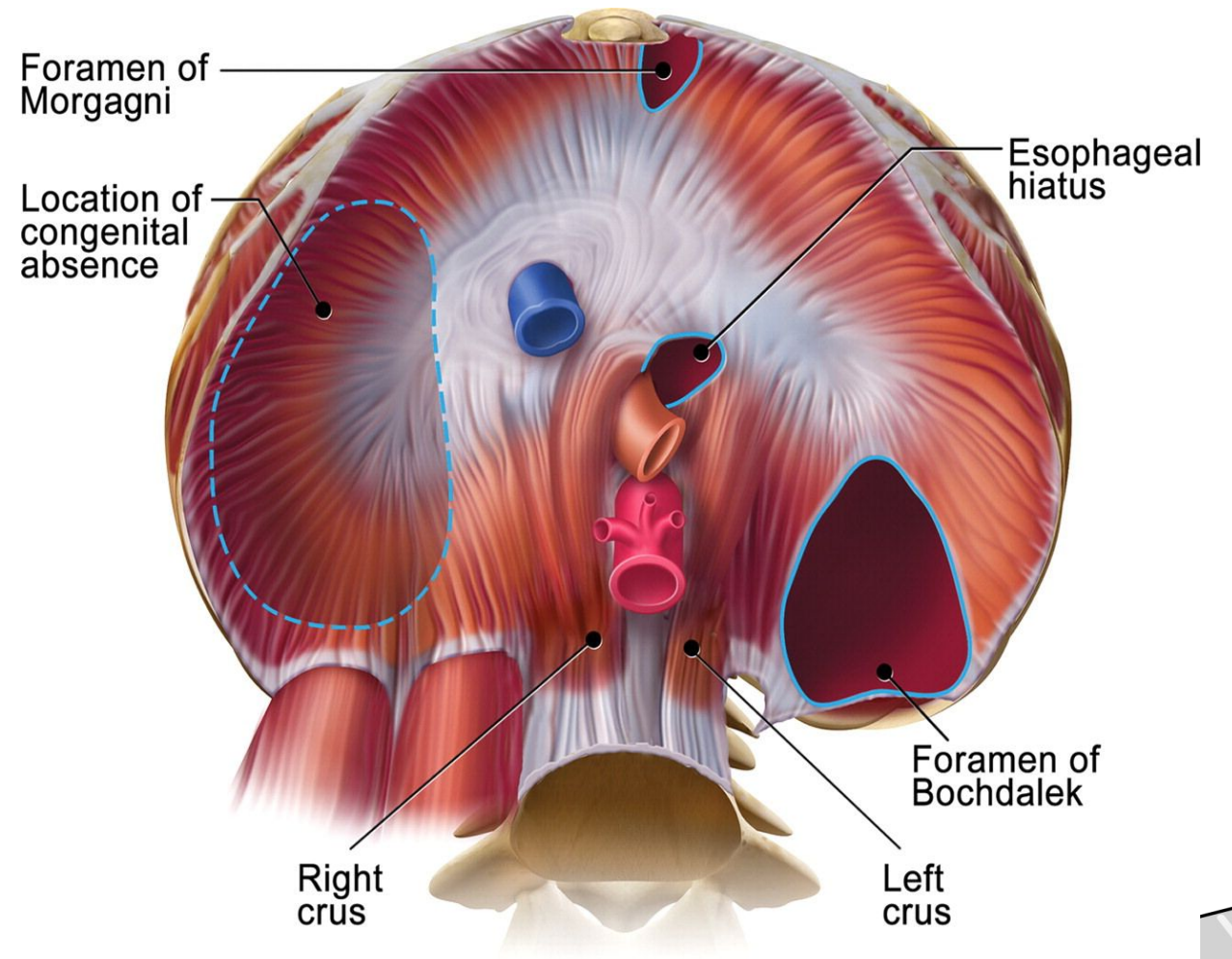
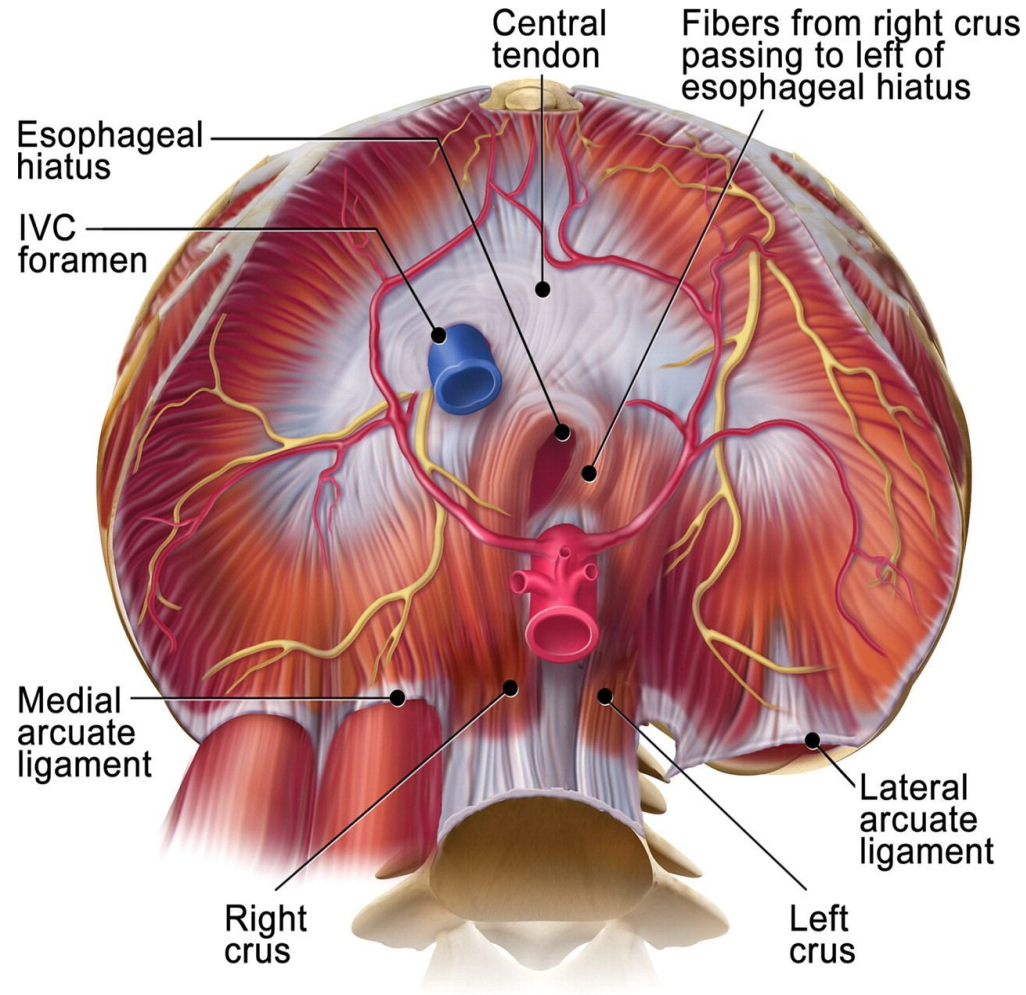


Diaphragmatic Herniation



Diaphragmatic Hernia Types

Diaphragmatic Anatomy and Hernia Types



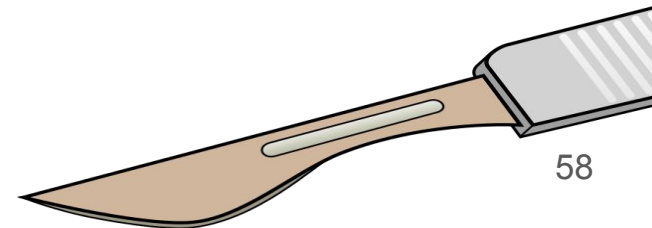
Hiatal hernia

Hiatal hernia is the protrusion of the stomach and other abdominal viscera into the mediastinum

It is caused by increased intra-abdominal pressure.

Risk factors include:

- Being overweight
- Elderly
- Multiple pregnancies
- History of esophageal surgery
- Partial or full gastrectomy
- Certain disorders of the skeletal system associated with bone decalcification and degeneration



Diaphragmatic Herniation

- Type I – Sliding

- Herniation of Cardia

- Type II – Rolling (paraesophageal)

- Herniation of Fundus

- Type III – Combined (paraesophageal)

- Herniation of both

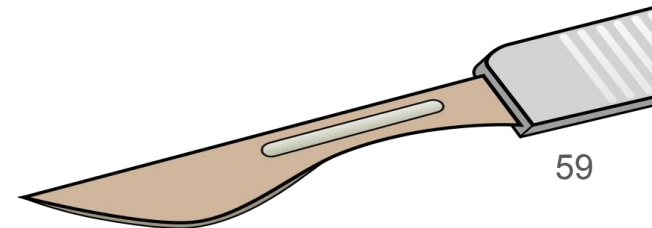
- Type IV

- Herniation of additional organ (colon mostly)

- Age

- Weakening of the phrenoesophageal membrane

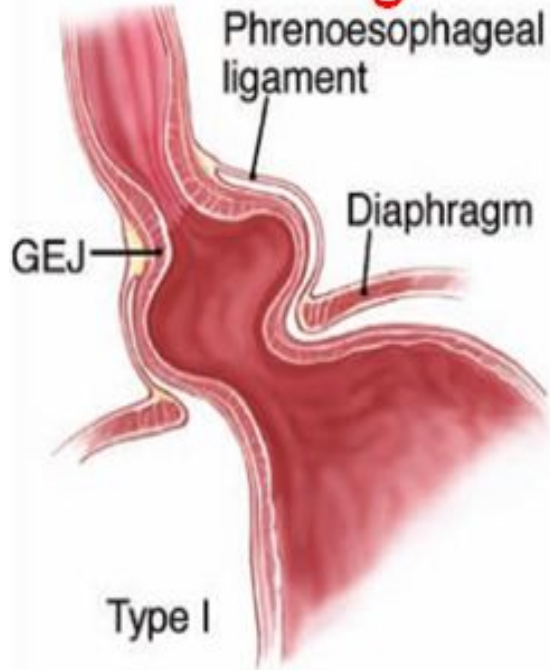
- More often in women



Hiatal hernia of the diaphragm

Axial

Sliding

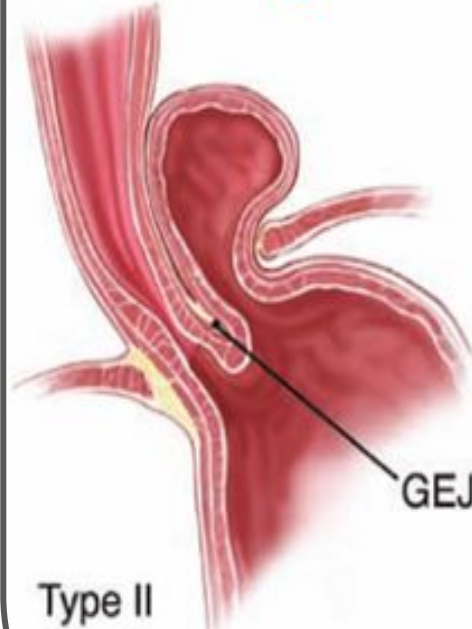

90%

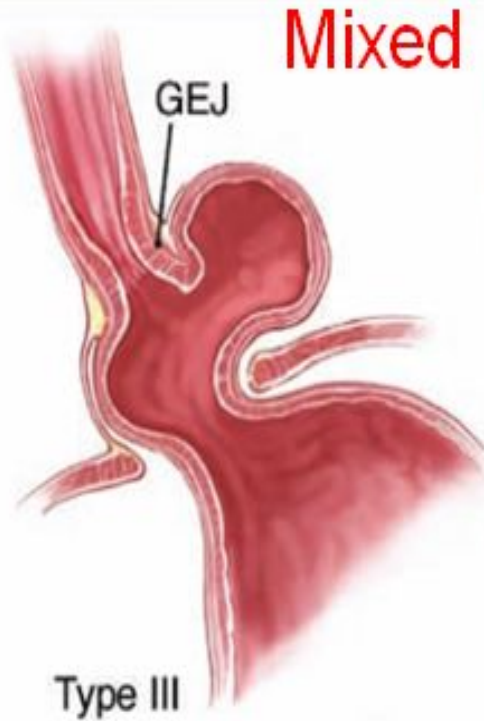Paraesophageal

high risk of gastric obstruction.

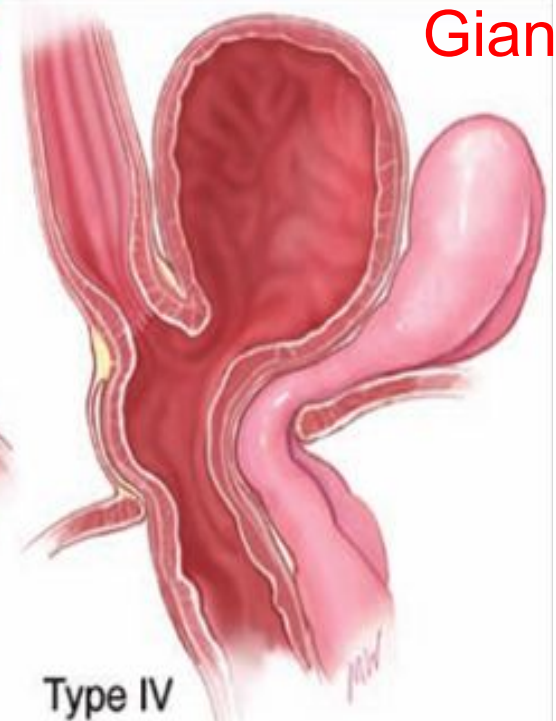Rolling



Mixed



Giant



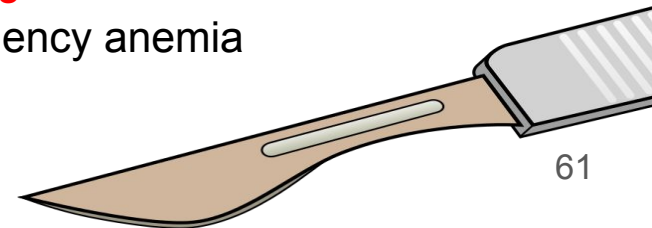
4.5%

Hiatal hernia

- Type I hernias represent more than 90% of cases of hiatal hernia and are known for their **frequent association with GERD**. They are also associated with more severe degrees of esophagitis and Barrett's esophagus
- Types II-IV are referred to as paraesophageal hernias (PEH); their main clinical importance is due to their **potential for ischemia, obstruction or volvulus**

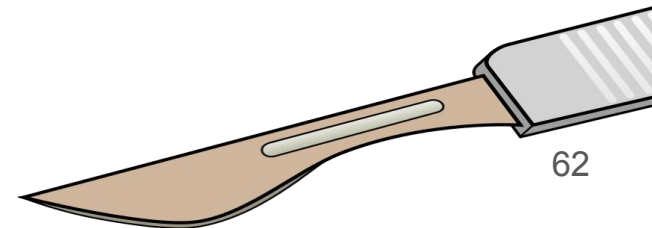
Signs and Symptoms

- Gastroesophageal reflux disease and hiatal hernia are closely associated
- Sliding Hernia
 - Mostly asymptomatic
 - If large ⇨ symptoms of GERD
Regurgitation and heartburn
- **Belching**
- **Epigastric or retrosternal chest pain**
- Less common symptoms:
 - Dysphagia
 - Early satiety
 - Dyspnea
 - Recurrent pneumonia
 - **Recurrent bleedings with absence of ulcers**
 - Chronic iron deficiency anemia



Hiatal hernia

- **Barium swallow** still remains essential in the diagnosis of hiatal hernia → video-esophagram. detecting esophageal motility dysfunction, stenosis and stricture related to GERD.
- **Esophagogastroduodenoscopy (EGD)** - check mucosa, erosive esophagitis, Barrett's esophagus, Cameron's ulcer and even lesions suspicious for malignancy. Air insufflation of the stomach may exaggerate hernia size, difficulty to assess massive hernias accurately
- **Manometry** rule out achalasia or other motility disorders.
- pH testing is not essential → to document acid reflux
- CT is not routinely recommended



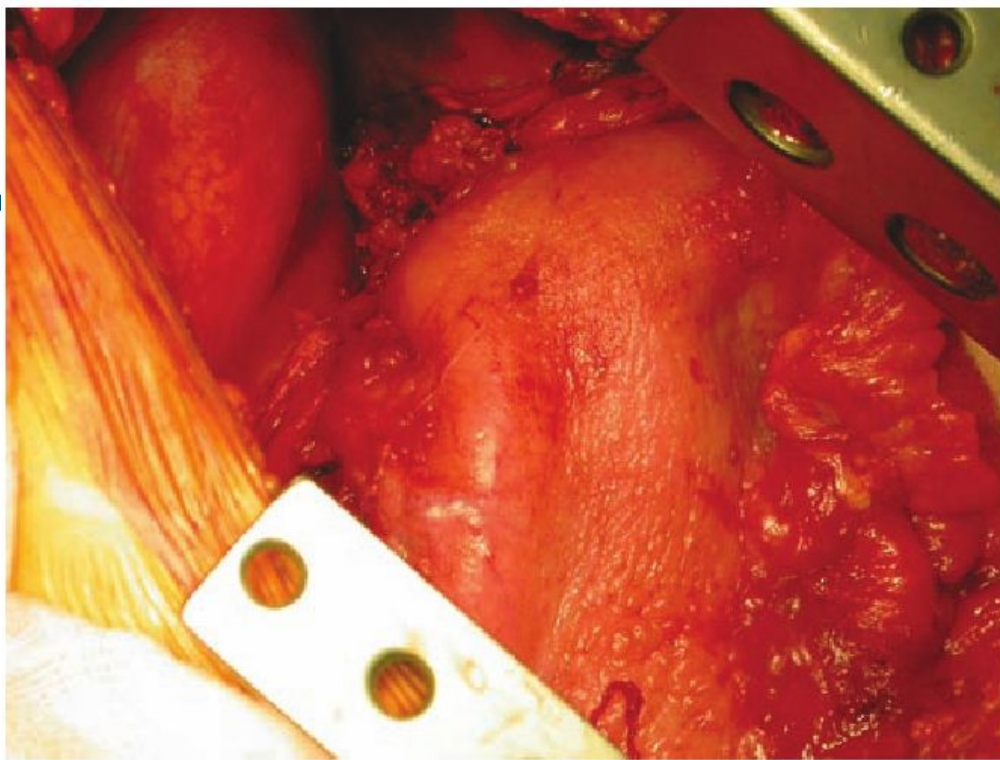
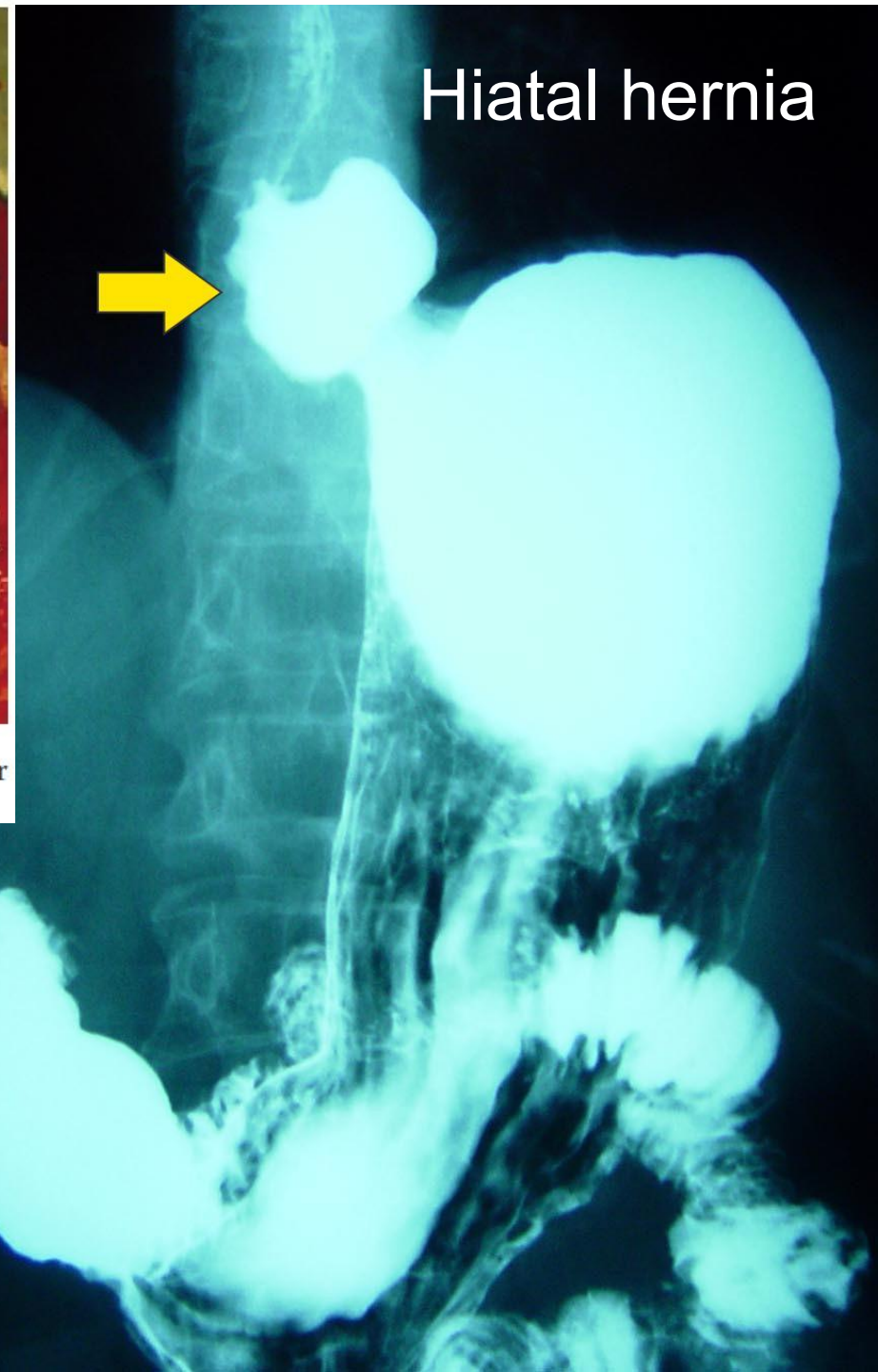
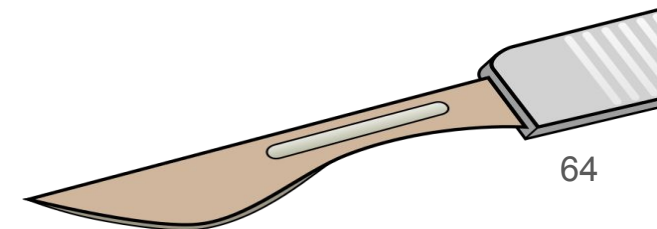


Figure 38-3. View of the incarcerated stomach from left thoracotomy after dissection of hiatal hernia sac.



Treatment

Type of hiatal hernia	First line	Second line
Type I (sliding) hernia	PPI – once daily, 8 week course treatment Inadequate symptom control: PPI – twice daily, 8 week course treatment	Laparoscopic fundoplication (Nissen or Toupet) – especially in case of symptom persistence
Types II, III, IV (paraesophageal) hernias	Laparoscopic fundoplication (Nissen or Toupet) – definitive treatment	PPI, histamine receptor antagonists, antacids – for symptom relief

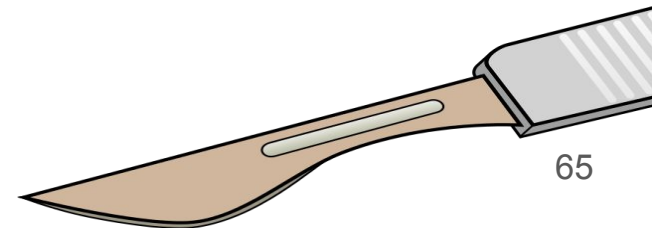


Treatment Of **Axial** Hiatal Hernia

American College of Gastroenterology

The aim is to reduce the symptoms of gastroesophageal reflux disease:

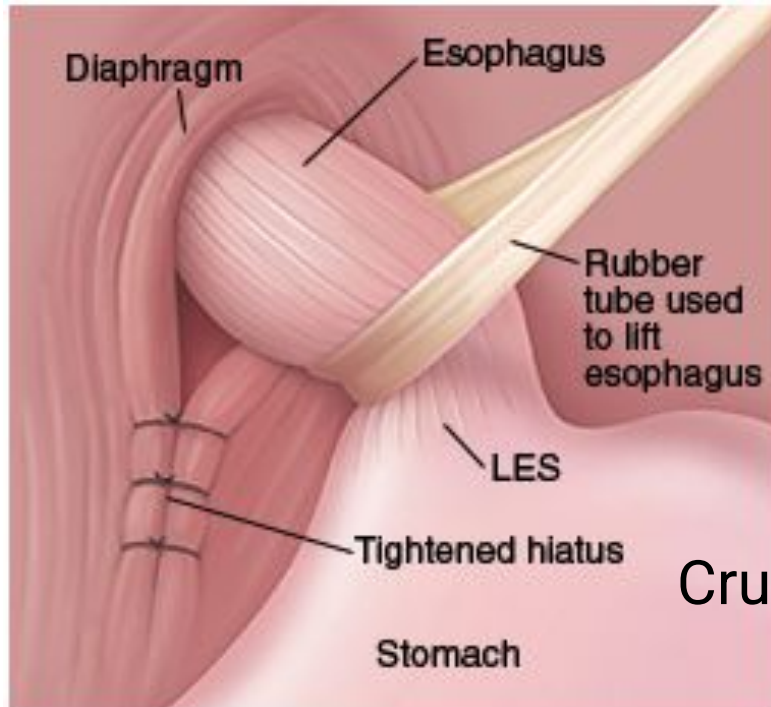
- Lifestyle modifications:
 - weight loss,
 - elevating the head of the bed by 8 inches during sleep,
 - avoidance of meals 2-3 hours before bedtime,
 - elimination of “trigger” foods such as
 - chocolate,
 - alcohol,
 - caffeine,
 - spicy foods,
 - citrus,
 - carbonated drinks
- 8-week course of PPI
 - Twice-daily PPI therapy if inadequate symptom response to once-daily PPI
 - Use the minimal dose of PPI that is sufficient to control symptoms
- Histamine 2 receptor antagonists
- Antacids.
-



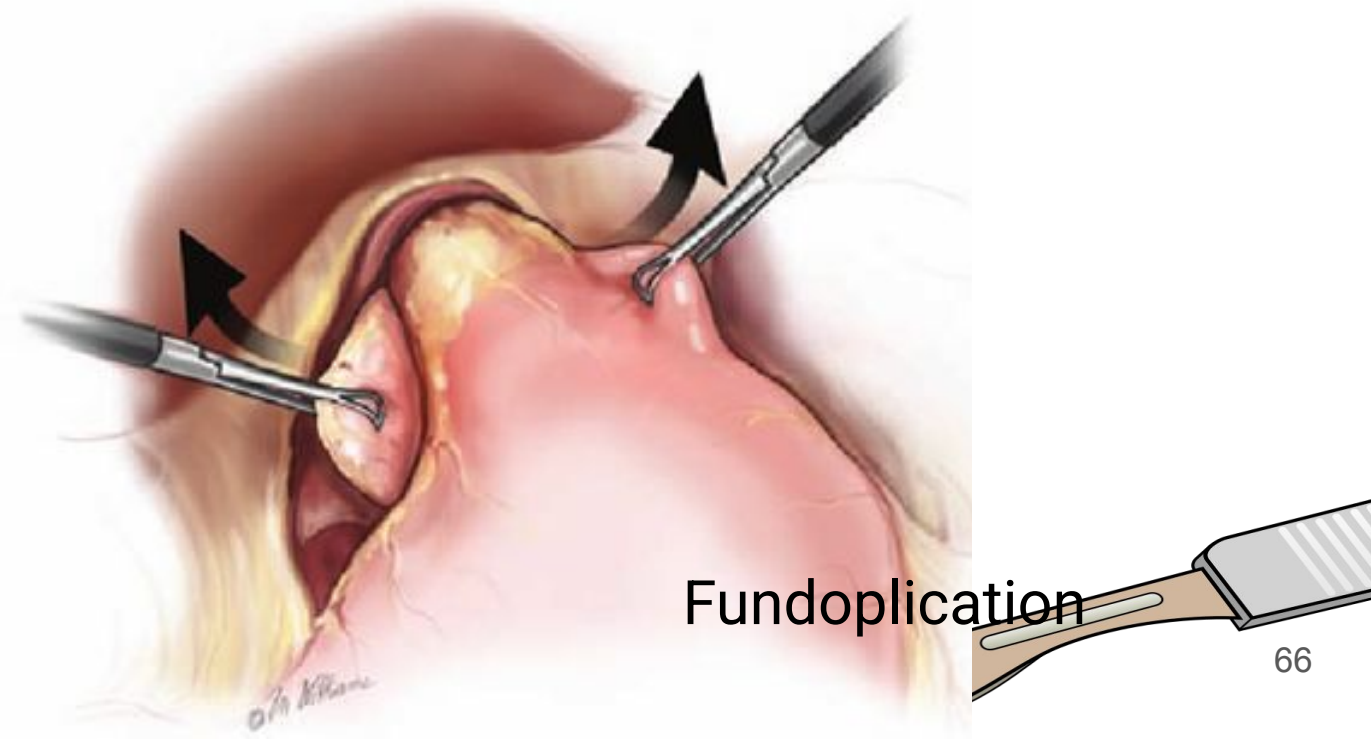
Treatment Of **Paraesophageal** Hiatal Hernia

American College of Gastroenterology

- Paraesophageal hernias ⇨ the gastric fundus has migrated above the diaphragm ⇨ high risk of obstruction.
- Most of the patients experience little or no relief with medication
- **Definitive treatment for paraesophageal hernia remains surgery: CRURORRAPHY + FUNDOPLICATION.**

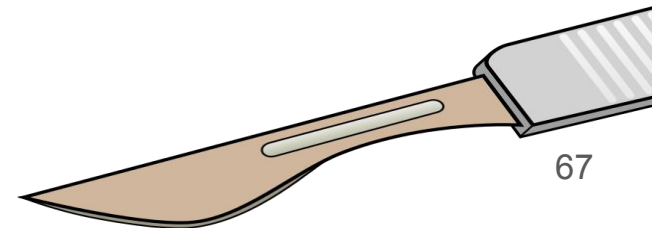


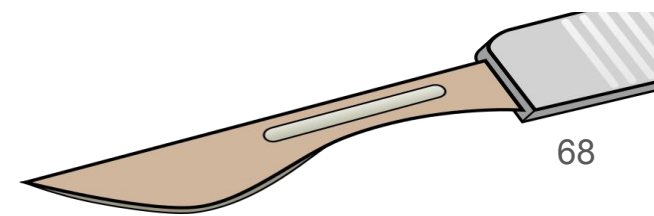
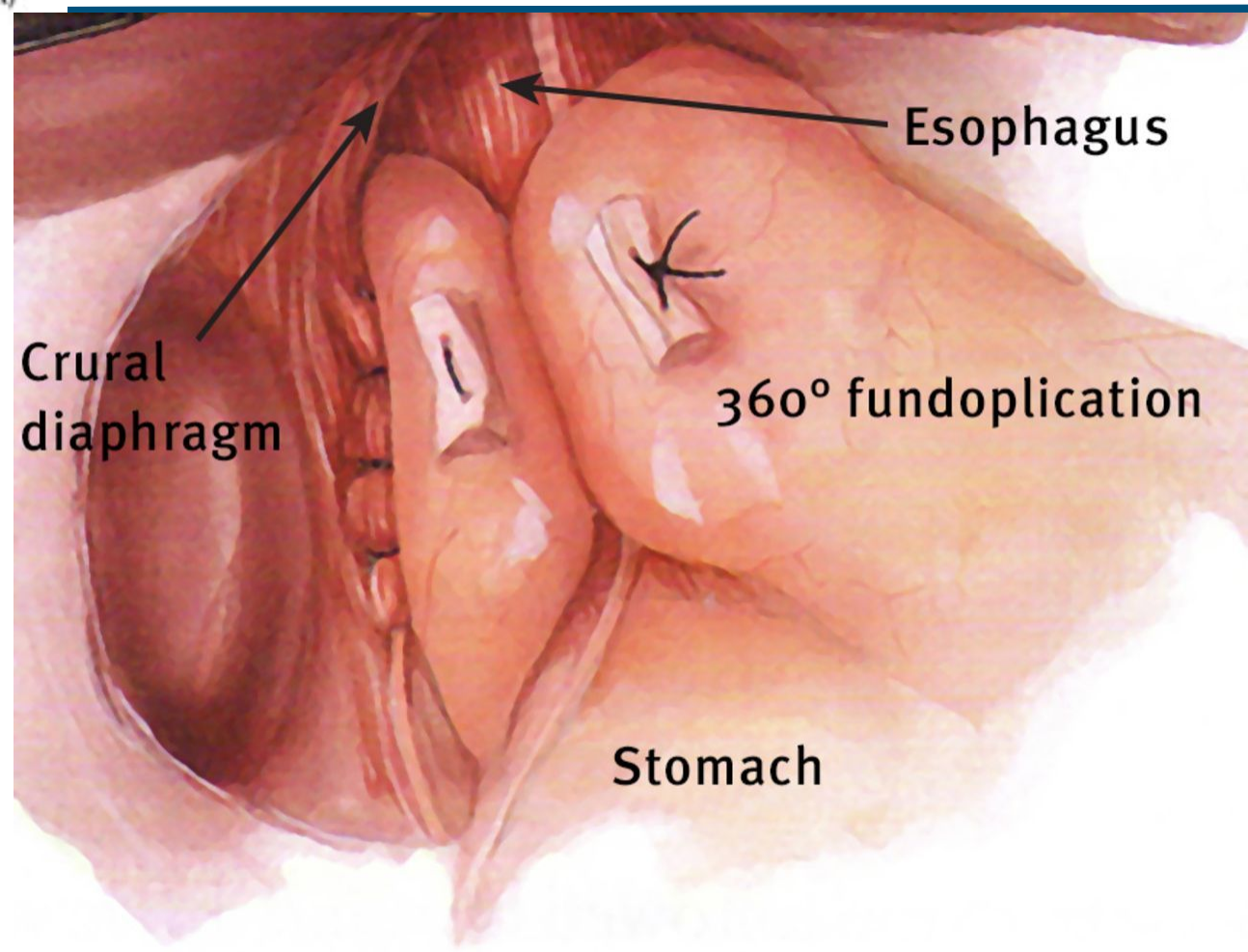
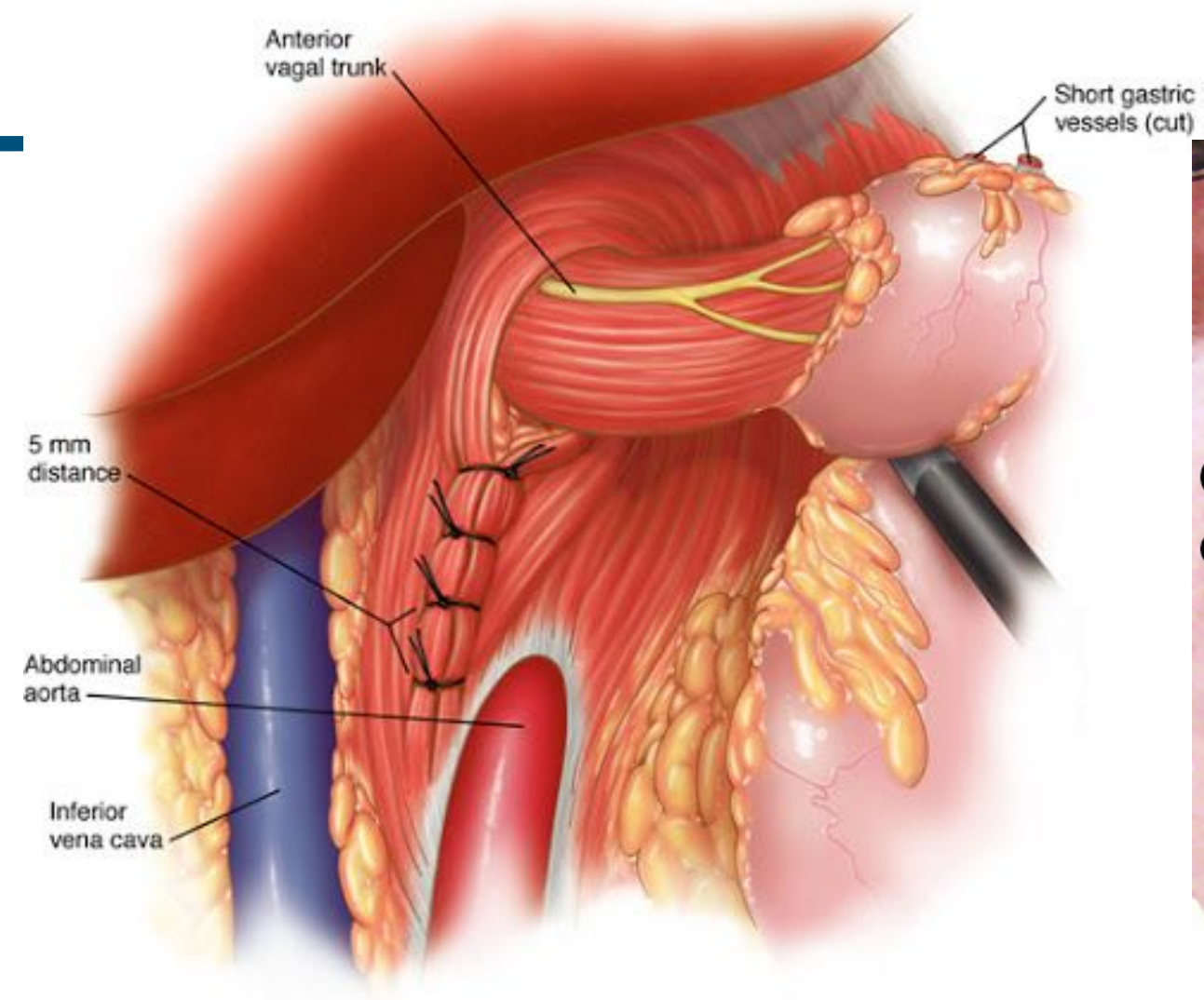
Crurorraphy

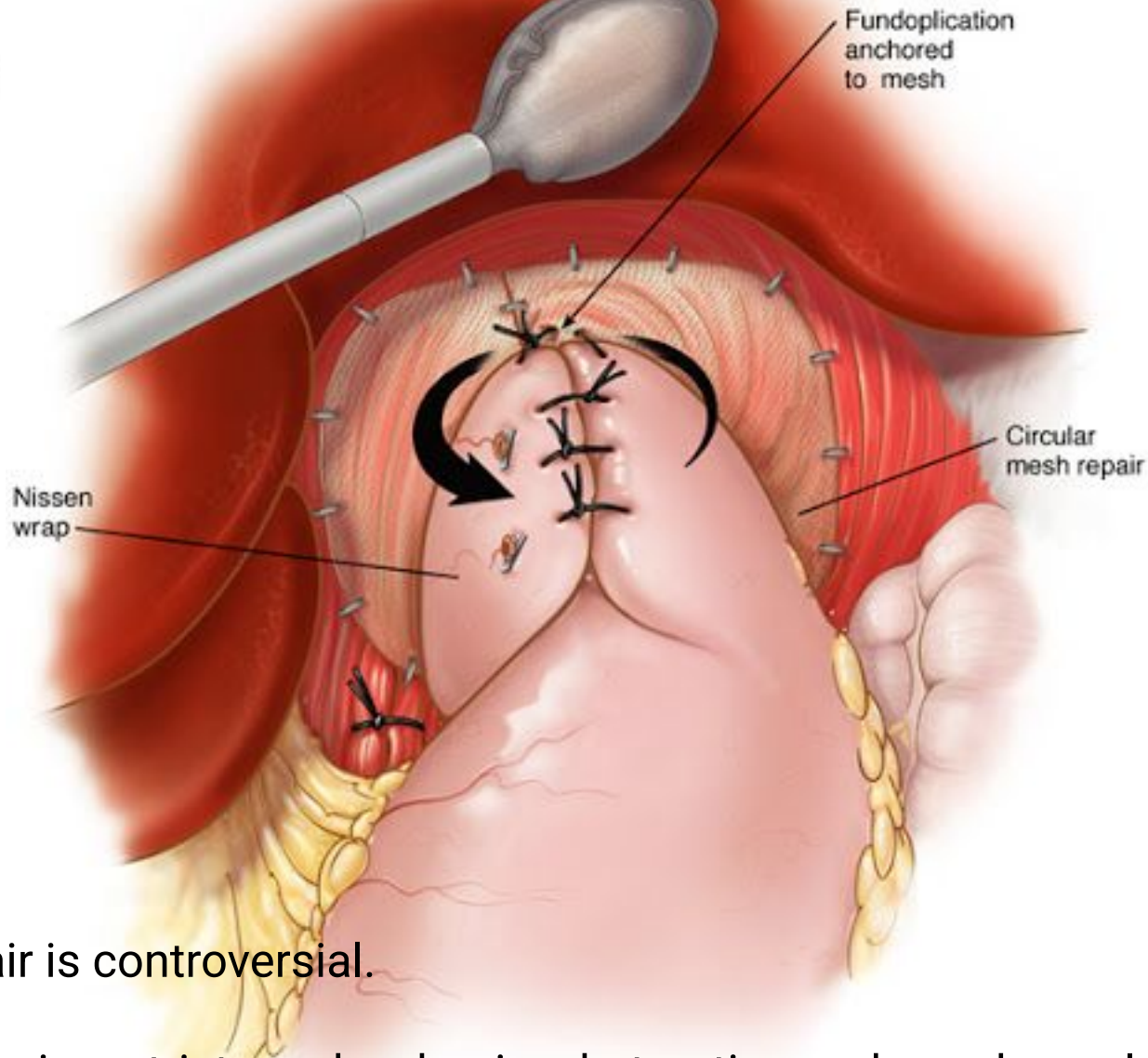
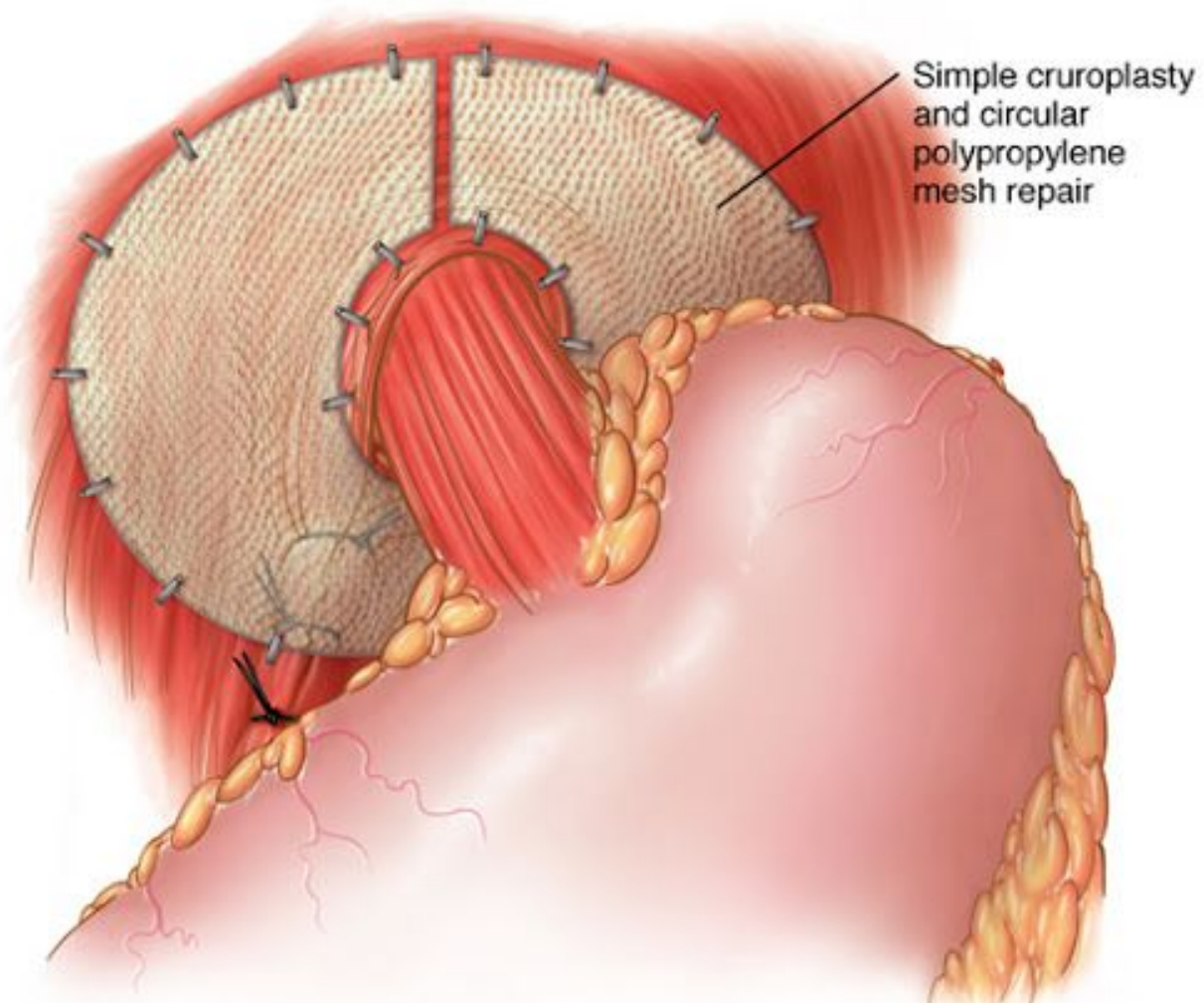


Surgical treatment

- Do not repair type I hiatal hernia in the absence of reflux disease and symptoms;
- Hiatal hernia repair can be combined with other types of bariatric surgery, such as sleeve gastrectomy and gastric bypass.
- Approach:
 - Transabdominally
 - Transthoracic approach, usually through the left chest.
- The current standard procedure is **crurorrhaphy + laparoscopic fundoplication** for both sliding and paraesophageal hernia.
- Usually, a Nissen fundoplication (360°) is performed after most hiatal hernia repairs,
- Preexisting esophageal dysmotility, in which case the Toupet fundoplication (270°) is preferred.



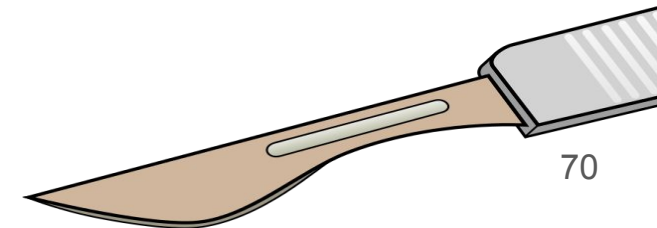
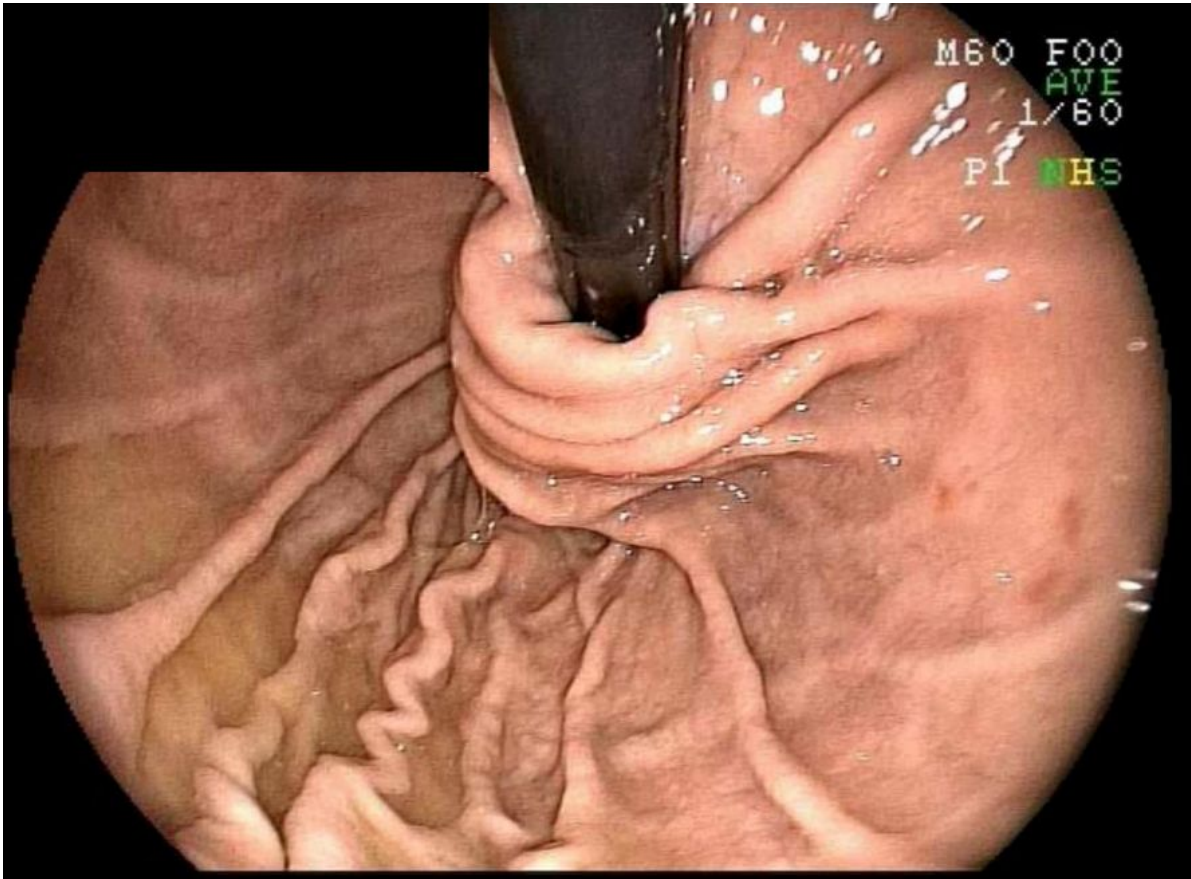



- Use of mesh during paraesophageal hernia repair is controversial.
- Synthetic and biologic mesh
- Synthetic mesh → development of esophageal erosion, stricture, dysphagia, obstruction and esophageal stenosis Lower recurrence rate is associated with short-term follow-up for biologic mesh reinforcement

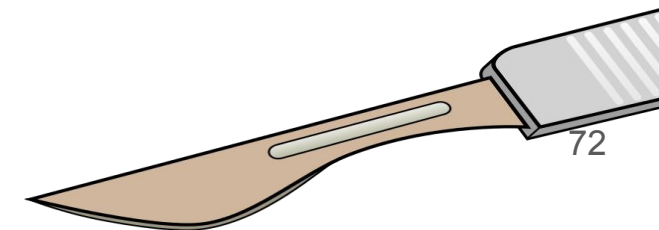
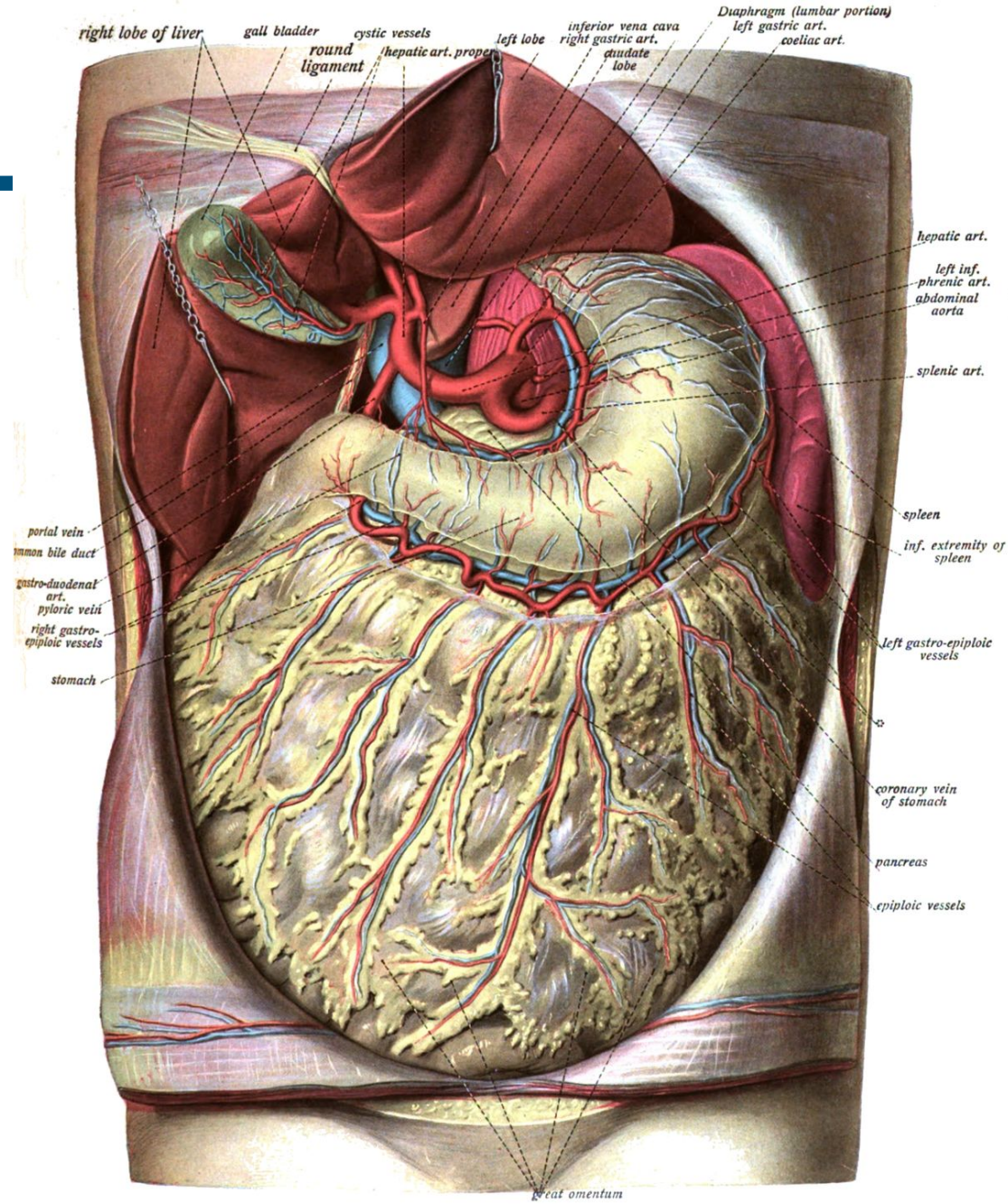
Fundoplication

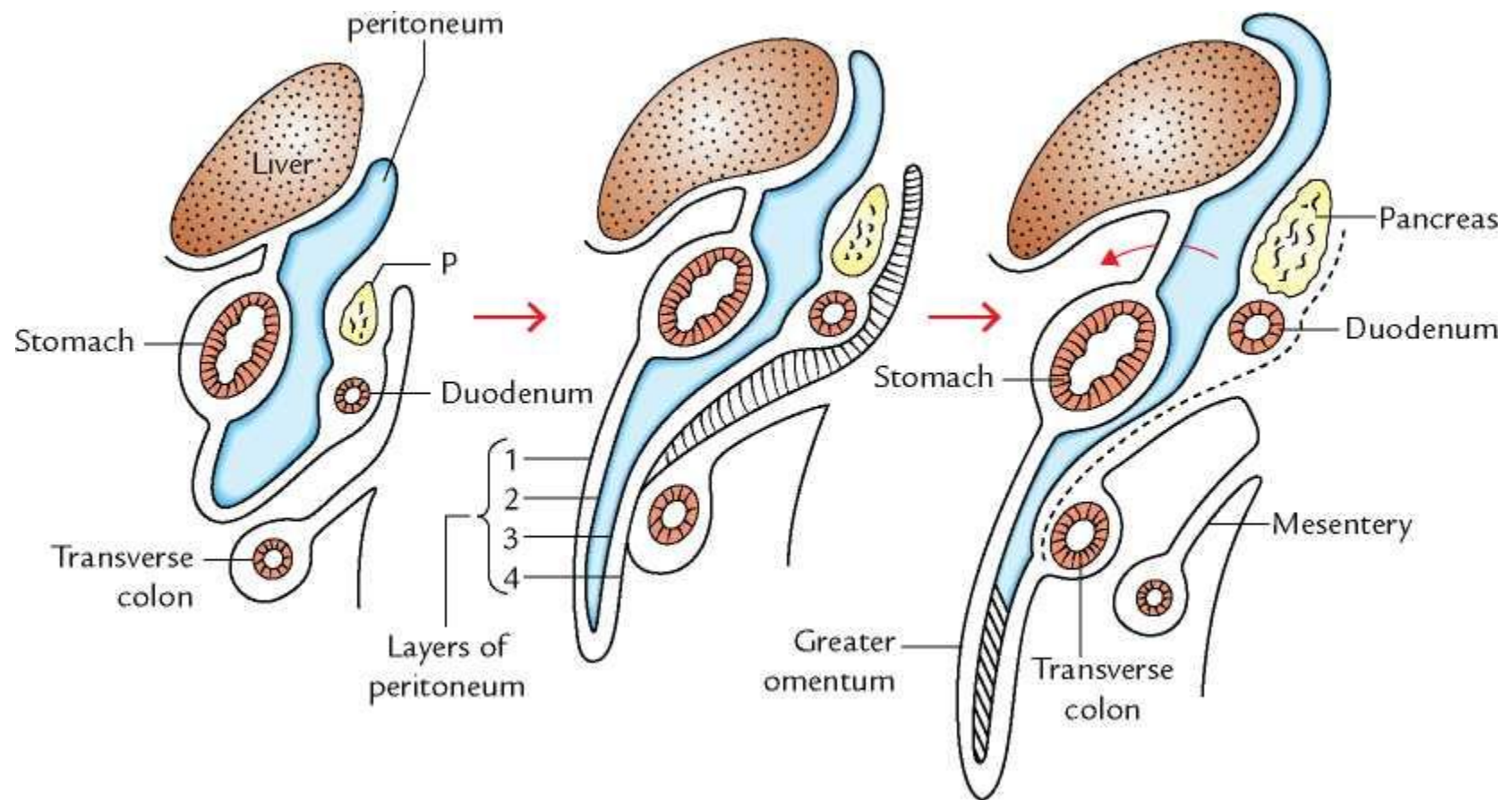
- Patient satisfaction 15 years – 85%
- Durability = 80-90% at 15 years, 75% at 20 years
- Medication use in up to 40% 5 yrs post op
- Problems:
 - gas-bloat 5-34%
 - dysphagia 3-17%
- Prolonged recovery



Omentum

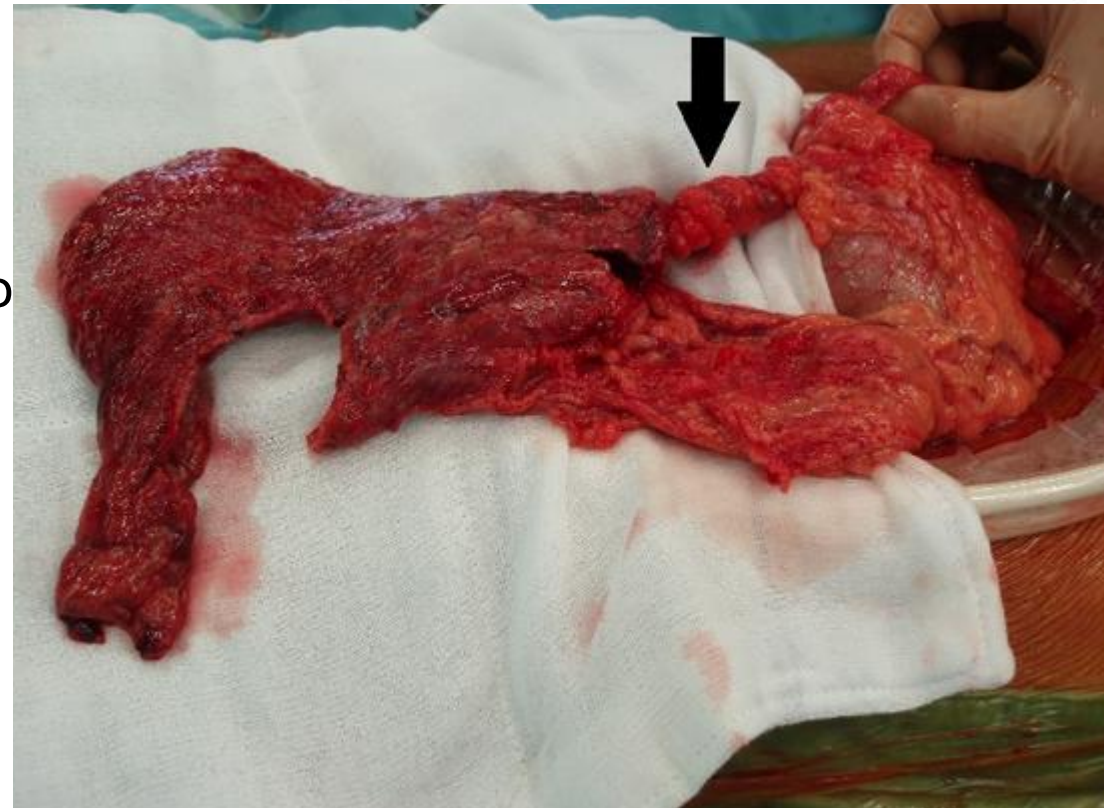
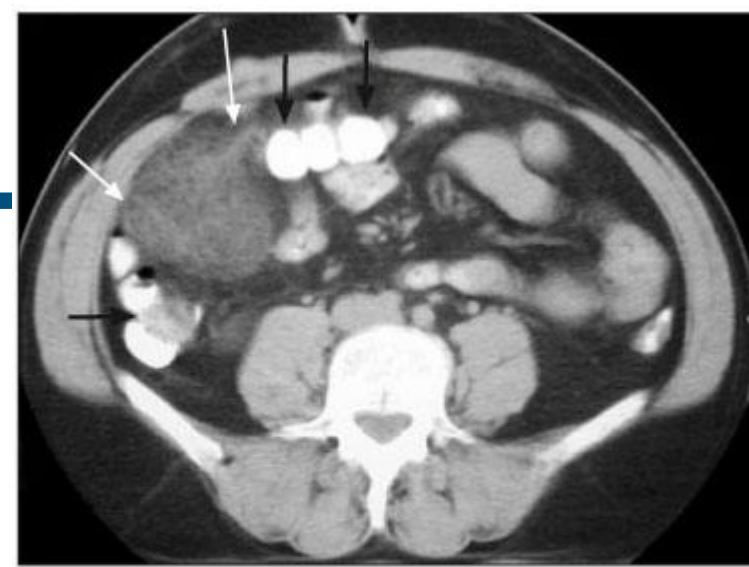
Omentum





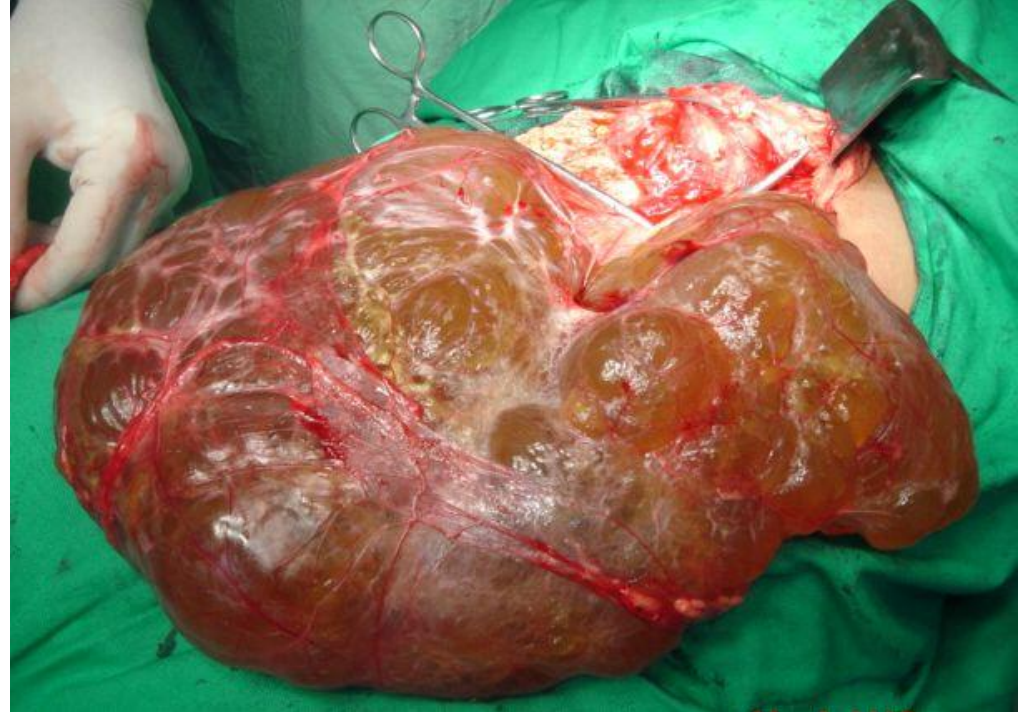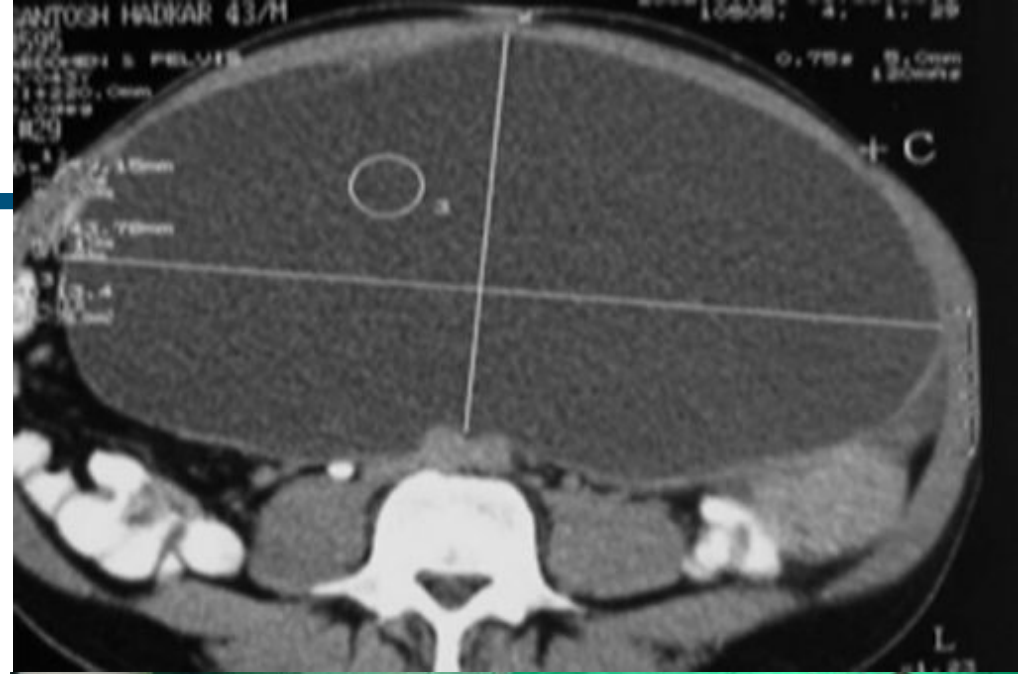Omental Infarction

- Interruption of the blood supply
 - torsion
 - thrombosis
 - venous outflow obstruction
- Abdominal pain
- Tender, palpable mass
- Abdominal CT or ultrasonography
- Supportive care
- Laparoscopic exploration and resection of the infarcted tissue



Omental Cysts

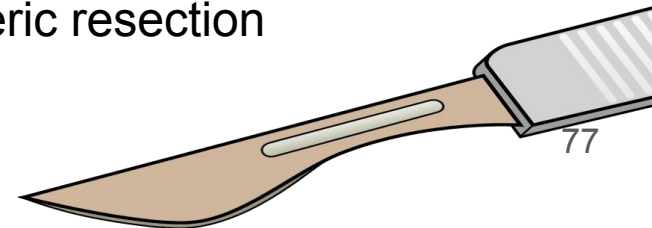
- Asymptomatic abdominal mass
- Abdominal pain
- Freely mobile intra-abdominal mass
- CT
- Abdominal ultrasound
- Resection of all symptomatic omental cysts
- Laparoscopic techniques



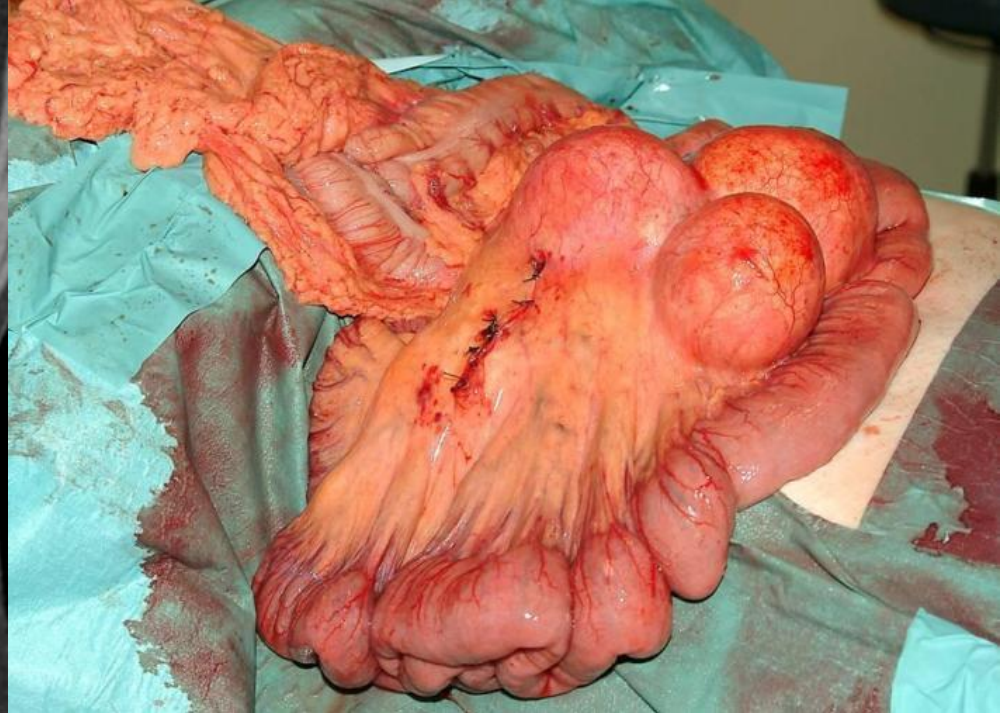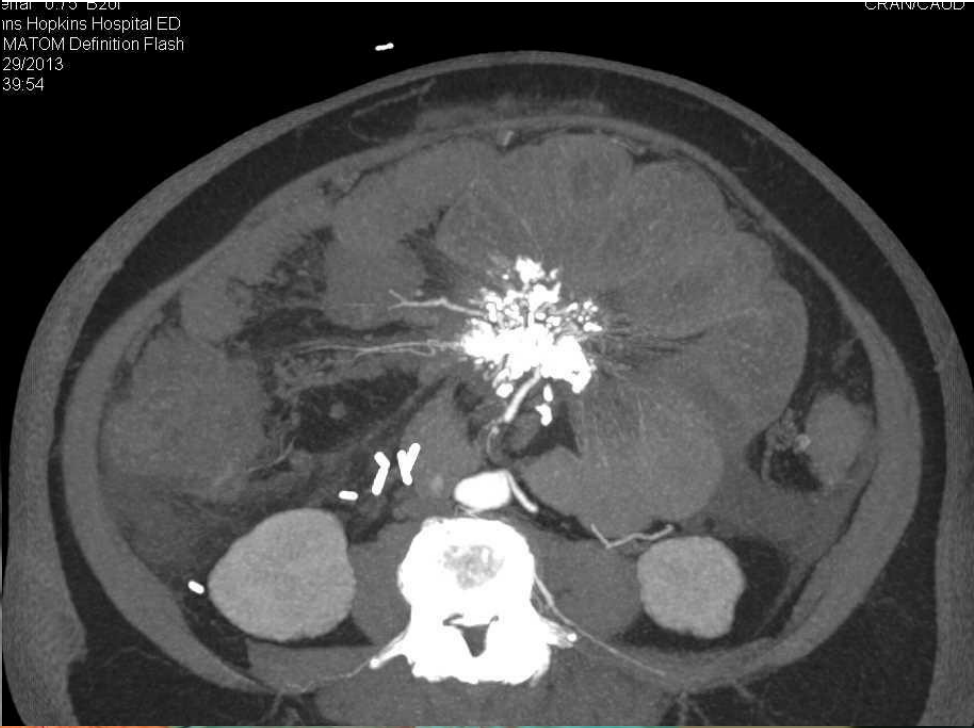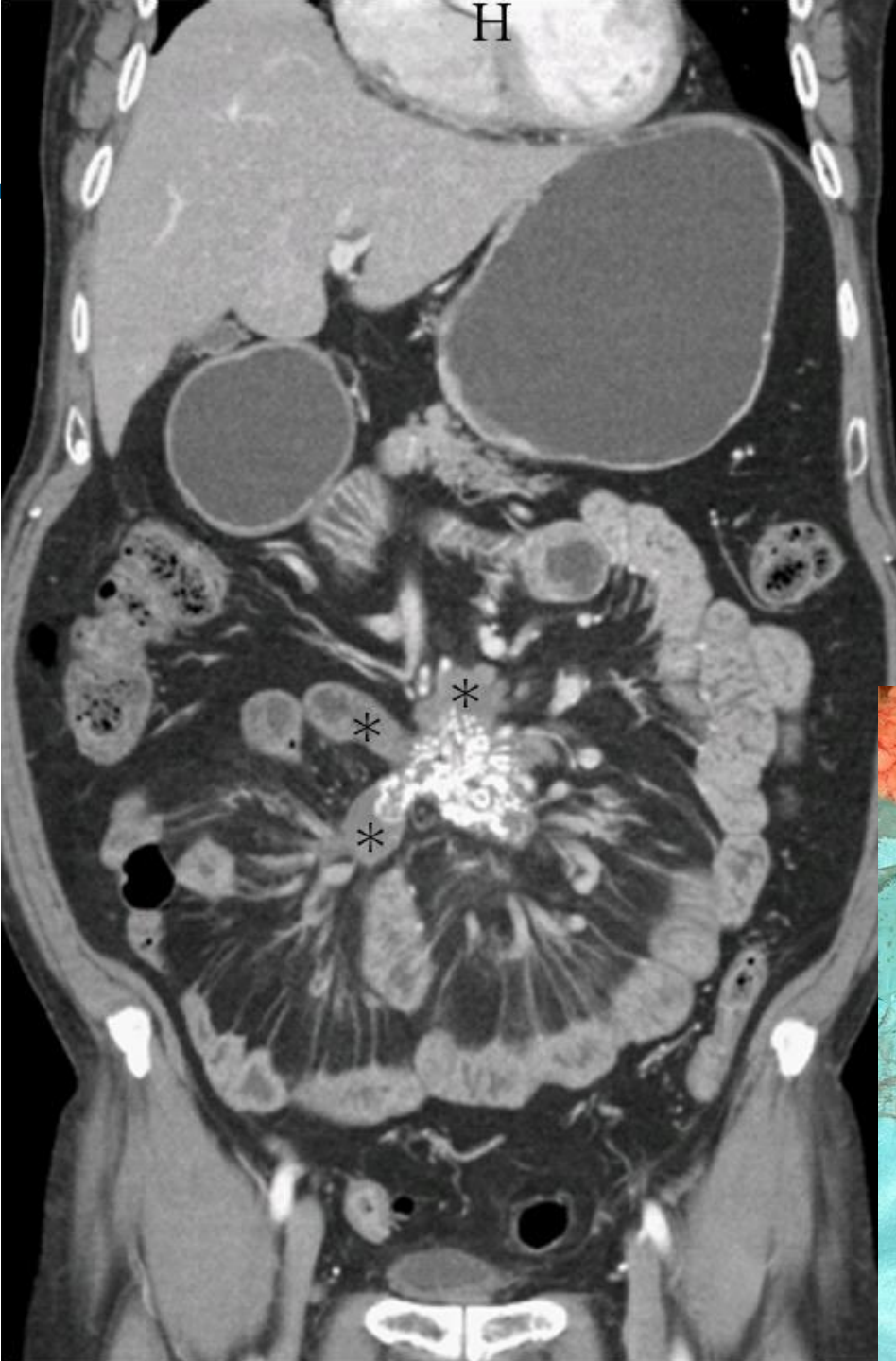Mesentery

Sclerosing Mesenteritis

- Sclerosing mesenteritis, also referred to as retractile mesenteritis, mesenteric panniculitis, or mesenteric lipodystrophy
- Inflammatory and fibrotic process involving the intestinal mesentery
- Older than 50 years of age.
- The etiology of this process is unknown
- Increased tissue density within the mesentery
- Nonneoplastic mesenteric mass
- Large swaths of mesentery without well-defined borders
- Fat tissue degeneration
- inflammation, and fibrosis
- Abdominal pain
- Presence of a mass or
- Intestinal obstruction
- CT of the abdomen shows a mass
- “Fat ring sign” or hypodense zone around the mass area
- Positron emission tomography with CT scanning has proven effective in ruling out neoplasia
- Surgical biopsy
 1. Self-limited and may even demonstrate regression if followed
 2. corticosteroids, colchicine, tamoxifen, and cyclophosphamide.
 3. Bowel and mesenteric resection

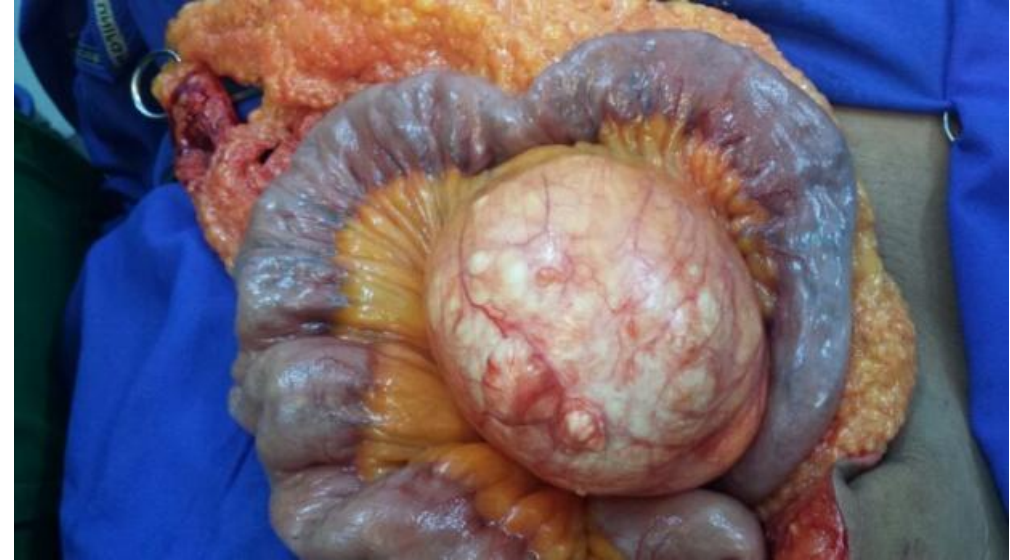

Serial 0.75 L201
ins Hopkins Hospital ED
MATOM Definition Flash
29/2013
39:54

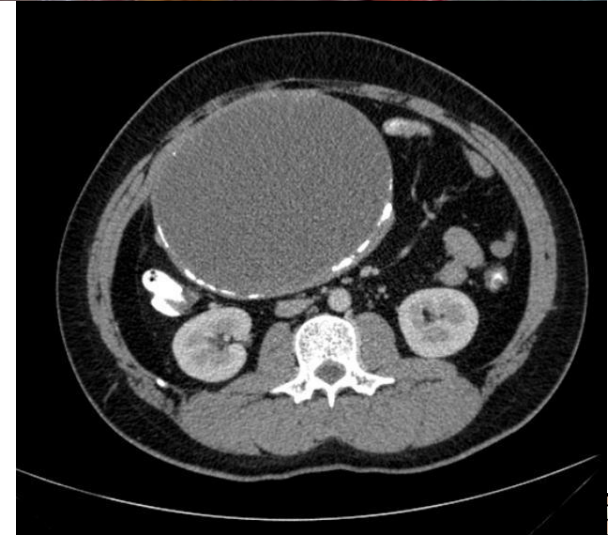


Mesenteric Cysts

- benign lesions
 - Asymptomatic
 - Symptoms of a mass lesion
- Acute pain
 - rupture
 - torsion of the cyst
 - acute hemorrhage into the cyst cavity
 - compression of adjacent structures

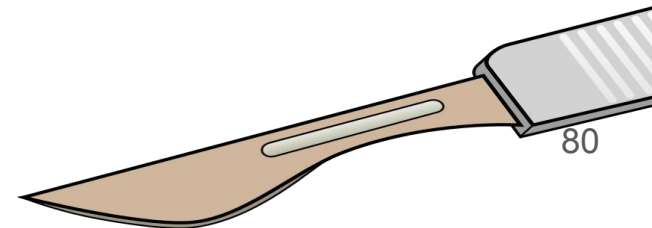


- Mobile mass lesion
- Mobile only from the patient's right to left or left to right (Tillaux's sign)
- CT, US, and MRI
- When symptomatic → surgically excised either openly or laparoscopically
- High propensity to recur after drainage alone



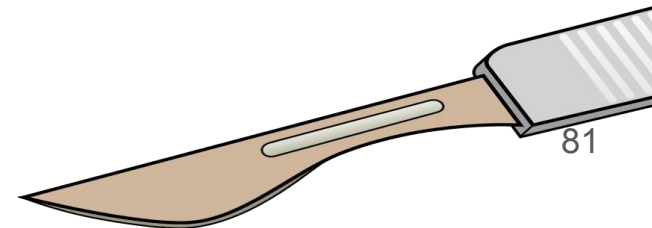
Retroperitoneal Fibrosis

- Hyperproliferation of fibrous tissue in the retroperitoneum
- Autoimmune?
- Inflammatory reaction is predominated by T-helper cells, plasma cells, and macrophages, but is subsequently replaced by collagen-synthesizing fibroblasts.
- The fibrotic process begins in the retroperitoneum just below the level of the renal arteries. Fibrosis gradually expands, encasing the ureters, inferior vena cava, aorta, mesenteric vessels, or sympathetic nerves.
- Primary - idiopathic = Ormond's disease
- Secondary - reaction to an inciting inflammatory process, malignancy, or medication
- Prostate, pancreas, and gastric cancer, as well as nonHodgkin's lymphoma, stromal tumors, and carcinoid tumors. Retroperitoneal fibrosis has been described in association with autoimmune disorders including ankylosing spondylitis, systemic lupus erythematosus, Wegener's granulomatosis, and polyarteritis nodosa.
- methysergide, β -blockers, hydralazine, α -methyldopa,



- Dull, poorly localized abdominal pain
- Leg swelling, intermittent claudication, oliguria, hematuria, or dysuria
- Palpation of an abdominal or flank mass,
- Lower-extremity edema
- Diminished lower-extremity pulses
- Blood urea nitrogen and/or creatinine levels
- US, CT, MRI

- Corticosteroids, with or without surgery
- Open or laparoscopic ureterolysis
- Ureteral stenting
- Iliocaval thrombosis require anticoagulation
- Endovascular interventions for ilio caval occlusion
- Prednisone





"HOW CAN I EVER FORGET OUR WEDDING DAY WHEN I GOT A HERNIA CARRYING YOU OVER THE THRESHOLD?"

