

Type the Title of Your Manuscript Here

First Author^{1,*}, Second Author^{1,2}, Third Author²

¹First affiliation institution, City, Country

²Second affiliation institution, City, Country

*Corresponding Author. Email: typeyouremail@here.com

Telp: +62-12345678

Abstract

Provide an abstract of no more than 250 words. Abstract for case report articles should be written in one paragraph. Information should include: background, key points from the case which consist the clinical question or diagnostic problem and provide essential information, as well as the main lessons to be learned from the case. Type your abstract here.

Keywords: Keywords contain three to eight words/phrases separated with coma.

Introduction

This guideline is a template for case report article submission for Indonesian Journal of Basic and Clinical Studies (IJBCS). Authors are allowed to modify this template for submission purpose. All submitted manuscripts must not previously published and not under consideration for publication elsewhere. Manuscripts may come from any country but must be written in English. There is no submission and processing charges for this journal.

In the Introduction, you should briefly summarize why this case report is important and provide enough background. You also need to provide an explanation of the focus of the case report. Use present tense to write any facts or common ideas as the background of the study.

Case Report

When writing a case report article, make sure that the total of works (not including abstract and references) in the manuscript is less than 2,500 words. The submission file is in Microsoft Word file (.doc/.docx) formatted as standard A4 page setup with double-space and 1-inch margin on the left and right sides. Use 12-point Times New Roman font.

Case descriptions or summaries are the focus of the case report. Cases are better presented in chronological order and detailed enough for the reader to draw their own conclusions about the validity of the case. Current medical conditions (such as physical examination findings, investigation results, including imaging and laboratory results, differential diagnosis, management, follow-up, and final diagnosis) and medical history (such as relevant family history and clinical history of subject), must be clearly explained in chronological order.

We encourage authors to submit all relevant images of the cases. Please only send images of the affected area to maintain subject confidentiality. Images require brief but clear

descriptions. Tables and/or Figures must be used to uncover chronological findings or to compare observations using different methods. You can include 6 figures and/or tables in total. Use past tense to write any information presented in this section.

Discussion

The purpose of the Discussion is to state your interpretations and opinions, as well as to explain the implications of your findings. Discussion should explore the significance of the results of the work, not repeating them, to compare case reports with what is already known in the literature and show their uniqueness, to gain new knowledge and application to practice. Each case boundary must be explained. The added value of the cases presented must be disclosed, as well as lessons that can be learned from the cases presented, especially if there are new recommendations for patient or management diagnosis, can be suggested.

The discussion section of the case report is not designed to provide a comprehensive literature review and citation of all references; therefore, all references cited must be critically evaluated. A brief statement of the lessons learned from this case can be expressed through evidence-based recommendations in the last part of Discussion.

Conclusion

You may state the main conclusion and the most important information of the report in the Conclusion section. Reaffirm the uniqueness of the case presented and lessons learned from the case report.

Acknowledgment

The acknowledgment should be filled with other contributors those are not qualified in the author's list. Research grant that supported the study should be listed in this section as well.

Authors' Contributions

In order to qualify for authorship of the submitted manuscript, every of the listed authors should have made substantial intellectual contributions both to the research and to its preparation.

AB and CD were involved in concepting and planning the research, EF and GH performed the data acquisition/collection, EF and IJ calculated the experimental data and performed the analysis, AB drafted the manuscript and designed the figures, CD aided in interpreting the results. All authors took parts in giving critical revision of the manuscript.

References

1. Sandra F, Esposti MD, Ndebele K, Gona P, Knight D, Rosenquist M, *et al.* Tumor Necrosis Factor-Related Apoptosis-Inducing Ligand Alters Mitochondrial Membrane Lipids. *Cancer Res.* 2005; 65 (3): 8286-97.
2. Murray PR, Rosenthal KS, Kobayashi GS, Pfaller MA. *Medical microbiology*. 4th ed. St. Louis: Mosby; 2002.
3. Rosenberg GA. Matrix metalloproteinase and proteolytic opening of the blood brain-barrier in neuroinflammation. In: deVries E, Prat A, editors. *The Blood-brain Barrier and Its Microenvironment Basic Physiology to Neurological Disease*. New York: Taylor and Francis Group; 2005. p.335-58.
4. Arlauckas SP. Near infrared fluorescent choline kinase alpha inhibitors for cancer imaging and therapy [Dissertation]. Philadelphia: University of Pennsylvania; 2015.
5. Medline Plus [Internet]. Bethesda: US National Library of Medicine; ©2009. Diabetic Kidney Problems [update 2015 Nov 2; cited 2015 Nov 16]. Available from: <https://www.nlm.nih.gov/medlineplus/diabetickidneyproblems.html/>.
6. Fledelius HS. Myopia and significant visual impairment: global aspects. In: Lin LLK, Shin YF, Hung PT, editors. *Myopia Updates II: Proceedings of the 7th International Conference on Myopia 1998 Nov 17-20, Taipei*. Tokyo: Springer; 2000. p.3-17.

Notes:

References and citation must be according to the Vancouver Systems. Where available, URLs for the references have been provided. For research article, 20 or less references are allowed.

Figures/Tables

Table 1. Type your table caption with 10-point Times New Roman font. Number tables consecutively in accordance with their appearance in the text. Present the table with no vertical lines.

Parameter	Value
Parameter a (unit)	Mean±SD
Parameter b (unit)	Mean±SD
Parameter c (unit)	Mean±SD

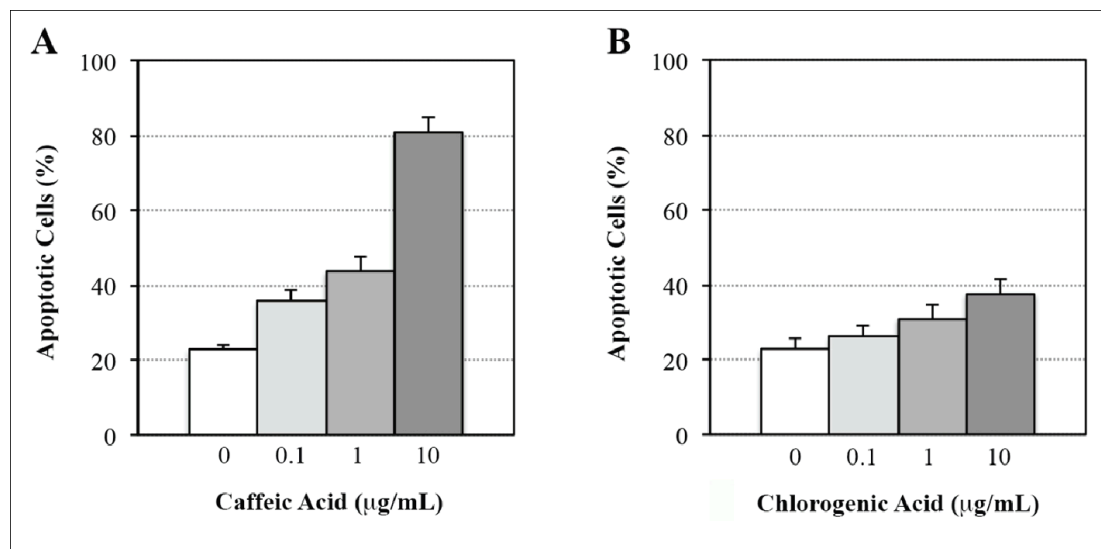


Figure 1. Type your figure caption with 10-point Times New Roman font. Provide the respective high resolution figure. Number figures consecutively in accordance with their appearance in the text. Please provide proof of permission that has been obtained to reproduce illustrations from other publication (Adapted with permission from Cell and Biopharmaceutical Institute).




Figure 1. Morphology of cells derived from dental pulps and periodontal membranes. Isolated cells derived from dental pulps (A) and periodontal membranes (B) were cultured according to Materials and Methods. Cells in passage 5 were documented under an inverted light microscope. White bar: 10 μm .

Figure 2. Type your figure caption with 10-point Times New Roman font. Provide the respective high resolution figure. Number figures consecutively in accordance with their appearance in the text. If there's two parts of the figure, make sure you explain what (A) and (B) are. A size bar should be provided for any morphology, histology, or histopathology pictures. For example: white bar = 100 μm .