ANATOMY & PHYSIOLOGY (H): DIGESTIVE SYSTEM

https://learn.vcs.net/pluginfile.php/367232/mod_resource/content/0/Unit%204%20Questions.pdf

Know all of the bold terms and italic terms in this chapter.

What are the other names of the digestive tract?

- alimentary tract
- gastrointestinal tract

Be able to name all of the primary and accessory structures associated with this system.

- Primary: oral cavity (mouth), pharynx (throat), esophagus, stomach, small intestine, large intestine, rectum, and anus
- Accessory: teeth, tongue, salivary glands, liver, pancreas, and gallbladder

Name and describe the six functions of the digestive system.

- *Ingestion* takes place when food and drink enter the oral cavity (mouth) of the digestive tract
- *Mechanical digestion* is the crushing and shearing that makes solid foods easier to propel along the digestive tract. It also increases their surface area, making them more susceptible to attack by enzymes. The tongue and the teeth in the oral cavity begin the process. Swirling, mixing, and churning motions of the stomach and intestines provide mechanical digestion after ingestion.
- *Chemical digestion* refers to the chemical breakdown of food into small organic molecules that can be absorbed by the digestive epithelium.
- *Secretion* is the release of water, acids, enzymes, buffers, and salts by the epithelium of the digestive tract, the glandular organs, and the gallbladder
- *Absorption* is the movement of small organic molecules, electrolytes (inorganic ions), vitamins, and water across the digestive epithelium and into the interstitial fluid of the digestive tract.
- *Defecation* is the elimination of wastes from the body. Within the digestive tract, waste products from glandular and secretory organs mix with indigestible materials of the digestive process and gallbladder. These waste products are dehydrated, compacted, and ejected from the digestive tract as feces

Name and describe the four histological layers of the GI tract.

- **Be sure you know the composition and function of each. Also know how each layer is controlled, if appropriate.**
    - Mucosa: mucous membrane
        - Epithelium
        - Mucosal epithelium
        - Lamina propria: areolar tissue
        - Permanent transverse circular folds
        - Villi: fingerlike projections that further increase the area for absorption
        - Circular folds and villi are moved by contractions of this layer, called the muscularis mucosae
    - Submucosa: a layer of dense irregular connective tissue that binds the mucosa to the muscular layer
        - Contains numerous blood vessels and lymphatic vessels
        - Along the outer margin, contains a network of nerve fibers, sensory neurons, and parasympathetic motor neurons (submucosal plexus)
        - Controls contractions of the smooth muscle in the muscularis mucosae

        - Regulates the secretion of digestive glands
    - Muscular layer: a band of smooth muscle cells arranged in an inner circular layer and an outer longitudinal layer
        - Contractions agitate and propel materials along the digestive tract
        - Controlled by the myenteric plexus between the circular and longitudinal layer
            - Contains parasympathetic ganglia, sensory neurons, interneurons, and sympathetic post-ganglionic fibers
            - Parasympathetic stimulation increases muscular tone and activity
            - Sympathetic stimulation promotes muscular inhibition and relaxation
    - Serosa: serous membrane covering the muscular layer along most portions of the digestive tract enclosed by the peritoneal cavity
        - This visceral peritoneum is continuous with the parietal peritoneum, which lines the inner surfaces of the body wall
        - Mesenteries: double sheets of serous membranes composed of the parietal and visceral peritoneum
            - Suspend some regions of the digestive tract
            - Loose connective tissue sandwiched between the epithelial surfaces of the mesenteries provides a pathway for blood vessels, nerves, and lymphatic vessels
            - Stabilize positions of attached organs
            - Prevent the intestines from becoming entangled during digestive movements or sudden changes in body position
        - No serosa covers the muscular layer of the oral cavity, pharynx, esophagus, and rectum; instead surrounded by an adventitia that firmly attaches these regions of to adjacent structures
            - Adventitia: dense connective tissue with collagen fibers

Movement of digestive materials

- **What cells trigger contraction?**
    - Pacesetter cells
- **What are the two types of movement and what is the difference?**
    - Peristalsis: movement of material along the tract
        - Achieved through waves of contractions moving along the digestive tract
            - Circular muscles contract behind the bolus
            - Longitudinal contraction shortens adjacent segments of the tract
    - Segmentation: mechanical mixing of the material
        - Churn and break up digestive materials to achieve mixing
        - Do not follow a set pattern

The Oral Cavity

- **Know the other name of this region**
    - Buccal cavity
- **Give four functions of this region**
    - Senses and analyzes food before swallowing
    - Mechanically digests food through the use of the teeth, tongue, and surfaces of the palate
    - Lubricates food by mixing it with mucus and salivary gland secretions

    - Begins limited chemical digestion of carbohydrates and lipids with salivary enzymes
- **Know the boundaries**
    - The lips anteriorly, the cheeks laterally, the floor of the mouth inferiorly, the oropharynx posteriorly, and the palate superiorly
- **What are the gingivae?**
    - Pink ridges of oral mucosae that surround the bases of the teeth
    - Cover the tooth-bearing surfaces of the upper and lower jaws
- **What are the functions of the tongue?**
    - Mechanical digestion by compression, abrasion, and distortion
    - Manipulation to assist in chewing and to prepare food for swallowing
    - Sensory analysis by touch, temperature, and taste receptors
    - Glands under the tongue secrete lingual lipase, that digests lipids
- **What are the functions of the tonsils?**
    - Lingual tonsils: clusters of lymphoid nodules that help resist infections
        - Marked by a pair of prominent lateral swellings at the base of the tongue
- **Name each of the salivary glands. Know the location and different secretions of each.**
    - Parotid: back of each side of the mouth
        - Under the skin covering the lateral and posterior surface of the mandible
        - Produce a secretion rich in salivary amylase, an enzyme that breaks down starches (complex carbohydrates) into smaller molecules that can be absorbed by the digestive tract
    - Sublingual: under the tongue
        - Beneath the mucous membrane of the floor of the mouth.
        - Secretions contain more buffers and mucus than enzymes
    - Submandibular: double chin area
        - in the floor of the mouth along the inner surfaces of the mandible
        - Secretions contain more buffers and mucus than enzymes
- **Know the composition and function of saliva**
    - 99.4% water, in addition to mucins and an assortment of ions, buffers, waste products, metabolites, and enzymes
        - Mucins: glycoproteins that absorb water and form mucus
        - Buffers: keep the pH of your mouth near 7 and prevent the buildup of acids produced by bacteria
    - Large quantities of saliva lubricate the mouth and dissolve chemicals that stimulate the taste buds; allows for swallowing to occur
- **Teeth**
    - **Be able to name and describe the differences between each**
        - Incisors: blade-shaped teeth at the front of the mouth
            - Useful for clipping or cutting, as when you nip off the tip of a carrot stick
        - Canines (cuspid): conical, with a sharp ridge line and a pointed tip
            - Used for tearing or slashing
        - Premolars (bicuspids) and Molars: have flattened crowns with prominent ridges
            - Used for crushing, mashing, and grinding
            - Molars are in the back

- **Know the anatomy of a tooth**
- **Know the functions of teeth**
  - Carry out mastication, or chewing
    - Breaks down connective tissues in meat and the fibers in vegetables
    - Helps saturate the food with salivary secretions
- **Know how many baby and adult teeth we have**
  - Baby: 20
  - Adult: 32

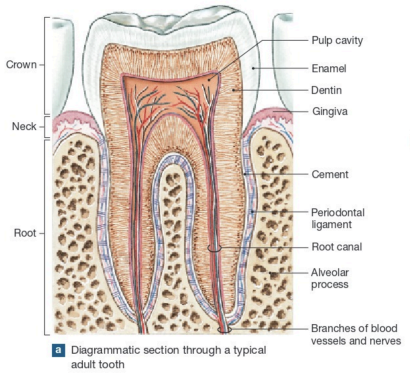

a Diagrammatic section through a typical adult tooth

The Pharynx

- **Where is this and what are the three divisions of this region?**
  - Throat; serves as a common passageway for solid food, liquids, and air
  - Divisions
    - Nasopharynx
    - Oropharynx
    - Laryngopharynx

The Esophagus

- **What and where is this?**
  - Connected to laryngopharynx
  - A muscular tube that conveys solid food and liquids to the stomach
- **Know the sphincters and their function**
  - Upper Esophageal Sphincter: prevents the entry of air into the esophagus during breathing
  - Lower Esophageal Sphincter: normally in active contraction to prevent backflow of materials from the stomach into the esophagus
    - Relaxes during swallowing
- **How do we swallow and why can we do this upside down?**
  - Swallowing upsidedown is possible because of the use of peristalsis rather than use of gravity
- **What are the three phases of swallowing?**
  - Movement of the Bolus
  - Buccal Phase: voluntary
  - Pharyngeal Phase: involuntary
  - Esophageal Phase: involuntary

The Stomach

- **Know the functions of the stomach**
  - Storage of ingested food
  - Mechanical digestion of ingested food
  - Disruption of chemical bonds in food through the action of acids and enzymes
  - Production of intrinsic factor, a compound necessary for the absorption of vitamin B12 in the small intestine
- **Know the regions of the stomach**

    - Cardia: connects to the esophagus; smallest region
    - Fundus: top bulge
    - Pylorus: connects the stomach with the small intestine
        - The pyloric sphincter regulates the flow of chyme between the stomach and small intestine
    - Body - labeling
- **Of what is the gastric wall composed? Know what is secreted and the types of cells involved.**
    - Simple columnar epithelium dominated by mucous cells
    - Mucous cells: secrete alkaline mucus
        - protect epithelial cells from acids, enzymes, and abrasives
    - Gastric pits: shallow depressions that open onto the stomach surface
        - Mucous cells at the base of gastric pits divide to replace shed epithelial cells, with a lifespan of 3–7 days
    - Fundus and body: gastric pits connect to gastric glands extending into the lamina propria
        - Gastric glands contain:
            - Parietal cells: Produce components of gastric acid
                - Secrete intrinsic factor and hydrochloric acid
            - Chief cells: Secrete pepsinogen, an enzyme precursor
                - Protein Degradation (pepsinogen > pepsin after HCl)
            - Gastric glands secrete approximately 1500 mL of gastric juice daily
            - The pylorus contains gastric glands with endocrine cells that regulate gastric activity
- **What are the three phases of regulation of gastric activity? What is the difference between each? Be sure you know the hormones involved in each phase.**
    - Cephalic phase: begins when you sense or think of food
        - Preps stomach for food
    - Gastric phase: begins when food arrives in the stomach
        - Triggers local reflexes controlled by the submucosal and myenteric plexuses
        - Mixing waves
        - stimulates parietal and chief cells
        - Gastrin released stimulating contractions
        - pH dropped
    - Intestinal Phase: Chyme enters small intestine
        - Control rate of gastric emptying
- **What initiates protein digestion in the stomach?**
    - The stomach carries out the preliminary digestion of proteins by pepsin
    - As the stomach contents become more fluid and the pH approaches 2.0, pepsin activity increases and protein disassembly begins
        - Protein digestion is not completed in the stomach, because time is limited and pepsin attacks only certain peptide bonds
        - Breaks down complex proteins into smaller peptide and polypeptide chains before chyme enters the small intestine

The Small Intestine

- **What are the three regions? Know the location, function, and components of each**

    - Duodenum
        - Mixing bowl
        - Chyme and liver/pancreas secretions
    - Jejunum
        - Chemical digestion
        - Absorption of nutrients
    - Ileum
        - Shit gets passed to the large intestine
        - Ileocecal valve
- **Name and describe the three ways in which the intestinal wall has increased surface area**
    - Folds/Villi
        - Lacteal(lymph capillary) transports fats
    - **What are intestinal glands?**
        - They secrete juices
- **Name the two reflexes that result in intestinal movements.**
    - Gastroenteric reflux
        - Stomach stretching
        - Empty duodenum
    - Gastroileal reflux
        - Open ileocecal valve
        - Release shit
- **What secretions are made by the intestines and what is their function?**
    - Intestinal Juice
        - Moisture/buffers
- **Name and give the functions of the four intestinal hormones.**
    - Secretin
        - Encourages secretion of bile and buffer
    - Gastrin
        - Pushes things along
    - Cholecystokinin
        - Increase pancreatic enzyme production and gallbladder bile ejection
    - Gastric inhibitory peptide
        - Inhibits gastric activity
        - Causes release of insulin
- **What is the brush border?**
    - Shit ton of microvilli

The Pancreas

- **Where is this organ located?**
    - Posterior to stomach
- **Know the following tissues and their functions:**
    - Pancreatic Islets
        - Endocrine
        - Secrete insulin
    - Acinar cells

        - Exocrine
            - Secrete enzymes, buffers, juice
- **What are the four enzymes secreted by the pancreas? Know the function of each.**
    - Pancreatic Amylase: carbs
    - Pancreatic Lipase: fats
    - Pancreatic Nucleases: nucleic acids
    - Pancreatic Proteases: proteins
- **What is the role of CCK?**
    - Secreted when chyme arrives in the duodenum
    - Targets the pancreas and gallbladder
        - Pancreas: speeds up production and secretion of all types of digestive enzymes
        - Gallbladder: causes the ejection of bile into the duodenum
            - presence of either secretin or CCK in high concentrations also reduces gastric motility and the rates of secretions.

The Liver

- **Know the anatomy of the liver**
    - Left Lobe
    - Right Lobe
    - Caudate
    - Quadrate
- **What is a liver lobule and what is its primary function?**
    - A small part of the liver
- **How does the liver produce bile and what does it do?**
    - Hepatocytes (liver cells) produce bile
    - The liver cells secrete bile components into the bile canaliculi, small ducts that merge into larger bile ducts
    - contains bile salts for fat emulsification, bilirubin for waste elimination, and cholesterol, and aids in fat digestion, absorption, and neutralizing stomach acid in the small intestine
    - **Where does the bile go once it is produced?**
        - Gallbladder
    - **What is bile composed of?**
        - Water, ions, bilirubin, cholesterol, bile salts
- **How does the liver regulate metabolism?**
    - Nutrient extractions
    - Monitor nutrient levels
- **How does the liver regulate blood composition?**
    - Removed damaged cells/wastes
    - Make plasma proteins
    - Regulate clotting systems
    - ~~**What are Kupffer cells and what do they do?**~~
        - ~~Macrophages~~
        - ~~first innate immune cells and protect the liver from bacterial infections~~
    - **What role do hepatocytes have in this process?**
        -

The Gallbladder

- **Where is this organ?**
  - Located beneath the liver, on the right side of the abdomen
- **What is this organ's primary function?**
  - store and concentrate bile produced by the liver, releasing it into the small intestine when needed for fat digestion
  - **What hormone is involved in gallbladder contractions?**
    - CCK

The Large Intestine

- **Where is this organ located?**
  - Begins at ileum
  - Around small intestine
- **Give the functions of this organ**
  - Reabsorption (water, bile salts, vitamins)
  - Absorption of vitamins
  - Regulation of organic waste (bilirubin)
  - Breakdown of toxin
- **Know the anatomy of the large intestines. Know all the sub-divisions and their functions**
  - Cecum
    - Compaction begins
    - Attached to appendix
  - Colon
    - Lack villi
    - Abundance of mucous cells
    - Thinner than small intestine
    - Haustra: permit colon to expand and elongate
      - 3 separate longitudinal bands of smooth muscle (teniaecoli) run along the outer surface of the colon just beneath the serosa
      - Muscle tone within these bands creates the haustra
    - Divided into 3 sections
      - Ascending
      - Transverse
      - Descending
  - Rectum
    - Anal canal: last section
      - contains small longitudinal folds called anal columns
    - Anus: exit of the anal canal
      - Internal anal sphincter: involuntary
      - External anal sphincter: encircles the anus; voluntary
- **Why are the movements in the large intestine slow?**
  - To allow adequate time for the absorption of water, electrolytes, and nutrients
  - Helps to transform the liquid chyme into more solid feces by reabsorbing water
- **What are mass movements?**
  - Slow, powerful peristalsis

    - Occurs a few times a day typically after meals
    - propel fecal material over large distances toward the rectum, helping to move it closer to the point of defecation
        - help in the final stages of digestion
- **What is the defecation reflex? What two loops are involved?**
    - triggered by the distension of the rectum
    - Intrinsic and parasympathetic loop
        - Intrinsic loop: stretch of the rectum triggers local reflexes that cause the smooth muscles of the rectum to contract and the internal anal sphincter to relax
            - longer
        - Parasympathetic loop: Signals are sent to the brain, which sends parasympathetic signals back to the colon and rectum, further stimulating peristalsis and relaxation of the internal anal sphincter to facilitate defecation
            - shorter

Nutrient Processing

- **How are carbs broken down?**
    - Salivary and pancreatic amylase
- **How are carbs used by our body?**
    - Used in glycolysis and cellular respiration for the production of ATP
- **How are lipids broken down?**
    - Gastric and pancreatic lipase
- **How are proteins broken down?**
    - Pepsin and pancreatic enzymes (ie. trypsin and chymotrypsin)
    - Peptidases
- **How is water absorbed?**
    - Osmotic pressure in the small intestine
    - The rest of the water reabsorbed in the large intestine
- **How are vitamins absorbed (both fat soluble and water soluble)?**
    - Fat-soluble: Absorbed with dietary fats through the lymphatic system after emulsification by bile; transported in chylomicrons
    - Water-soluble: Absorbed directly into the bloodstream through specific transporters in the small intestine, without the need for fat or bile

Name 6 ways the GI tract changes as we age.

- Declining rate of cell division
    - More susceptible to tissue injury
- Smooth muscle tone decreases
    - Slowing peristalsis; leads to constipation
    - Hemorrhoids
    - Heart burnt
- Cumulative damage
    - Liver disease
    - Cavities
- Cancer
- Dehydration

    - Osmoreceptor sensitivity decreases
- Decrease of calcium ions leading to tooth loss
- Changes in sense of smell and taste