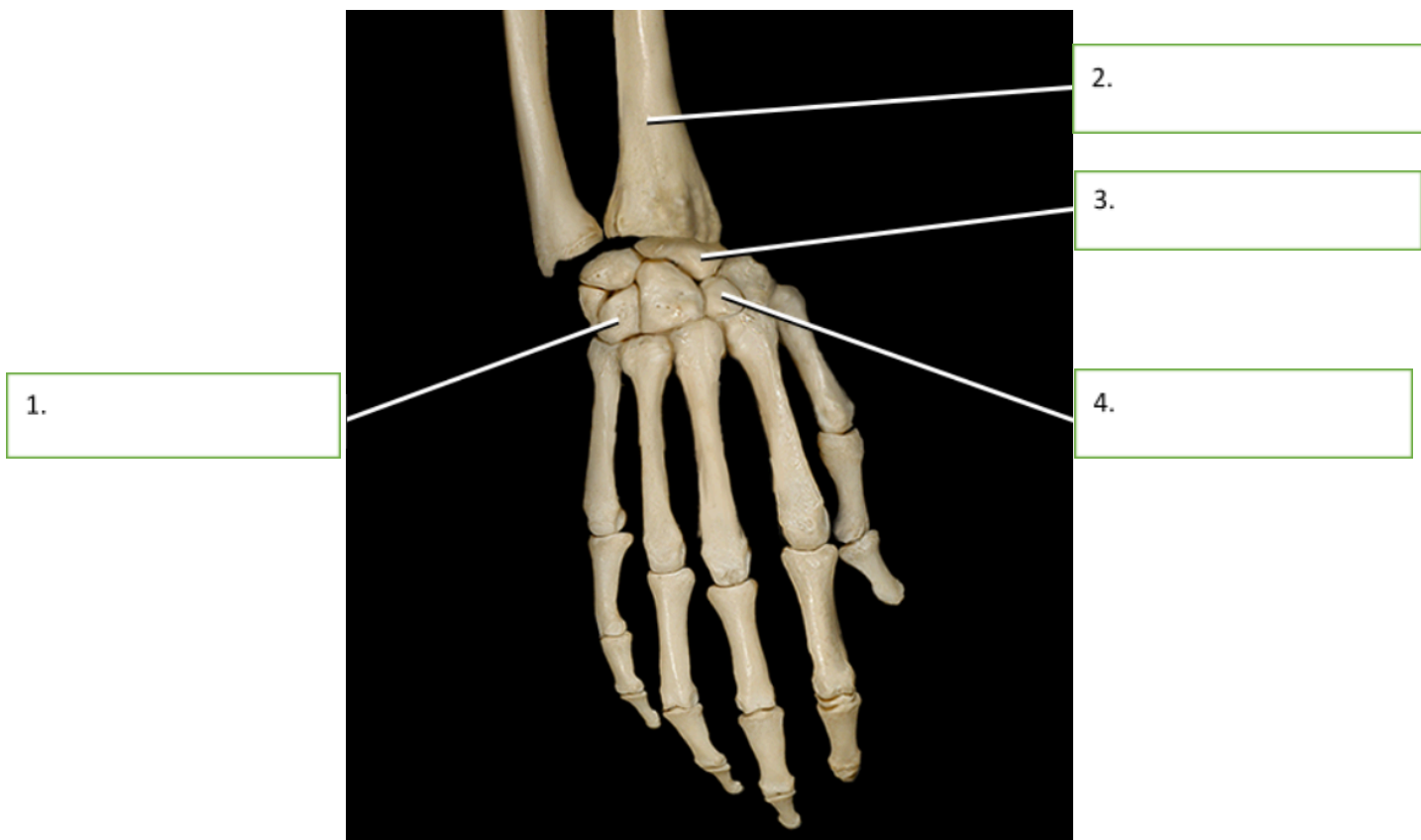


Bones of the Wrist Posterior (Dorsal) view

The Skeletal System

Identify the bones.



- Radius
- Hamate
- Scaphoid
- Trapezoid

Answer key:

