Internal Jugular & Brachiocephalic Veins

Origin, Course, Relations, Tributaries & Termination

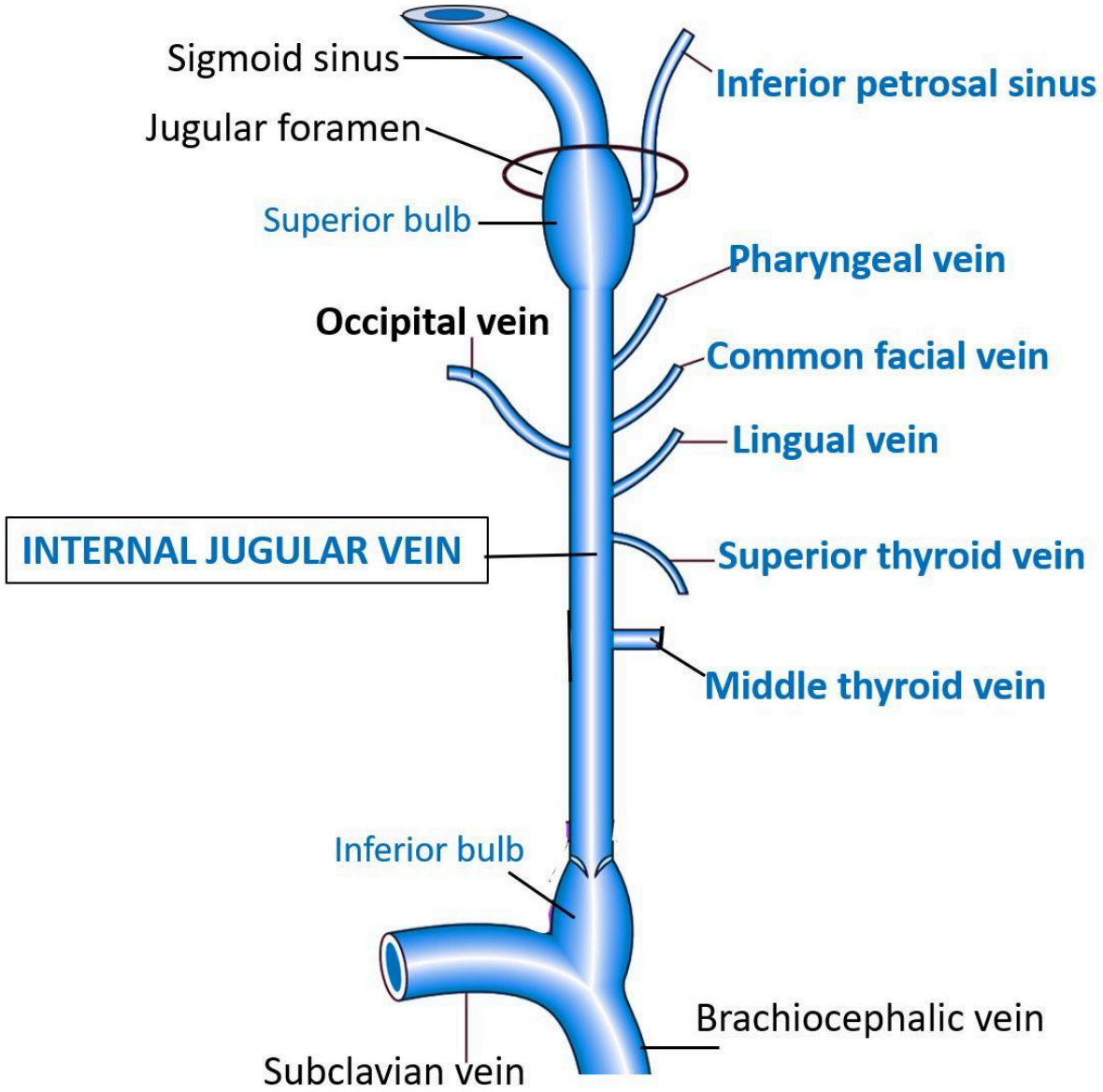

Brachiocephalic Veins & SVC

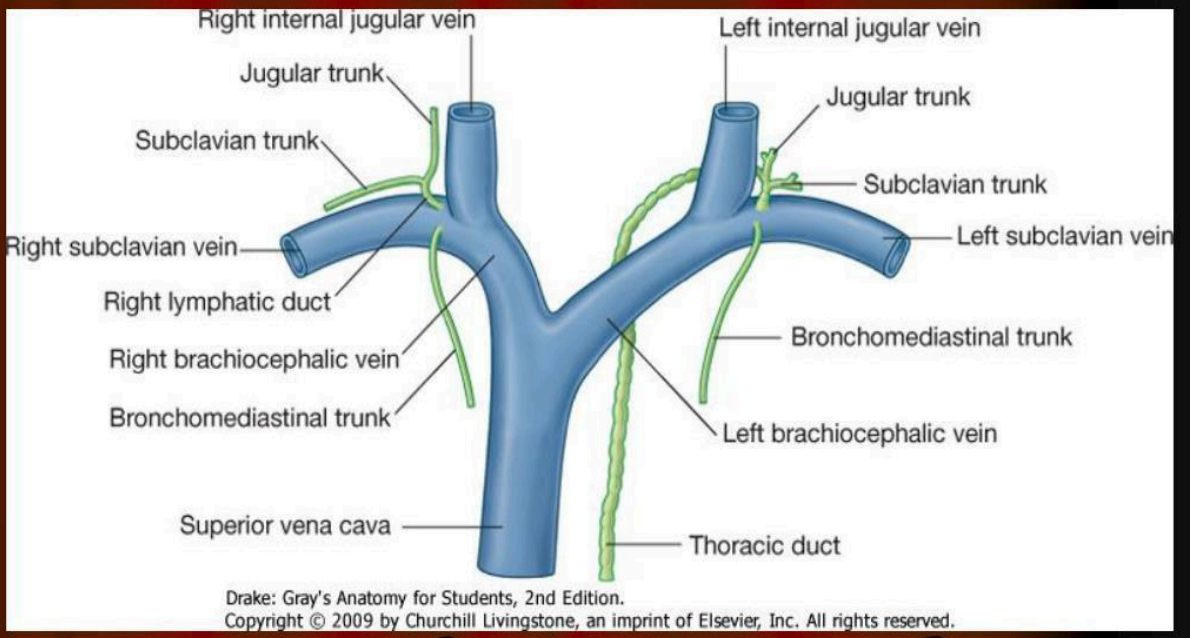

Drake: Gray's Anatomy for Students, 2nd Edition.
Copyright © 2009 by Churchill Livingstone, an imprint of Elsevier, Inc. All rights reserved.

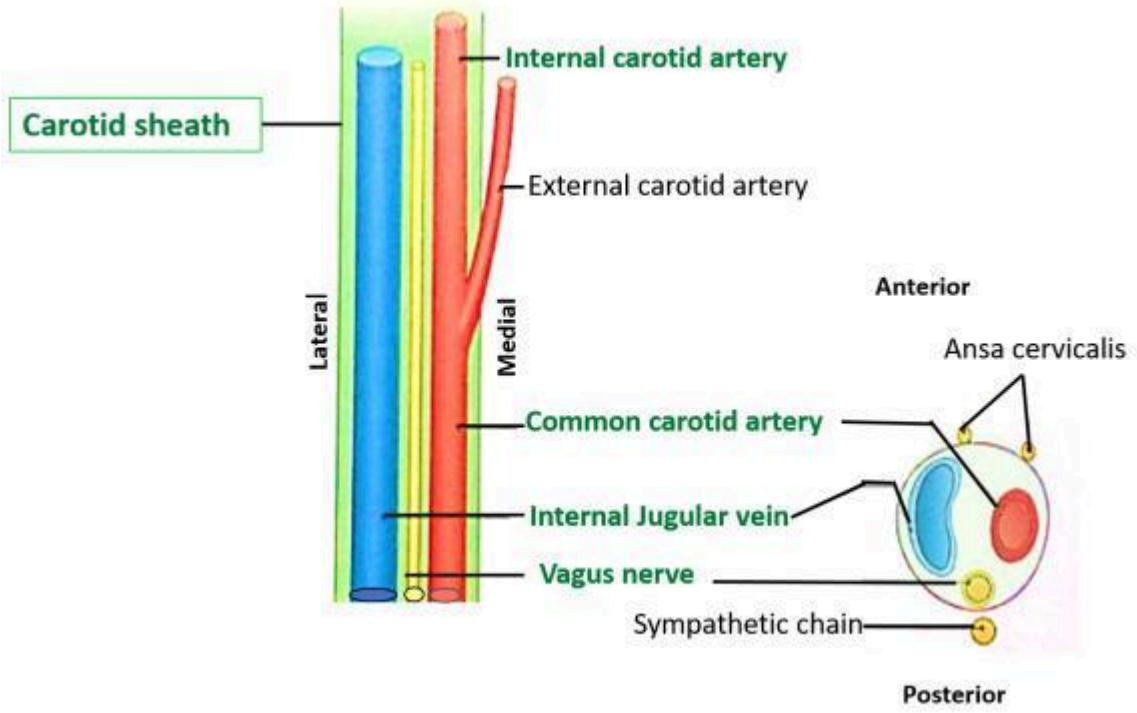

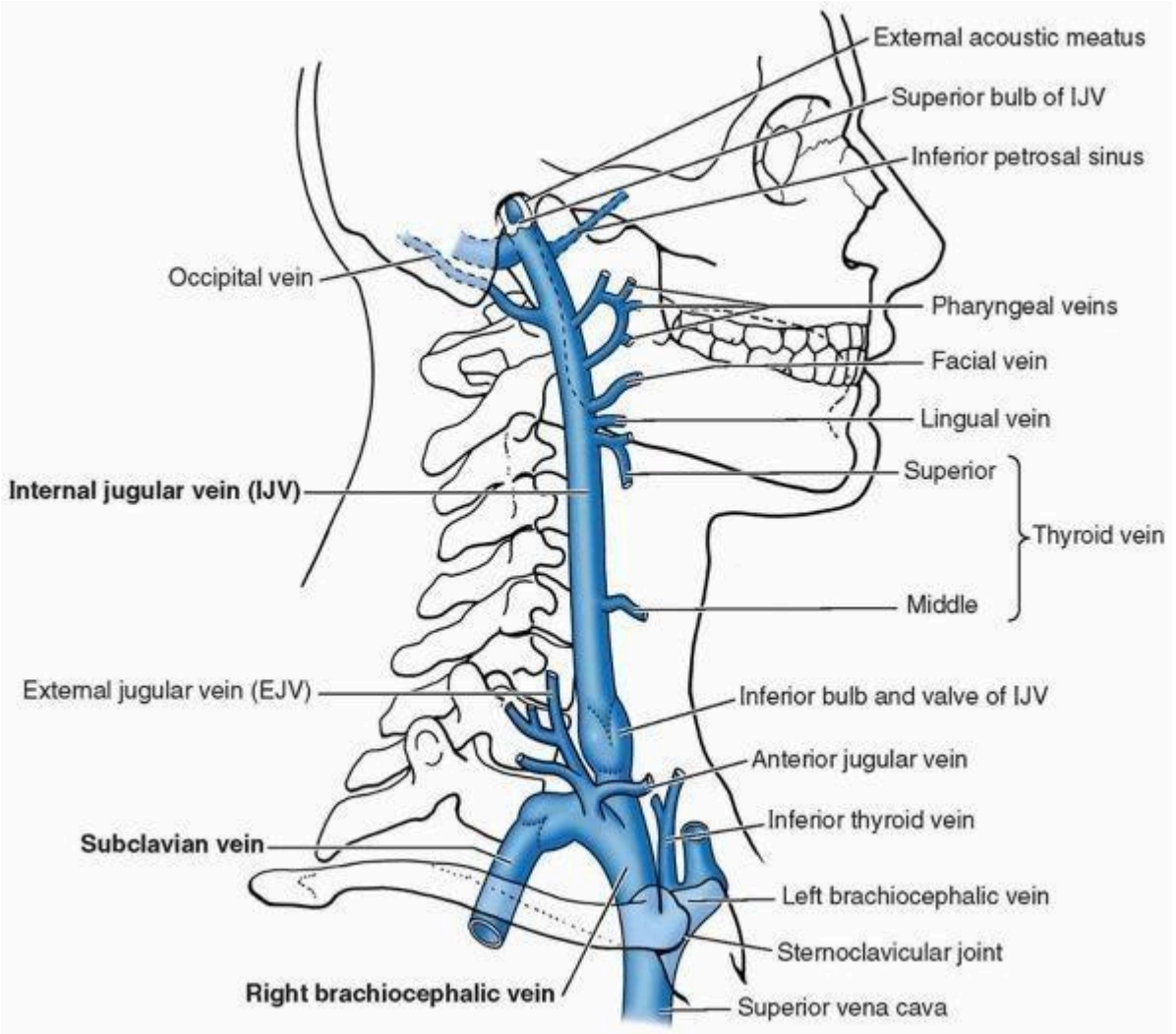
External acoustic meatus
Superior bulb of IJV
Inferior petrosal sinus
Occipital vein
Pharyngeal veins
Facial vein
Lingual vein
Internal jugular vein (IJV)
Superior
Thyroid vein
Middle
External jugular vein (EJV)
Inferior bulb and valve of IJV
Anterior jugular vein
Inferior thyroid vein
Subclavian vein
Left brachiocephalic vein
Sternoclavicular joint
Right brachiocephalic vein
Superior vena cava

Brachiocephalic veins

- Located immediately posterior to thymus
- Formed at the jn. of IJ & subclavian veins.
- Begins post to clavicle
- Tributaries: vertebral, first post. Intercostal, int. thoracic, inf. Thyroid, thymic veins

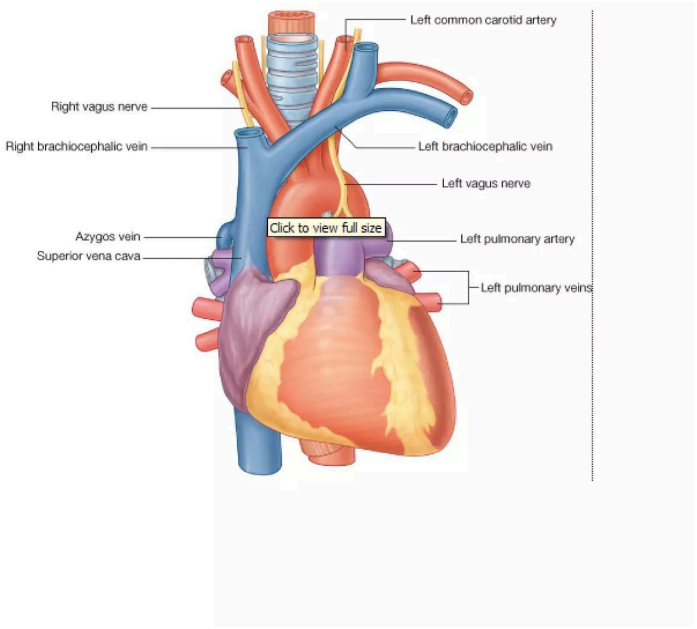

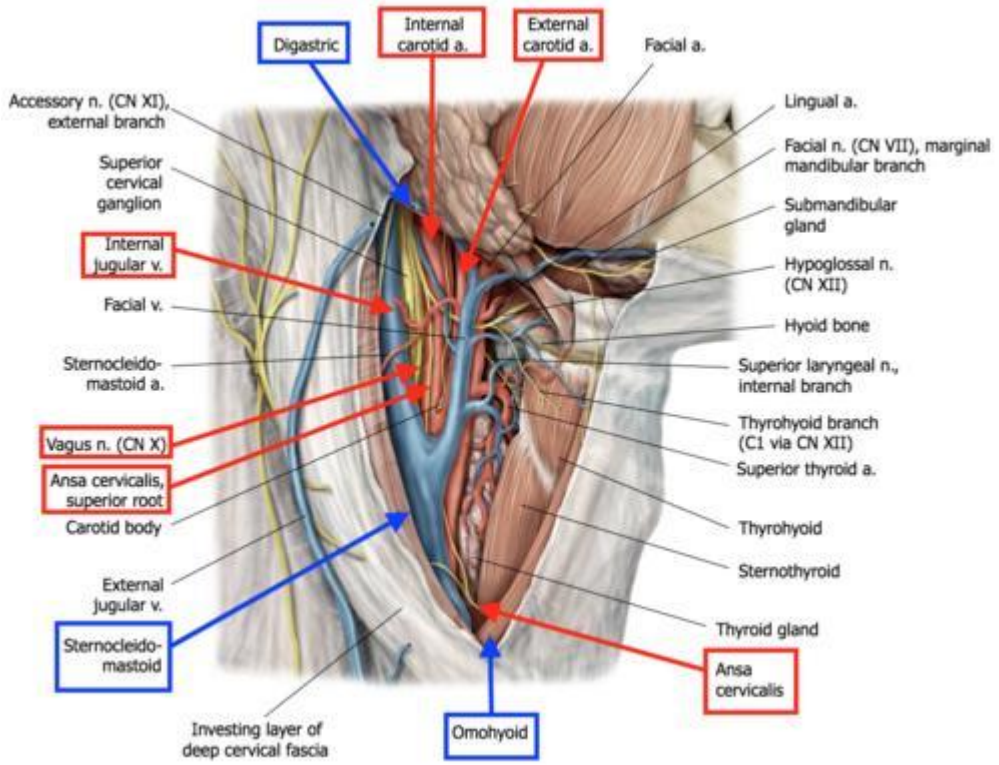

A. Internal Jugular Vein (IJV)

The **internal jugular vein** is the main venous channel draining the **brain, superficial face and deep structures of the neck**.

1. Origin

The IJV begins at the **jugular foramen** as a continuation of the **sigmoid sinus**.

At its origin it has a slight dilatation called the **superior bulb**.

It descends vertically through the neck and ends behind the **sternoclavicular joint**, where it joins the subclavian vein.

---

2. Course

Jugular foramen
↓
Descends in the **carotid sheath**
↓
Passes deep to SCM
↓
Descends toward root of neck
↓
Behind sternoclavicular joint
↓
Joins subclavian vein
↓
Brachiocephalic vein

At its termination it has an **inferior bulb**, usually provided with a valve.

---

3. Relations

Upper part

The IJV is related to:

- Internal carotid artery
- Cranial nerves in the upper neck
- Posterior belly of digastric
- Stylohyoid

Middle and lower parts

The IJV lies within the **carotid sheath**.

Important relationship

Within the carotid sheath:

Carotid artery → medial
Internal jugular vein → lateral
Vagus nerve → posterior, between artery and vein

Anterior relation

- Sternocleidomastoid
- Investing layer of deep cervical fascia

The vein is largely **deep to SCM**.

Posterior relations

- Cervical sympathetic trunk
- Prevertebral muscles
- Transverse processes of cervical vertebrae

---

4. Tributaries

The important tributaries are:

Intracranial

- Inferior petrosal sinus
- Sigmoid sinus

Extracranial

- Common facial vein
- Lingual vein
- Pharyngeal veins
- Superior thyroid vein
- Middle thyroid vein
- Occasionally occipital vein

The IJV therefore drains:

- Brain
- Face
- Tongue
- Pharynx
- Thyroid
- Deep neck structures.

---

5. Termination

The IJV joins the **subclavian vein** behind the sternoclavicular joint.

IJV + Subclavian vein → Brachiocephalic vein

B. Brachiocephalic Veins

There are **right and left brachiocephalic veins**.

They are formed by the union of:

Internal jugular vein + subclavian vein

behind the respective sternoclavicular joints.

---

1. Right brachiocephalic vein

Course

- Shorter and more vertical.
- Descends behind the right first costal cartilage.
- Passes toward the right side of the superior mediastinum.

Tributaries

Receives:

- Inferior thyroid veins
- Vertebral vein
- First posterior intercostal vein

- Internal thoracic vein
- Occasionally thymic and pericardial veins.

---

2. Left brachiocephalic vein

Course

- Longer than the right.
- Runs **obliquely from left to right**.
- Passes behind the upper part of the manubrium.
- Crosses the midline.
- Joins the right brachiocephalic vein.

Important relations

Anterior:

- Manubrium and its attachments

Posterior:

- Branches of the aortic arch
- Trachea
- Large arteries arising from the arch

It is therefore an important vessel in the **superior mediastinum**.

Tributaries

Similar to the right:

- Inferior thyroid veins
- Vertebral vein
- Internal thoracic vein
- First posterior intercostal vein
- Thymic/pericardial veins.

It may also receive the **left superior intercostal vein**.

---

3. Termination

The right and left brachiocephalic veins unite:

Behind the lower border of the right 1st costal cartilage

to form the:

Superior vena cava

The SVC then drains into the **right atrium**.

Important Relations — Practical Table

Vein	Important relation
Internal jugular	Within carotid sheath
IJV	**Lateral to carotid artery**
IJV	Vagus nerve lies between artery & vein
IJV	Deep to sternocleidomastoid
Right brachiocephalic	Short, nearly vertical
Left brachiocephalic	Long, oblique, behind manubrium
Brachiocephalic veins	Unite to form SVC

Practical Demonstration

Internal jugular vein

On a cadaver:

1. Identify the **jugular foramen**.
2. Trace the sigmoid sinus into the **internal jugular vein**.
3. Follow it inferiorly in the carotid sheath.
4. Identify **SCM** superficial to the vein.
5. Demonstrate:
    - Carotid artery medially
    - IJV laterally
    - Vagus nerve between them
6. Trace the IJV to the **sternoclavicular joint**.

7. Demonstrate its union with the subclavian vein.

Brachiocephalic veins

1. Identify the right and left IJV.
2. Identify the corresponding subclavian veins.
3. Demonstrate their union behind each sternoclavicular joint.
4. Trace:

Right + left brachiocephalic veins → SVC → right atrium

5. Note that the **left brachiocephalic vein crosses obliquely behind the manubrium**.

Clinical Anatomy

1. Internal jugular venous access

The IJV is commonly used for **central venous catheterization** because of its relatively predictable course.

2. JVP

The **jugular venous pulse** provides information about right atrial pressure and central venous haemodynamics.

3. Internal jugular thrombosis

Thrombosis may occur due to:

- Central venous catheters
- Malignancy
- Infection
- Hypercoagulable states

4. Venous air embolism

Because the veins of the neck can be exposed to atmospheric pressure during procedures, inadvertent entry of air can cause a **venous air embolism**.

⭐ Flow to remember

Sigmoid sinus
↓
Internal jugular vein
↓ + **Subclavian vein**
↓
Brachiocephalic vein
↓
Right + Left brachiocephalic veins
↓
Superior vena cava
↓
Right atrium

One-line practical answer

> **The IJV begins at the jugular foramen, descends in the carotid sheath lateral to the carotid artery, receives major cranial and cervical tributaries, and joins the subclavian vein behind the sternoclavicular joint to form the brachiocephalic vein; the two brachiocephalic veins unite to form the superior vena cava.**