OPTIC CHIASM

In neuroanatomy, the optic chiasm, or optic chiasma (/ɒptɪk kaɪæzəm/; from Greek χίασμα 'crossing', from Ancient Greek χιάζω 'to mark with an X'), is the part of the brain where the optic nerves cross. It is located at the bottom of the brain immediately inferior to the hypothalamus. The optic chiasm is found in all vertebrates, although in cyclostomes (lampreys and hagfishes), it is located within the brain.

Optic chiasm

IMAGE - 1

Brain viewed from below; the front of the brain is above. Visual pathway with optic chiasm (X shape) is shown in red (image from Andreas Vesalius' Fabrica, 1543).

IMAGE - 2

Optic nerves, chiasm, and optic tracts

DETAILS

System *:- Visual system*

Function :- *Transmit visual information from the optic nerves to the occipital lobes of the brain*

Identifiers

Latin *:- chiasma opticum*

This article is about the optic chiasm of vertebrates, which is the best known nerve chiasm, but not every chiasm denotes a crossing of the body midline (e.g., in some invertebrates, see Chiasm (anatomy)). A midline crossing of nerves inside the brain is called a decussation (see Definition of types of crossings).

STRUCTURE

IMAGE :- 3

Transformations of the visual field toward the visual map on the primary visual cortex in vertebrates. U=up; D=down; L=left; R=right; F=fovea

In all vertebrates, the optic nerves of the left and the right eye meet in the body midline, ventral to the brain. In many vertebrates the left optic nerve crosses over the right one without fusing with it.

In vertebrates with a large overlap of the visual fields of the two eyes, i.e., most mammals and birds, but also amphibians, reptiles such as chameleons, the two optic nerves merge in the optic chiasm. In such a merged optic chiasm, part of the nerve fibres do not cross the midline, but continue towards the optic tract of the ipsilateral side. By this partial decussation, the part of the visual field that is covered by both eyes is fused so that the processing of binocular depth perception by stereopsis is enabled (see Image - 3).

In the case of such partial decussation, the optic nerve fibres on the medial sides of each retina (which correspond to the lateral side of each visual hemifield, because the image is inverted) cross over to the opposite side of the body midline. The inferonasal retina are related to the anterior portion of the optic chiasm whereas superonasal retinal fibers are related to the posterior portion of the optic chiasm.

The partial crossing over of optic nerve fibres at the optic chiasm allows the visual cortex to receive the same hemispheric visual field from both eyes. Superimposing and processing these monocular visual signals allow the visual cortex to generate binocular and stereoscopic vision. The net result is that the right cerebral hemisphere processes left visual hemifield, and the left cerebral hemisphere processes the right visual hemifield.

Beyond the optic chiasm, with crossed and uncrossed fibers, the optic nerves are called optic tracts. The optic tract inserts on the optic tectum (in mammals known as superior colliculus) of the midbrain. In mammals they also branch off to the lateral geniculate body of the thalamus, in turn giving them to the occipital cortex of the cerebrum.

DEVELOPMENT IN MAMMALS

During development, the crossing of the optic nerves is guided primarily by cues such as netrin, slit, semaphorin and ephrin; and by morphogens such as sonic hedgehog (Shh) and Wnt.[6] This navigation is mediated by the neuronal growth cone, a structure that responds to the cues by ligand-receptor signalling systems that activate downstream pathways inducing changes in the cytoskeleton.Retinal ganglion cell (RGC) axons leaving the eye through the optic nerve are blocked from exiting the developing pathway by Slit2 and Sema5A inhibition, expressed bordering the optic nerve pathway. Ssh expressed at the central nervous system midline inhibits crossing prior to the chiasm, where it is downregulated. The organization of RGC axons changes from retinotopic to a flat sheet-like orientation as they approach the chiasm site. Most RGC axons cross the midline at the ventral diencephalon and continue to the contralateral superior colliculus. The number of axons that do not cross the midline and project ipsilaterally depends on the degree of binocular vision of the animal (3% in mice and 45% in humans do not cross).[8] Ephrin-B2 is expressed at the chiasm midline by radial glia and acts as a repulsive signal to axons originating from the ventrotemporal retina expressing EphB1 receptor protein, giving rise to the ipsilateral, or uncrossed, projection.[8] RGC axons that do cross at the optic chiasm are guided by the vascular endothelial growth factor, VEGF-A, expressed at the midline, which signals through the receptor Neuropilin-1 (NRP1) expressed on RGC axons.Chiasm crossing is also promoted by Nr-CAM (Ng-CAM-related cell adhesion molecule) and Semaphorin6D (Sema6D) expressed at the midline, which form a complex that signals to Nr-CAM/Plexin-A1 receptors on crossing RGC axons.

OTHER ANIMALS

Mammals

Since all vertebrates, even the earliest fossils and modern jawless ones,possess an optic chiasm, it is not known how it evolved.A number of theories have been proposed for the function of the optic chiasm in vertebrates (see theories). According to the Axial Twist theory the optic chiasm develops as a consequence of a twist in the early embryo.

In Siamese cats with certain genotypes of the albino gene, the wiring is disrupted, with more of the nerve-crossing than normal. Since siamese cats, like albino tigers, also tend to cross their eyes (strabismus), it has been proposed that this behavior might compensate the abnormal amount of decussation.

CEPHALOPODS AND INSECTS

In cephalopods and insects the optic tracts do not cross the body midline, so each side of the brain processes the ipsilateral eye.

HISTORY

The crossing of nerve fibres, and the impact on vision that this had, was probably first identified by Persian physician "Esmail Jorjani", who appears to be Zayn al-Din Gorgani (1042–1137).

IMAGE - 4
Scheme showing central connections of the optic nerves and optic tracts.

IMAGE - 5
Brain seen from below, with the optic chiasm seen in yellow in the centre.

IMAGE - 6
Transformations of the visual field toward the visual map on the primary visual cortex.

IMAGE - 7
Brain and brainstem seen from below

IMAGE - 8
Left hemisphere of the brain seen in a cadaveric specimen from the side, with the optic chiasm labelled.

IMAGE - 9
Cerebrum, inferior view, deep dissection.

IMAGE - 10
Guidance of axon crossing and non-crossing during development.

Chiasm (anatomy)

Not to be confused with Decussation, Commissure, or Ganglion.

In anatomy a chiasm is the spot where two structures cross, forming an X-shape (from Greek letter χ, Chi). Examples of chiasms are:

- *A tendinous chiasm, the spot where two tendons cross. For example, the tendon of the flexor digitorum superficialis muscle, and the tendon of the flexor digitorum longus muscle which even forms two chiasms.*
- *In neuroanatomy, the crossing of fibres of a nerve or the crossing of two nerves.*

Chiasm

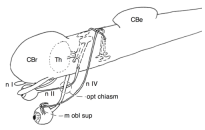

IMAGE - 1

Schema of the optic chiasm and the trochlear chiasm in vertebrates.

DETAILS

Function *:- Anatomical feature where two structures cross*

Identifiers

Latin *:- chiasma*

Neural chiasms

Different types of crossings of nerves are referred to as chiasm:

- *Type I: Two nerves can cross one over the other (sagittal plane) without fusing, e.g., the trochlear nerve (see IMAGE).*
- *Type II: Two nerves can merge while at least part of the fibres cross the midline (see IMAGE 2).*
- *Type III: The fibres within a single nerve cross, such that the order of the functional map is reversed, e.g., the optic chiasms of various invertebrates such as insects and cephalopods.*
- *Type IV: A torsion or loop by 180 degrees of a nerve can also reverse the order of the functional map. This type is usually not referred to as chiasm.*

Note that in the third type there is no crossing of the mid sagittal plane. Only in the first type, the crossing is complete.

There are other kinds of crossings of nerve fibres. The chiasm is distinguished from a decussation, which is a crossing of nerve fibres inside the central nervous system. A chiasm also differs from a ganglion in that axons run through it without making any synapses. A chiasm is thus not a nervous processing centre.

Optic chiasm in vertebrates

By far the most widely known chiasm is the optic chiasm in vertebrate animals, including humans.

EXAMPLES

Chiasms are found in vertebrates but also in invertebrates. The optic chiasm in vertebrates can be of type I or II.However, an optic chiasm of type III is found in many insects and in cephalopods.

In vertebrates, three of the cranial nerves show a chiasm.

- *The optic chiasm of the optic tract (type I or II)*
- *The chiasm of the Trochlear nerve (type I)*

- *The decussation of part of the Oculomotor nerve (type I)*

The optic chiasm of vertebrates involves the optic tract. The trochlear nerve is a motor nerve that innervates one of the muscles that move the contralateral eye (i.e., the superior oblique muscle). It emerges from the dorsal aspect of the ventral midbrain, leaves the brain on the dorsal side where it crosses to the opposite side. The oculomotor nerve originates from the third nerve nucleus at the level of the superior colliculus (in non-mammalian vertebrates this is the optic tectum) in the midbrain. The rostral part of the nerve crosses the midline to merge with the part of the contralateral nerve that does not cross. Since the midline crossing occurs inside the brain, it is not strictly a chiasm but rather a decussation.

STRUCTURE

As stated above, very different kinds of nerve crossings are known as chiasm. The optic chiasm of vertebrates is the best known. The optic nerve runs from the retina towards the ventral midline of the brain and crosses to the opposite side to continue as the optic tract which inserts to the optic tectum (=superior colliculus) on the dorsal midbrain (as well as branching off to the thalamus in amniotes).

Type I: Passing in the sagittal plane

In many vertebrates, the left-eye optic nerve crosses over the right-eye one, without blending.

Type II: Fusion in the sagittal plane



IMAGE 2

Example of bifurcating axons in the optic chiasm (Type II) of a rabbit. a,b,c: bifurcating optic fibres. c: fibre bifurcating in the two opposite optic tracts. d. Commisure of Gudden. e. Fibres that continue in a different depth.

In mammals and birds and other vertebrates with frontal eyes, the optic nerves do blend in the optic chiasm, and only part of the nerve fibres cross the midline.The drawings of Cajal suggest that the axons of the optic nerve may branch in the optic chiasm, and thus give off a branch both in the ipsi- and contralateral optic tract. Note, however, that such branching is not neural processing as occurs in a ganglion.

Type III: Systematic crossing of fibres inside a nerve

The optic tract of various clades of insects shows two chiasms, the first and second optic chiasm. In contrast to those in vertebrates, the insect chiasms do not cross the body midline. Rather, the first and second chiasm invert the anterior and posterior visual field. Since there are two chiasms, the retinotopic map is not affected.

Cephalopods (squids and octopuses) possess highly developed lens eyes. The optic tract of cephalopods, such as the squid Loligo,chiasmates without midline crossing. This chiasm is distributed along the optic tract and effectively compensates the inversion of the image on the retina.

Type IV: Torsion or looping of a nerve

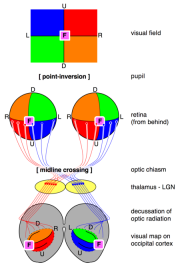

IMAGE 3

The decussation of the optic radiation in the cortex is an example of a type IV crossing

This type is usually not called chiasm. Such a looping occurs, for example, in the optic tract between the optic chiasm and the optic tectum.Another example is the optic radiation which rotates the retinal map on the visual cortex by 180° (see IMAGE 3).

THEORIES AND EVOLUTION

Vertebrates

A number of theories have been proposed to explain the existence of the optic chiasm in vertebrates. The first is these theories was the Visual map theory by Ramón y Cajal. The axial twist hypothesis also explains the chiasm of the trochlear nerve.The hypothesis of Cajal might be valid for the optic chiasm of cephalopods, although in a different manner, because Cajal designed his idea for a chiasm of type II but the cephalopod chiasm is of type III.

INVERTEBRATES

The lens eye inverts the visual image that is projected on the retina due to the camera obscura effect. The chiasm in the optic tract of cephalopods corrects this inversion.
In insects, the optic chiasms seem to have evolved gradually, since primitive groups have no chiasm, whereas later evolved groups have one or two optic chiasms along the optic lobe.

EXCEPTIONS

In jawless vertebrates (hagfish and lamprey), the optic tracts do cross in the midline, but only after entering the ventral side of the central nervous system.[After crossing the tracts insert on the dorsal optic tectum as in all other vertebrates. Therefore, given the obvious and undisputed homology, the optic chiasm is called chiasm also in these clades, even though the crossing is technically a decussation.

Decussation

Not to be confused with Desiccation, Chiasm (anatomy), or Commissure.
Decussation is used in biological contexts to describe a crossing (due to the shape of the Roman numeral for ten, an uppercase 'X' (decussis), from Latin decem 'ten', and as 'as'). In Latin anatomical terms, the form decussatio is used, e.g. decussatio pyramidum.

IMAGE - 1
Section of the medulla oblongata at the level of the decussation of the pyramids
Similarly, the anatomical term chiasma is named after the Greek uppercase 'X' (chi). Whereas a decussation refers to a crossing within the central nervous system, various kinds of crossings in the peripheral nervous system are called chiasma.
Examples include:

- *In the brain, where nerve fibers obliquely cross from one lateral side of the brain to the other, that is to say they cross at a level other than their origin. See for examples decussation of pyramids and sensory decussation. In neuroanatomy, the term chiasma is reserved for crossing of- or within nerves such as in the optic chiasm.*
- *In botanical leaf taxology, the word decussate describes an opposite pattern of leaves which has successive pairs at right angles to each other (i.e. rotated 90 degrees along the stem when viewed from above). In effect, successive pairs of leaves cross each other. Basil is a classic example of a decussate leaf pattern.*

IMAGE - 2
Decussate phyllotaxis of Crassula rupestris

- *In tooth enamel, where bundles of rods cross each other as they travel from the enamel-dentine junction to the outer enamel surface, or near to it.*

IMAGE - 3
In this "true bug", Dysdercus decussatus, in the family Pyrrhocoridae, the specific epithet refers to the bandolier-like markings on the back.

- *In taxonomic description where decussate markings or structures occur, names such as decussatus or decussata or otherwise in part containing "decuss..." are common, especially in the specific epithet.*

EVOLUTIONARY SIGNIFICANCE
The origin of the contralateral organization, the optic chiasm and the major decussations on the nervous system of vertebrates has been a long standing puzzle to scientists. The visual map theory of Ramón y Cajal has long been popular but has been criticized for its logical inconsistence. More recently, it has been proposed that the decussations are caused by an axial twist by which the anterior head, along with the forebrain, is turned by 180° with respect to the rest of the body.

CHIASMAL SYNDROME

Chiasmal syndrome is the set of signs and symptoms that are associated with lesions of the optic chiasm, manifesting as various impairments of the affected's visual field according to the location of the lesion along the optic nerve. Pituitary adenomas are the most common cause; however, chiasmal syndrome may be caused by cancer, or associated with other medical conditions such as multiple sclerosis and neurofibromatosis.

OPTIC CHIASM

IMAGE - 1

Visual pathway with optic chiasm (X shape outlined, red) (1543 image from Andreas Vesalius' Fabrica)

DETAILS

Identifiers

Latin :- *chiasma opticum*

CAUSE

Foroozen divides the causes of chiasmal syndromes into intrinsic and extrinsic causes. Intrinsic implies thickening of the chiasm itself and extrinsic implies compression by another structure. Other less common causes of chiasmal syndrome are metabolic, toxic, traumatic or infectious in nature.

Intrinsic etiologies include gliomas and multiple sclerosis. Gliomas of the optic chiasm are usually derived from astrocytes. These tumors are slow growing and more often found children.However, they have a worse prognosis, especially if they have extended into the hypothalamus. They are frequently associated with neurofibromatosis type 1 (NF-1). Their treatment involves the resection of the optic nerve. The supposed artifactual nature of Wilbrand's knee has implications for the degree of resection that can be obtained, namely by cutting the optic nerve immediately at the junction with the chiasm without fear of potentially resulting visual field deficits.

The vast majority of chiasmal syndromes are compressive. Ruben et al.[4] describe several compressive etiologies, which are important to understand if they are to be successfully managed. The usual suspects are pituitary adenomas, craniopharyngiomas, and meningiomas.

Pituitary tumors are the most common cause of chiasmal syndromes. Visual field defects may be one of the first signs of non-functional pituitary tumor. These are much less frequent than functional adenomas. Systemic hormonal aberrations such as Cushing's syndrome, galactorrhea and acromegaly usually predate the compressive signs. Pituitary tumors often encroach upon the middle chiasm from below. Pituitary apoplexy is one of the few acute chiasmal syndromes. It can lead to sudden visual loss as the hemorrhagic adenoma rapidly enlarges.

The embryonic remnants of Rathke's pouch may undergo neoplastic change called a craniopharyngioma. These tumors may develop at any time but two age groups are most at risk. One peak occurs during the first twenty years of life and the other occurs between fifty and seventy years of age. Craniopharyngiomas generally approach the optic chiasm from behind and above. Extension of craniopharyngiomas into the third ventricle may cause hydrocephalus.

Meningiomas can develop from the arachnoid layer. Tuberculum sellae and sphenoid planum meningiomas usually compress the optic chiasm from below. If the meningioma arises from the diaphragma sellae the posterior chiasm is damaged. Medial sphenoid ridge types can push on the chiasm

from the side. Olfactory groove subfrontal types can reach the chiasm from above. Meningiomas are also associated with neurofibromatosis type 1. Women are more prone to develop meningiomas.

ANATOMY

The optic chiasm is formed by the union of the two optic nerves. The nasal fibers of each optic nerve decussate (cross) across the chiasm to the contralateral side while the temporal fibers course posteriorly to form the optic tract on the ipsilateral side. This arrangement allows the left half of the visual field to end up on the right side of the brain and the right half of the visual field to locate to the left side.

The optic nerves consist of the axons from the retinal ganglion of each eye. At the chiasm, 53% of the axons from the nasal retina cross the midline to join the uncrossed temporal fibers. These nasal fibers carry information from the temporal visual field. Similarly, the temporal fibers transmit images from the nasal field. The two optic tracts, representing the right and left visual fields, emerge posteriorly from the posterior chiasm. Most of these fibers synapse in the lateral geniculate nucleus or the pretectal nucleus.

The crossing of the nasal half of macular fibers of central vision occurs posteriorly in the chiasm. The inferior and superior fibers remain inferior or superior, respectively. However, the inferonasal fibers pass more anteriorly in the chiasm while the superonasal fibers pass more posteriorly. Classical teaching was that, once crossed, the inferonasal fibers briefly loop back into the contralateral optic nerve sheath, before returning to the chiasm. This bend into the contralateral optic nerve had been called Wilbrand's knee. However, today there is significant evidence that Wilbrand's knee is simply an artifact (error). Optic nerve axons from one eye can only be selectively studied in the human after enucleation of the contralateral eye and thus degeneration of the axons on one side. After several years, the occurring optic nerve atrophy results in artifactual looping of the axons into the atrophic nerve. This looping was initially described by Wilbrand, who studied subjects with severe optic nerve atrophy after enucleation, and who then appears to have exaggerated the importance of this looping in later drawings.Clinically, no optic field deficits have been observed in a small series of optic nerve sections at the optic nerve-chiasm junction.

Several important structures are located adjacent to the optic chiasm. The supraclinoid branches of the internal carotid artery flank the chiasm. The cavernous sinuses are lateral and inferior to the chiasm. The frontal lobe of the brain lies above. The pituitary gland sits below in the sella turcica. The sella turcica is bound in front by the tuberculum sellae and behind by the dorsum sellae. Behind the chiasm lies the floor of the third ventricle.

PATHOPHYSIOLOGY

Andrew G. Lee has divided optic chiasmal syndromes into anterior, middle and posterior locations. Anterior chiasmal syndrome affects the junction of the optic nerve and chiasm. Middle chiasmal syndrome relates to the decussating fibers in the body of the optic chiasm while posterior chiasmal syndrome involves the caudal fibers.

The classic anterior chiasmal lesion affects the optic nerve fibers and the contralateral inferonasal fibers located in Wilbrand's knee. This will produce an ipsilateral optic neuropathy, often manifested as a central scotoma, and a defect involving the contralateral superotemporal field. This is also known as a junctional scotoma. An alternative explanation for the contralateral field deficit has been provided by Horton.

Middle lesions affecting the uncrossed temporal fibers are rare. These can result in a nasal or binasal hemianopia. Lesions in the body of the chiasm most commonly disrupt the crossing nasal retinal fibers.

This leads to a bitemporal hemianopia. The field of vision may still be full when both eyes are open but stereovision will not be possible. However, if fusion of the images is lost, perhaps due to a preexisting phoria, binocular diplopia may result.
Because macular fibers cross more posteriorly in the chiasm, they are damaged in posterior chiasmal syndrome. This leads to a smaller, paracentral bitemporal field loss. Because the temporal macular fibers have not been damaged, it is possible to preserve color vision and visual acuity. Posterior lesions may also involve the optic tract and cause a contralateral homonymous hemianopia.
Optic disc pallor may be apparent with an ophthalmoscope if the result is longstanding. If the lesion does not affect the lateral uncrossed fibers, the pallor may take on a bow-tie configuration. This is due to loss of retinal ganglion cells nasal to the macula in the papillomacular bundle. Compressive lesions often cause headache and may compress the third ventricle leading to hydrocephalus. The most common tumors also cause pituitary gland malfunction.

MANAGEMENT
Visual fields associated with chiasmal syndrome usually leads to an MRI. Contrast can delineate arterial aneurysms and will enhance most intrinsic chiasmal lesions.If a mass is confirmed on MRI, an endocrine panel can help determine if a pituitary adenoma is involved.
In patients with functional adenomas diagnosed by other means, visual field tests are a good screen to test for chiasmal involvement. Visual fields tests will delineate chiasmal syndromes because the missing fields will not cross the midline. Junctional scotomas classically show ipsilateral optic disc neuropathy with contralateral superotemporal defects. Bitemporal hemianopia with or without central scotoma is present if the lesions have affected the body of the chiasm. A posterior chiasm lesion should only produce defects on the temporal sides of the central visual field.

CHIASMA (GENETICS)

In genetics, a chiasma (pl.: chiasmata) is the point of contact, the physical link, between two (non-sister) chromatids belonging to homologous chromosomes. At a given chiasma, an exchange of genetic material can occur between both chromatids, what is called a chromosomal crossover, but this is much more frequent during meiosis than mitosis. In meiosis, absence of a chiasma generally results in improper chromosomal segregation and aneuploidy.

[1]IMAGE 1

Crossing over during meiosis, with chiasma shown.

Points of crossing over become visible as chiasma after the synaptonemal complex dissembles and the homologous chromosomes slightly apart from each other.

The phenomenon of genetic chiasmata (chiasmatypie) was discovered and described in 1909 by Frans Alfons Janssens, a Professor at the University of Leuven in Belgium.

When each tetrad, which is composed of two pairs of sister chromatids, begins to split, the only points of contact are at the chiasmata. The chiasmata become visible during the diplotene stage of prophase I of meiosis, but the actual "crossing-overs" of genetic material are thought to occur during the previous pachytene stage. Sister chromatids also form chiasmata between each other (also known as a chi structure), but because their genetic material is identical, it does not cause any noticeable change in the resulting daughter cells.

In humans, there seems to be one chiasma per chromosome arm,and in mammals, the number of chromosome arms is a good predictor of the number of crossovers.Yet, in humans and possibly other species, evidence shows that the number of crossovers is regulated at the level of an entire chromosome and not an arm.

The grasshopper Melanoplus femurrubrum was exposed to an acute dose of X-rays during each individual stage of meiosis, and chiasma frequency was measured. Irradiation during the leptotene-zygotene stages of meiosis, that is, prior to the pachytene period in which crossover recombination occurs, was found to increase subsequent chiasma frequency. Similarly, in the grasshopper Chorthippus brunneus, exposure to X-irradiation during the zygotene-early pachytene stages caused a significant increase in mean cell chiasma frequency. Chiasma frequency was scored at the later diplotene-diakinesis stages of meiosis. These results suggest that X-rays induce DNA damages, likely including double-strand breaks, and these damages are repaired by a crossover pathway leading to chiasma formation.

1