Anatomical Basis of Clinical Conditions Affecting the Midbrain

The clinical syndromes of the midbrain are produced by lesions involving specific **cranial-nerve nuclei/fascicles, long tracts, and tectal structures**. The three important syndromes are **Weber syndrome, Benedikt syndrome, and Parinaud syndrome**.

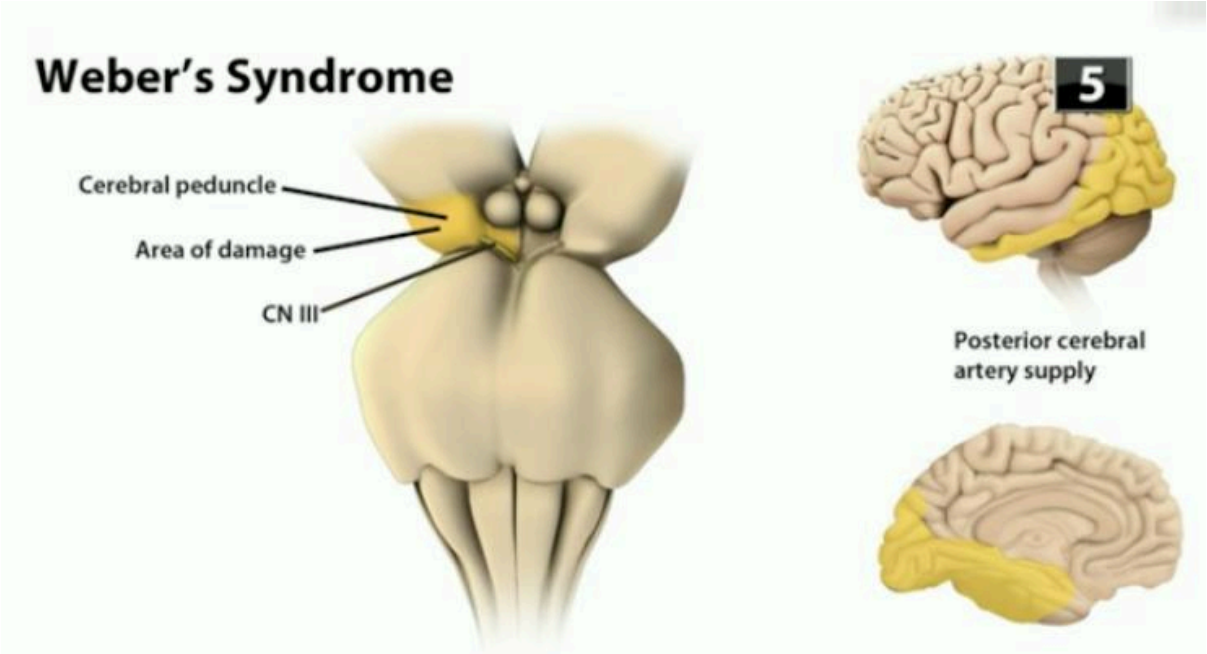



BENEDIKT'S SYNDROME

- Lesion of mid brain tegmentum
- Lesion effects –

1. Ipsilateral oculomotor palsy
2. Medial Leminiscus – Contralateral pain, touch, temperature, vibratory and proprioceptive sensations lost
3. Red nucleus and Superior cerebellar peduncles – Tremor, chorea and athetosis

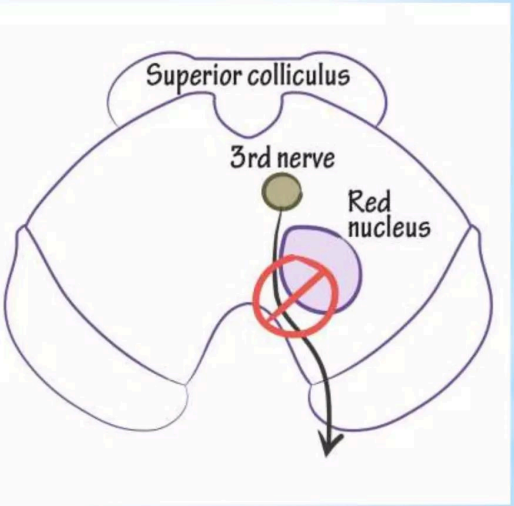

Syndromes of Mid brain

Parinaud syndrome

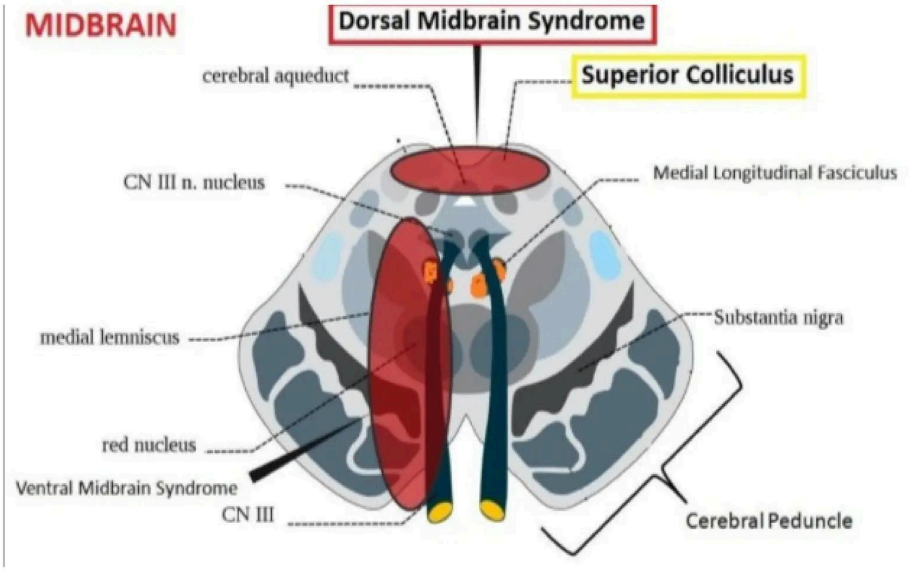

WEBER SYNDROME

Weber syndrome-occlusion of perforating branch of posterior cerebral artery

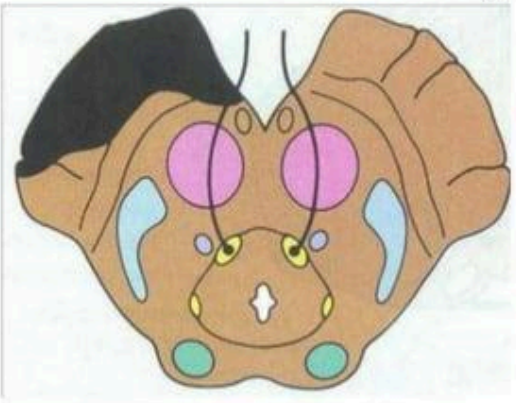

Clinical features

1.Ipsilateral

a.3rd nerve palsy

2.Contralateral

a.hemiplegia

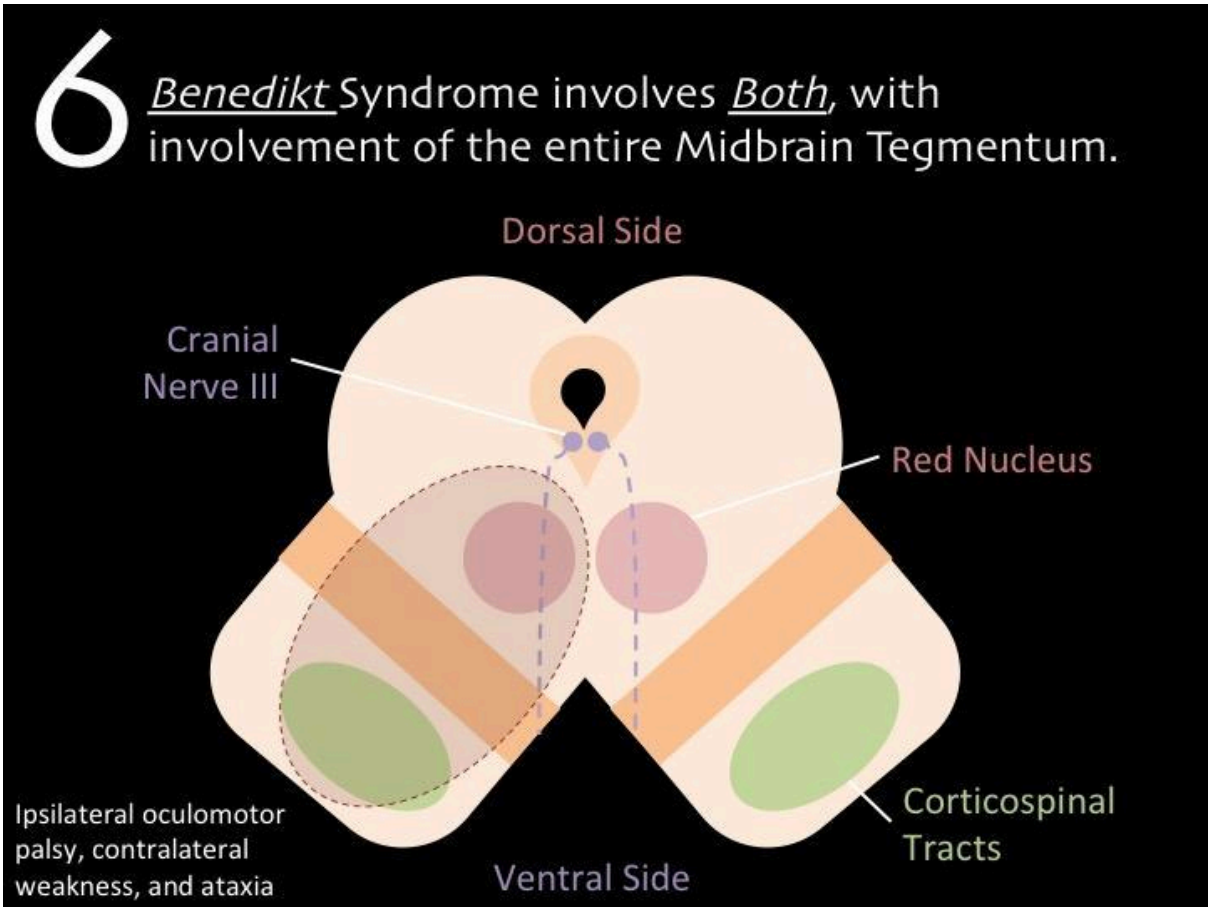
6
Benedikt Syndrome involves Both, with involvement of the entire Midbrain Tegmentum.
Dorsal Side
Cranial Nerve III
Red Nucleus
Corticospinal Tracts
Ventral Side
Ipsilateral oculomotor palsy, contralateral weakness, and ataxia

PARINAUD'S SYNDROME

- DORSAL MIDBRAIN SYNDROME
- Lesion affecting the tectum of mid brain in the region of superior colliculi
- In children, aqueductal stenosis and pinealoma
- In adults, demyelination, trauma and A-V malformations
- In elderly, vascular accidents and posterior fossa aneurysms

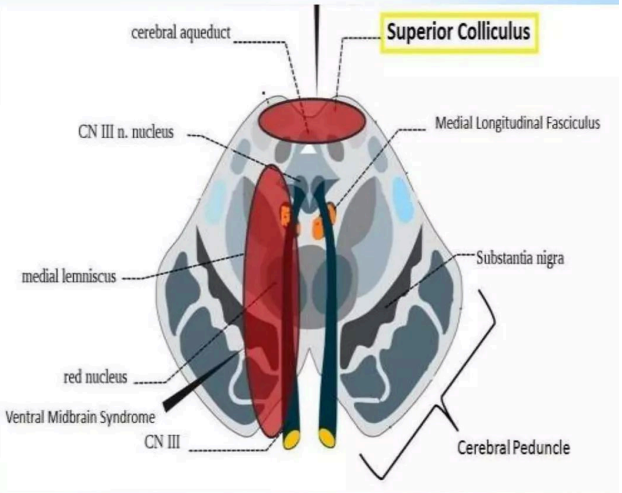



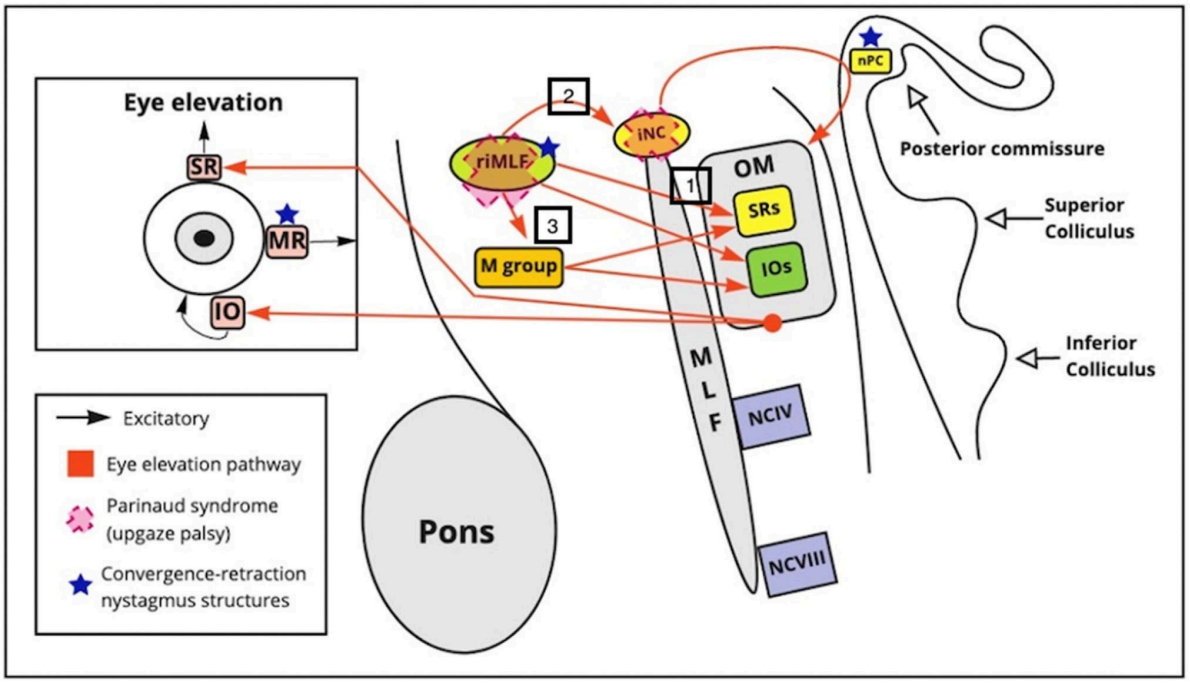

1. Weber Syndrome

Site of lesion: Ventral midbrain, particularly the **basis pedunculi/crus cerebri** and **oculomotor nerve fascicles**.

Structures involved:

- **Oculomotor nerve (CN III) fascicles**
- **Corticospinal tract**
- **Corticobulbar fibres**
- Often corticopontine fibres

Clinical features:

- **Ipsilateral 3rd-nerve palsy**
  - Ptosis
  - Eye deviated **down and out**
  - Diplopia
  - Dilated pupil may occur if parasympathetic fibres are involved
- **Contralateral hemiparesis** involving the arm and leg due to corticospinal-tract involvement
- Possible contralateral lower facial weakness from corticobulbar involvement

Anatomical basis:

Ipsilateral CN III palsy + contralateral hemiparesis = Weber syndrome

---

2. Benedikt Syndrome

Site of lesion: Tegmentum of the midbrain, especially the region containing the **red nucleus** and nearby structures.

Structures involved:

- **Red nucleus**
- **Oculomotor nerve fascicles**
- **Superior cerebellar peduncle fibres**
- **Medial lemniscus** may also be involved

Clinical features:

- **Ipsilateral oculomotor nerve palsy**
- **Contralateral involuntary movements**, such as:
  - Tremor
  - Choreoathetosis
  - Ataxia
- Contralateral impairment of proprioception/vibration may occur if the medial lemniscus is involved.

Anatomical basis:

Damage to the **red nucleus and cerebellar connections** produces abnormal contralateral movements, while involvement of **CN III fascicles** produces ipsilateral ocular-motor paralysis.

> **Ipsilateral CN III palsy + contralateral tremor/ataxia/involuntary movements = Benedikt syndrome**

---

3. Parinaud Syndrome

Also called **dorsal midbrain syndrome**.

Site of lesion: Dorsal midbrain/tectal region, particularly around the **superior colliculi and posterior commissure**.

Common causes include lesions affecting the pineal region, such as a **pineal-region mass**, but other lesions can produce the syndrome.

Structures involved:

- **Pretectal region**
- **Posterior commissure**
- Rostral interstitial nucleus of the medial longitudinal fasciculus and related vertical gaze pathways
- Superior collicular region

Clinical features:

A. Upward gaze palsy

The characteristic feature is difficulty moving the eyes **upward**.

B. Convergence-retraction nystagmus

Attempted upward gaze may produce abnormal **convergence and retraction of the eyes**.

C. Pupillary abnormalities

Pupils may show **light-near dissociation**:

- Poor response to light
- Better response during near accommodation

D. Eyelid retraction

Collier sign—upper-lid retraction—may occur.

Anatomical basis:

A lesion in the **dorsal rostral midbrain**, particularly involving the **posterior commissure and vertical gaze pathways**, interferes with the supranuclear control of vertical eye movements.

> **Dorsal midbrain lesion + upward gaze palsy + light-near dissociation = Parinaud syndrome**

Comparison of the Three Syndromes

Feature	Weber syndrome	Benedikt syndrome	Parinaud syndrome
Main location	Ventral midbrain	Tegmental midbrain	Dorsal/tectal midbrain
Major structure	Crus cerebri + CN III fascicles	Red nucleus + CN III fascicles	Posterior commissure/vertical gaze pathways
CN III palsy	Ipsilateral	Ipsilateral	Usually not the primary feature
Hemiparesis	**Contralateral**	May occur depending on extension	Not characteristic
Tremor/ataxia	Not characteristic	**Contralateral**	Not characteristic
Vertical gaze palsy	No	No	**Prominent**
Pupillary abnormality	May occur	May occur	**Light-near dissociation**
Typical association	Ventral midbrain infarction	Tegmental lesion	Pineal/dorsal midbrain lesion

Practical examination mnemonic

WEBER = Weakness
→ **CN III + corticospinal tract**

BENEDIKT = Bizarre movements
→ **CN III + red nucleus/cerebellar connections**

PARINAUD = Pretectal/Posterior commissure
→ **Paralysis of upward gaze**

These syndromes illustrate an important anatomical principle: **the exact clinical picture depends on which structures are involved within the midbrain—ventral long tracts in Weber, tegmental motor-control structures in Benedikt, and dorsal tectal/vertical-gaze pathways in Parinaud.**