Team Participation in Closed Reduction of Shoulder, Hip, Knee and Finger Joint Dislocations

(MBBS practical / competency-based clinical answer)

1. Learning objectives

The student should be able to:

- Recognise common joint dislocations and identify associated complications.
- Participate safely as a member of the reduction team under appropriate supervision.
- Perform and document pre- and post-reduction neurovascular examinations.
- Assist with analgesia, sedation, positioning, reduction, immobilisation and post-reduction imaging.
- Recognise emergencies requiring immediate orthopaedic intervention.

2. General principles of closed reduction

Closed reduction restores joint alignment without an open surgical incision. It should be performed by a trained clinician with suitable supervision, analgesia and monitoring.

Team roles



Add to Favorites

1. Team leader / orthopaedic clinician

Confirms the diagnosis, chooses the reduction technique, assesses contraindications and directs the procedure.



Add to Favorites

2. Analgesia and monitoring team member

Assists with prescribed analgesia or procedural sedation, monitors vital signs and prepares resuscitation equipment when sedation is planned.



Add to Favorites

3. Assisting student or clinician

Supports and positions the patient, documents neurovascular findings, prepares equipment and assists with controlled manoeuvres only as directed.

Essential steps before reduction

1. Explain the procedure, obtain consent where feasible and check allergies, comorbidities and relevant medication history.
2. Assess deformity, skin condition, swelling, open wounds and possible associated fractures.
3. Record distal pulses, capillary refill, skin temperature, sensation and motor function.

4. Obtain appropriate radiographs before reduction when indicated. Do not delay emergency reduction for imaging when limb viability is threatened and the responsible clinician judges immediate reduction necessary.
5. Provide adequate analgesia; procedural sedation may be needed. Monitor the patient according to local sedation protocols.
6. Prepare splints, slings, traction equipment and emergency support as appropriate.

3. Shoulder dislocation



Add to Favorites



Add to Favorites



6

Add to Favorites

Common type and mechanism

- Anterior dislocation is the most common type.
- It often occurs during forced abduction and external rotation, such as a fall on an outstretched arm.
- Posterior dislocation can occur after seizures or electrical injury and may be missed on a single AP radiograph.

Clinical features

- Severe shoulder pain and inability to move the arm.
- Loss of the normal rounded shoulder contour.

- Arm may be held slightly abducted and externally rotated in anterior dislocation.
- Possible axillary nerve injury: reduced sensation over the lateral deltoid region or impaired deltoid contraction.

Participation in reduction

1. Assist the patient into the position directed by the team leader.
2. Support the arm and avoid sudden or forceful movement.
3. Provide reassurance and assist with prescribed analgesia or sedation.
4. Under supervision, assist with the clinician-selected method, such as gentle scapular manipulation, external rotation or another appropriate technique.
5. Stop if there is marked resistance, worsening pain or new neurovascular impairment.

After reduction

- Repeat axillary nerve, distal sensory, motor and vascular examination.
- Obtain post-reduction radiographs to confirm alignment and assess associated fractures.
- Apply a sling or shoulder immobiliser as appropriate.
- Arrange orthopaedic follow-up and rehabilitation; duration of immobilisation depends on age, injury pattern and recurrence risk.

Complications: Axillary nerve injury, rotator cuff tear, greater tuberosity fracture, recurrent instability and vascular injury.

4. Hip dislocation



Add to Favorites



Add to Favorites

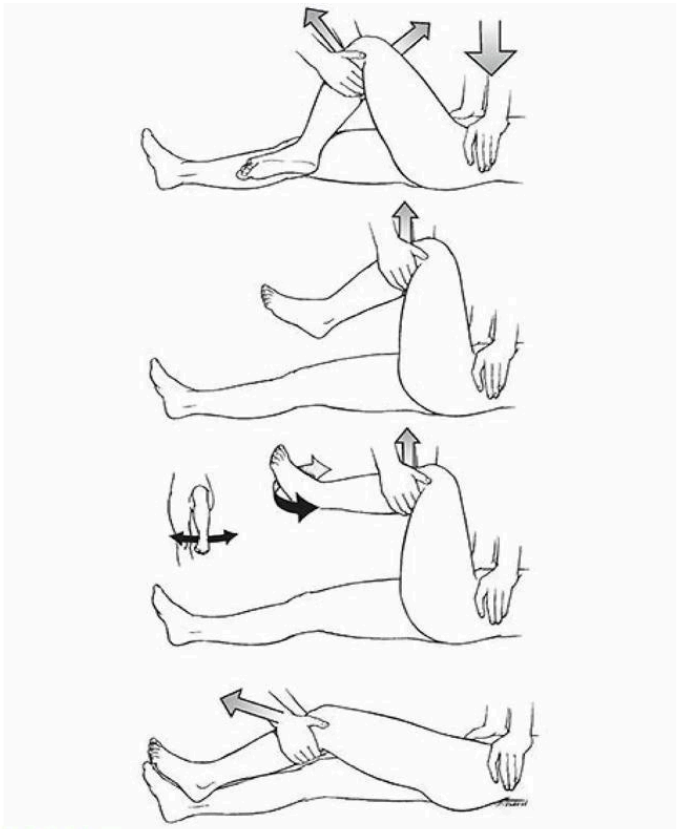

FIGURE 27.6 The Allis reduction technique for posterior hip dislocations. (From Bucholz RW, Heckman JD, Court-Brown C, et al., eds. *Rockwood and Green's Fractures in Adults*. 6th ed. Philadelphia: Lippincott Williams & Wilkins; 2006.)

Allis Method

•The patient is placed supine with the surgeon standing above the patient on the stretcher or table

•. Initially, the surgeon applies in-line traction while the assistant applies counter traction by stabilizing the patient's pelvis.

•While increasing the traction force, the surgeon should slowly increase the degree of flexion to approximately 70 degrees.

• Gentle rotational motions of the hip as well as slight adduction will often help the femoral head to clear the lip of the acetabulum.

• A lateral force to the proximal thigh may assist in reduction. An audible "clunk" is a sign of a successful closed reduction.

8

Add to Favorites

Common type and mechanism

- Posterior dislocation is most common, often following high-energy trauma such as a road traffic collision.
- The femoral head is displaced posteriorly, classically after force transmitted through a flexed knee.
- The limb typically appears shortened, flexed, adducted and internally rotated.

Clinical features and assessment

- Severe hip pain with inability to bear weight.
- Limb deformity and restricted movement.
- Sciatic nerve injury may cause foot drop, sensory loss or weakness.
- Assess for associated femoral head, acetabular and other pelvic fractures.

Participation in reduction

1. Treat as a major trauma injury; assist with primary survey and stabilisation.
2. Record sciatic nerve function, distal pulses and limb perfusion before reduction.

3. Assist with urgent radiographic assessment, generally including an AP pelvis and additional views or CT as indicated.
4. Prepare for urgent reduction under adequate anaesthesia or sedation by an experienced clinician.
5. Assist with positioning and controlled traction or other clinician-directed manoeuvres. Do not attempt unsupervised forceful manipulation.

After reduction

- Repeat and document sciatic nerve and vascular examination.
- Obtain post-reduction imaging; CT is commonly used to identify occult fractures or intra-articular fragments.
- Maintain appropriate precautions and arrange orthopaedic management and rehabilitation.

Important: A native hip dislocation is an orthopaedic emergency. Reduction should be performed as soon as safely possible, ideally within about six hours, to reduce the risk of avascular necrosis of the femoral head.

Complications: Avascular necrosis, sciatic nerve injury, post-traumatic arthritis, recurrent instability and associated fractures.

5. Knee dislocation



Add to Favorites

Mechanism and clinical features

- May follow high-energy trauma or, occasionally, lower-energy trauma in patients with obesity.
- Often involves disruption of multiple knee ligaments.
- Deformity may be obvious, but spontaneous reduction can occur before assessment.
- Major concern: popliteal artery injury and common peroneal nerve injury.

Participation in reduction

1. Assist with trauma assessment and immediate neurovascular examination.
2. Document dorsalis pedis and posterior tibial pulses, capillary refill, foot temperature, sensation and ankle/toe movement.
3. Help prepare urgent reduction by an experienced clinician; do not delay when the limb is threatened.
4. Assist with controlled positioning and stabilisation as directed.
5. Prepare a knee immobiliser or appropriate splint after reduction.

After reduction

- Repeat and document the neurovascular examination.
- Obtain radiographs to confirm alignment and assess fractures.
- Normal palpable pulses do not reliably exclude popliteal artery injury. Serial examinations and an ankle–brachial index (ABI) are required as part of the vascular assessment. An abnormal ABI, diminished pulses or other concerning findings warrant urgent vascular evaluation and imaging according to protocol.
- Arrange orthopaedic and, when indicated, vascular surgical assessment.

Complications: Popliteal artery thrombosis or rupture, compartment syndrome, common peroneal nerve palsy, multiligament instability and limb loss.

6. Dislocation of finger joints



Add to Favorites



Add to Favorites



7

Add to Favorites

Common types and mechanism

- Proximal interphalangeal (PIP) joint dislocation is common.
- Distal interphalangeal (DIP) and metacarpophalangeal (MCP) dislocations also occur.
- Usually caused by a ball striking the finger, a fall or forced hyperextension.

Clinical features

- Pain, swelling, deformity and inability to flex or extend normally.
- Check skin integrity, capillary refill, sensation and tendon function.
- Suspect an associated fracture, volar plate injury, collateral ligament injury or tendon injury.

Participation in reduction

1. Remove rings before swelling increases, if this can be done safely.
2. Assess neurovascular status and inspect for an open injury.
3. Obtain radiographs before reduction when appropriate, especially if a fracture or complex dislocation is suspected.
4. Assist the clinician with positioning and gentle, controlled traction or the joint-specific manoeuvre.
5. Never use forceful traction or repeatedly manipulate a joint that will not reduce.

After reduction

- Recheck alignment, circulation, sensation and tendon function.
- Obtain post-reduction radiographs to confirm congruity and identify fractures.
- Apply buddy taping or a suitable splint according to joint stability and associated injuries.
- Arrange early protected movement when appropriate to prevent stiffness; complex or unstable injuries require specialist follow-up.

Complications: Joint stiffness, chronic instability, tendon injury, fracture-dislocation and neurovascular damage.

7. Comparison of the four dislocations

Joint	Key structure at risk	Essential post-reduction step
Shoulder	Axillary nerve; axillary artery in severe injuries	Confirm alignment and reassess nerve function
Hip	Sciatic nerve; femoral head blood supply	Urgent imaging, including CT when indicated
Knee	Popliteal artery; common peroneal nerve	Serial vascular assessment, ABI and urgent vascular review when indicated

Finger	Digital neurovascular bundles; flexor/extensor tendons	Confirm joint congruity and assess tendon function

8. Final practical checklist

Before completing the procedure, the student should confirm:

- Patient identity, consent and correct joint.
- Appropriate assistance, equipment and monitoring.
- Documented pre-reduction neurovascular examination.
- Adequate analgesia or sedation when indicated.
- Assistance only within the assigned role and under supervision.
- Documented post-reduction neurovascular examination.
- Appropriate post-reduction imaging.
- Immobilisation, follow-up and rehabilitation plan.
- Clear documentation and handover, including any abnormal findings.

Key learning point: Successful reduction is not merely restoring the joint position. It also requires safe teamwork, recognition of associated fractures, repeated neurovascular assessment, confirmation of alignment and a clear plan for definitive care and rehabilitation.