

VAN 102 ASSIGNMENTS OF JOINTS


Topic: Hind Limb Joints

Roll no from 41-50

1. Sacro-iliac joint:

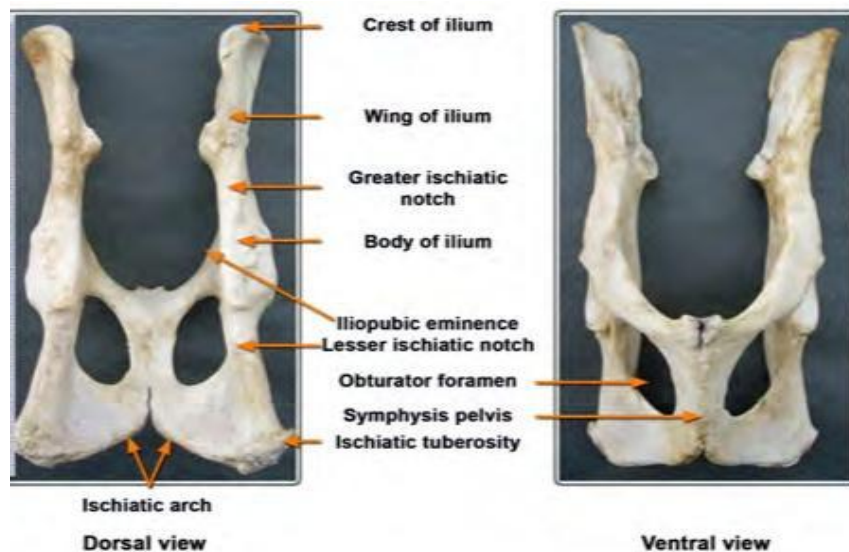
This joint is a diarthrosis formed between the auricular surface of the sacrum and ilium. These surfaces are not smooth in the adult, but are marked by reciprocal eminences and depressions and are covered by a thin layer of cartilage. The joint cavity is a more cleft and is often crossed by fibrous bands.

The joint capsule is very close fitting, and is attached around the margins of the articular surfaces. It is reinforced by the ventral sacro-iliac ligament which surrounds the joint. This is exceedingly strong above, where it occupies the angles between the ilium and the wing of the sacrum. It consists chiefly of nearly vertical fibres. The movements are inappreciable in the adult-stability not mobility, being the chief desideratum.



2. Pelvic symphysis:

The pubis and ischium of one side meet with the similar bones of the opposite sides in the median plane and forms a cartilaginous joint – the pelvic symphysis (symphysis pelvina). The layer of cartilage is replaced by bone in adult life. Its structure varies according to the species, sometimes to the age. The cranial portion of this joint is formed by medial borders of pubis bones and therefore, called pubic symphysis and the caudal portion similarly called ischial symphysis. The union of the bones is reinforced by connective tissue fibres, situated dorsally, ventrally, cranially and caudally.



3. Hip joint:

TYPE: BALL AND SOCKET

MOVEMENT: POLYAXIAL

BONES INVOLVED: Cotyloid cavity of os coxae and head of femur.

LIGAMENTS:

(a) Capsular ligament÷ it extends from the rim of the cotyloid cavity to the border around the head of femur. The synovial membrane is reflected on the round ligament. The joint cavity is capacious.

(b) Round ligament÷ It is an intra articular ligament extended from the fovea capitis at the head of femur to the non articular depression of the acetabular cavity.

(c) Cotyloid ligament÷ This is a fibro- cartilaginous structure attached along the rim of the cotyloid cavity to make it more deep .The part of cotyloid ligament which makes bridge over the acetabular notch is known as transverse ligament.

. The number of ligaments in this joint is very less. Therefore the surrounding muscles help to keep the bone in position.

Accessory ligament of femur (Check ligament) ÷ In the hip joint of equines an extra ligament is available. It is a strong band, detached from the symphysal tendons of abdominal muscles, pass through the aperture formed by the acetabular notch and transverse acetabular ligament and finally terminates in the wide notch on the head of femur along with the round ligament. However, this ligament is not found in other domestic mammals.

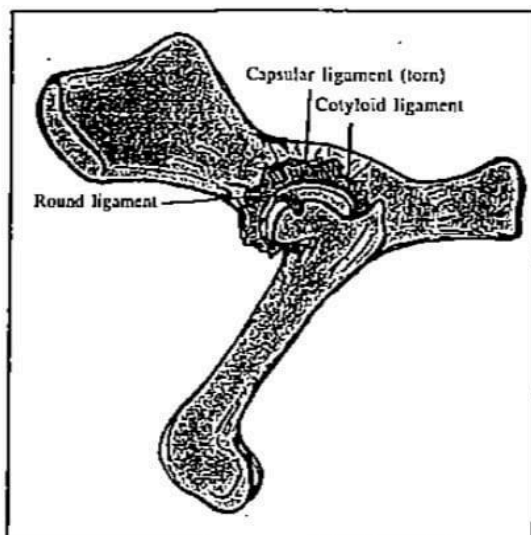


Fig. 3.10 Hip Joint.

4. Stifle joint:

The stifle of cattle is composed of the femoropatellar joint and the lateral and medial femorotibial joints. The femoropatellar joint is composed of the patella, trochlear groove, trochlear ridges of the distal femur, and lateral and medial cul-de-sacs. It qualifies as a sledge joint. The femorotibial joints are composed of the femoral condyles, the tibial condyles and median eminences, and the menisci. They are condylar joints medial, middle, and lateral patellar ligaments join the distal aspect of the patella to the proximal tibia. The 3 joints communicate with each other in 57% of cattle. The femoropatellar joint and the medial femorotibial joint always communicate.

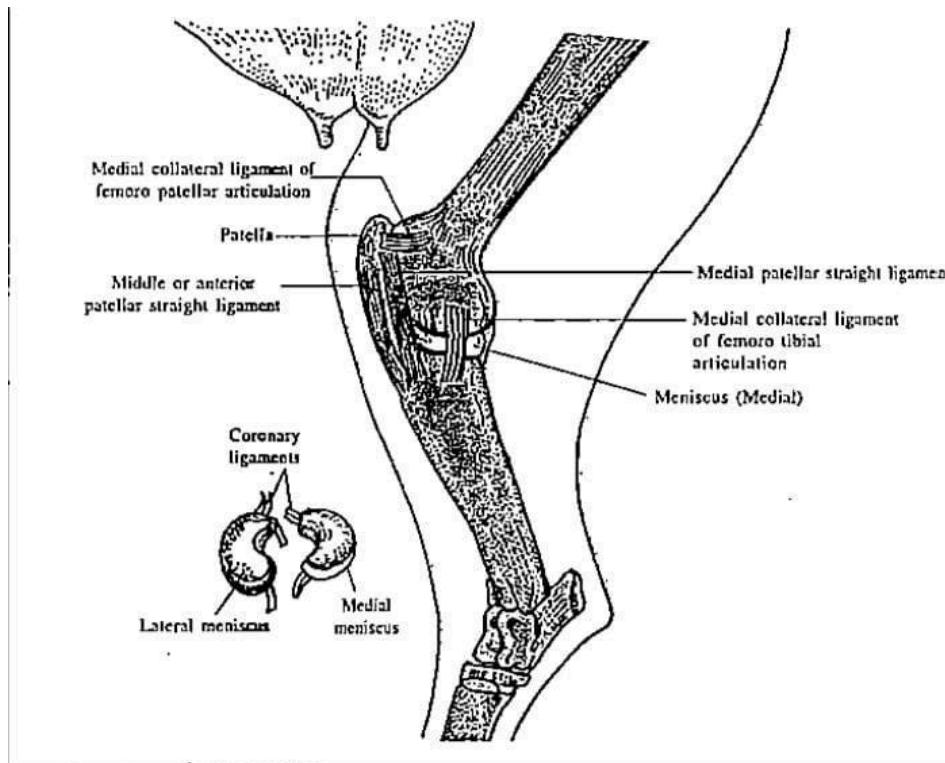


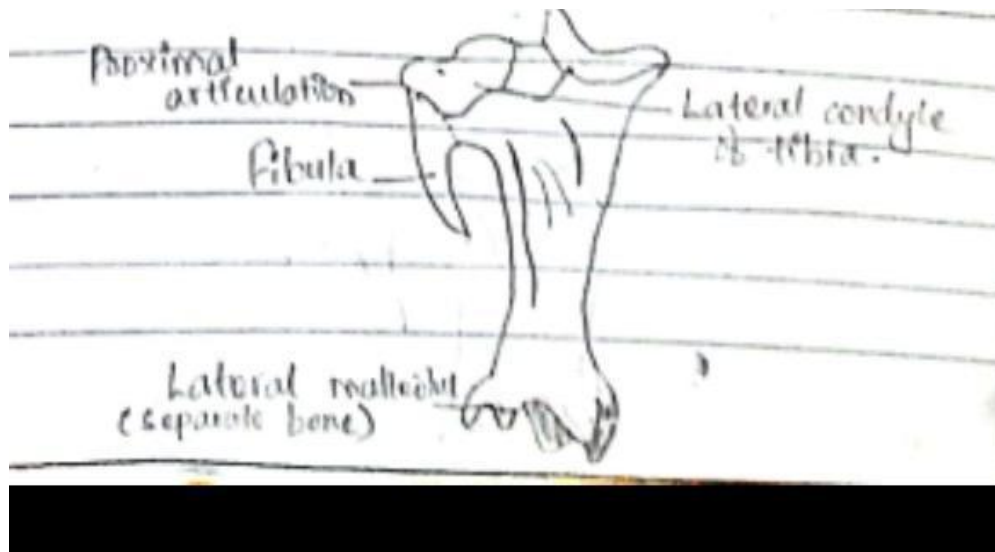
Fig. 3-11 Stifle Joint (Medial view).

5. Tibio-fibular joint:

The bony fibula is replaced by a ligament for most of its extent and thus proper tibio- fibular articulation is absent. The upper end of fibula fuses with lateral

tuberosity of fibula. The lower end ossifies as a separate piece of bone and forms diarthrosis with lower end of tibia: the movement here is imperceptible as two bones are united by strong peripheral fibres.

Motion:- Inappreciable as two bones are closely united by strong short fiber (i.e. peripheral fibres)



6. Hock joint:

Hock joint is a composite joint made up of a number of articulations

.It consists:

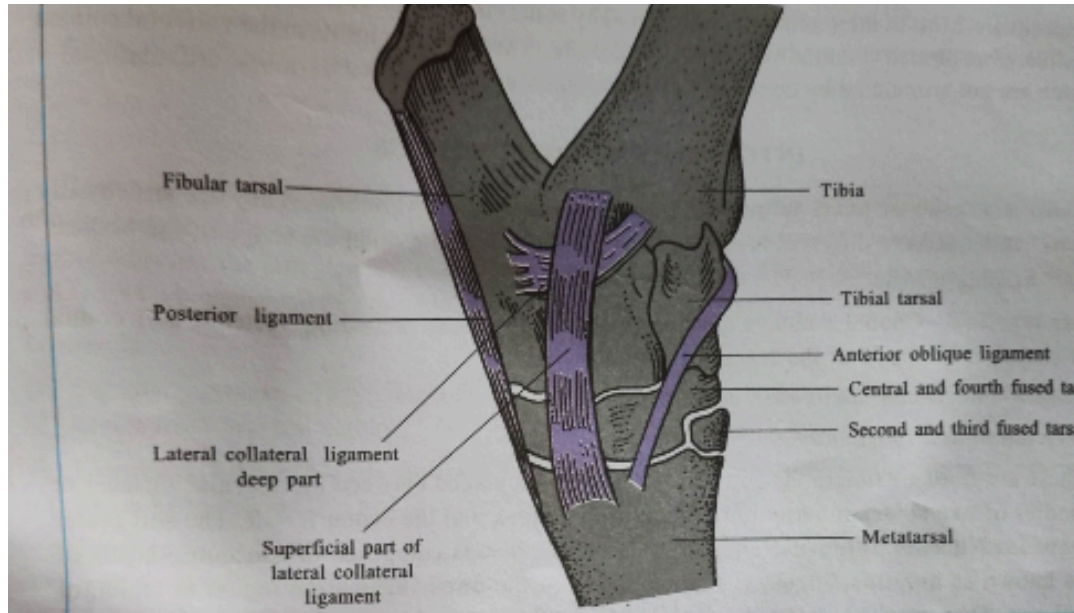
- a. Tibiotarsal articulation
- b. Intertarsal articulation and
- c. Tarsometatarsal articulation

Type: The tibiotarsal articulation is a typical ginglymus formed by the trochlea of the tibia tarsal bone and the corresponding surface of the distal end of tibia. The other articulations are arthodia, which have joint surface and ligaments of such a nature to allow only a minimal amount of gliding motion.

Bones involved: Distal end of tarsal, tarsal bones, lateral malleolus and proximal ends of metatarsal bone.

Movement: Tibiotarsal articulation=Extension and Flexion

Other articulation =Gliding



Ligaments:

a. Capsular ligament: It is divided into an anterior and posterior part. Both are lined by synovial membranes. The posterior part possesses a tendon sheath for the passage of deep digital flexor tendon.

b. Medial collateral ligament: It starts from the medial malleolus and divides into superficial middle and deep parts. The superficial parts inserts to the medial aspects of large and small metatarsal bone. The deep part attaches the tibia tarsal and the middle division terminates on the sustentaculum tail.

c. Lateral collateral ligament: It arises from the lateral malleolus and divides into superficial and deep parts. The superficial part hoes down vertically and terminates on the large metatarsal bone. The deep part is short. It turns backward below the superficial part and inserts on the fibular tarsal bone.

d. Anterior oblique ligament: This narrow band starts from the medial surface of tibial tarsal, crosses the anterior surface of the joint obliquely downwards and terminates on the lateral aspect of the proximal end of large metatarsal bone.

e. Posterior ligament: It starts from the tuber calcis, attaches the posterior border of os calcis, central and fourth fused tarsal and terminates at the large metatarsal bone.

7. Fetlock joint:

There are two such joints for each limb. Each is a ginglymus formed between the distal extremity of the large metacarpal, the proximal extremity of the first phalanx below and the proximal sesamoids behind.

Ligaments

The joint has a capsular, collateral and sesamoidean ligaments.

The capsular ligaments enclose the joints and adhere to the extensor tendons passing over the metatarsal.

The collateral ligaments are in the form of axial and abaxial ligaments.

The abaxial ligaments extend from the lateral aspects of the distal extremity of the large metatarsal to the abaxial sesamoids and the proximal extremity of the first phalanx below.

The axial ligaments arise common from the cleft of the large metatarsal bone and each spreads out on the cleft of the large metatarsal bone. It then spreads out and attached to the proximal part of the interdigital space of the first phalanx, where its fibres blend with the superior interdigital ligament.

The sesamoidean ligaments are superior, inferior, collateral and inter sesamoidean.

The superior sesamoidean or suspensory ligament (musculus interossei) arises from the volar face of the distal row of tarsal bones and the proximal extremity of the large metatarsal descends on the volar face of the latter and divides about its middle into two branches-anterior and posterior.

The posterior branch soon bifurcates at the distal end of the large metatarsus and each unites with one the divisions of the tendon of the superficial flexor of

the digit behind the fetlock to form a ring for the passage of the tendon of the deep flexor of the digit.

The anterior branch divides into six branches, which are in three pairs-abaxial, middle and axial.

The abaxial and middle slips are attached to the abaxial and axial sesamoids of each digit. The slips passing to the abaxial sesamoids detaches a slip which passes downwards the and forwards on the abaxial face of each digit to join the extensor tendon of the respective digit on the dorsal aspect.

The two axial slips pass into the cleft of the large metatarsal bone enter the inter-digital space and here join the same extensor tendons.

The suspensory ligament prevents extensive dorsal flexion of the fetlock joint and its slips prevent excessive volar flexion. In the young, the superior sesamoidean ligament is muscular while in the adult it becomes fibrous.

The inter-sesamoidean ligaments are three for each limb has three such ligament placed between four sesamoids.

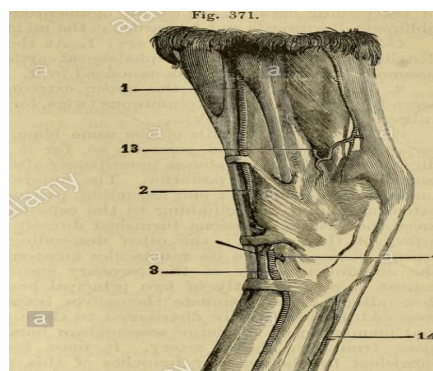
The collateral sesamoidean ligaments extend between the corresponding faces of abaxial sesamoids to the proximal extremity of the first phalanx and the lateral aspects of the large metatarsal.

The inferior sesamoidean are two straight and two oblique.

The straight ones are vertical, connecting the bases of the sesamoids to the upper end of the first phalanx.

The oblique ligaments are placed deeper, also extended from the base of the sesamoids; they cross and get attached to joint the first phalanx.

Motion: Extension and flexion.



8. Pastern joint:

Type: Hinge

Movement: extension and flexor

Bone involved: lower end of first phalanx and upper end of second phalanx

Ligaments:

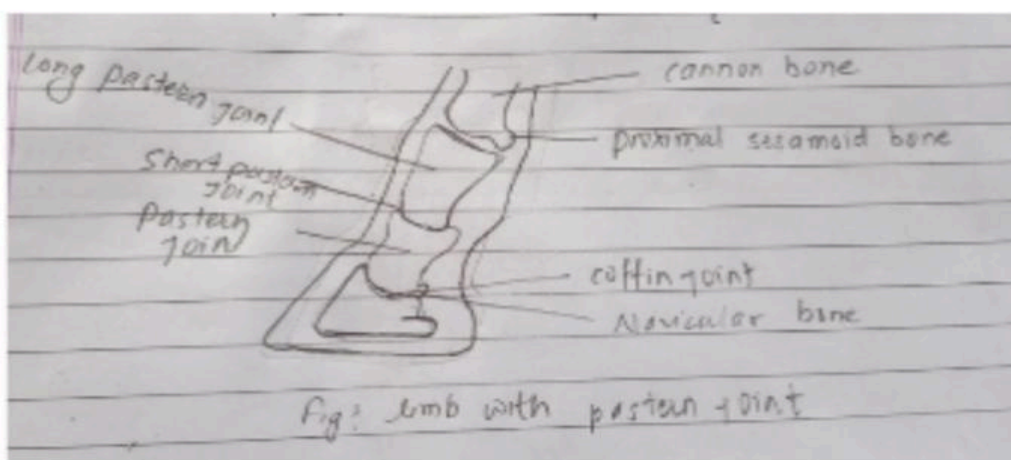
a. Capsular ligament

b. Lateral collateral ligament: It extends from the lateral aspect of the distal end of first phalanx and continues downward to lateral aspect of third phalanx

c. Medial collateral: It attaches the ventral end of first phalanx with the upper end of second phalanx at their posterior surface.

d. Postero central ligament: It attaches the ventral end of first phalanx with the upper end of second phalanx at their posterior surface

e. Postero lateral ligament: They connect corresponding borders and ends of first and second phalanges.



9. Coffin joint:

The joint is hinge joint and also called as saddle joint. The coffin joint is enclosed in hoof itself. It is the joint that exists between the third phalanx or coffin bone and short pastern bone.

The coffin joint moves in clockwise direction (second phalanx moving on third phalanx). There must be a counterclockwise resisting elastic band. Coffin joint contracture often begins within a few days of birth however; in early stage the common extensor tendon and extensor branches of suspensory tendons could act at coffin joint like elastic band. But the common extensor tendon is firmly attached to periosteum on dorsal surface of proximal and middle phalanges because of this attachment, the tendon can act as strong, passive, counterclockwise ligament resisting the clockwise rotation of coffin joint. Resistant has been used to indicate the movement acting opposite to the direction of joint movement. Between the two collateral ligaments which also hold it in suspension is called joint capsule and form the synovial fluid which lubricates the joint. The Navicular bone attached to coffin bone distally by impar ligament.

