

Periodontics

Lec.10

Phase II Surgical Therapy

In this phase the surgical techniques used for the following purposes :

1-Controlling or eliminating periodontal disease(surgical pocket therapy)

2-Correcting anatomic conditions that favor periodontal disease,impair aesthetics or impede placement of prosthetic appliances(plastic surgery,aesthetic surgery,pre prosthetic techniques)

3-Placing implants to replace lost teeth and improving environment for their placement and function

Periodontal surgery

Successful cause-related therapy (by the removal of plaque and calculus) will reduce gingival inflammation (edema, hyperemia and flabby tissue) there by making assessment of true gingival contour and pocket depth possible. In addition the soft tissue will be more fibrous and thus firmer, which facilitate surgical handling of the soft tissues. The propensity for bleeding is reduced, making the inspection of the surgical field easier.

The effectiveness of the patient's home care which is of decisive importance for the long term prognosis must be properly evaluated; lack of effective self performed plaque control will often mean that the patient should be excluded from surgical treatment.

Transient root hypersensitivity and recession of the gingival margins frequently accompany the healing process following close and open

Dr alaa omran University of Baghdad

S+ RP, thus the patient should be awarned that these results may happen.

Objectives of periodontal surgery

- 1-Accessibility and direct vision for proper S+ RP
- 2-Reduction or elimination of plaque retentive area especially periodontal pockets that have not responded to initial therapy.
- 3-Eliminate inflamed periodontal tissue
- 4-Enhancing the regeneration of periodontal tissue
- 5-Create a physiologic morphology of the dentogingival area that will facilitate efficient self performed plaque control
- 6-Correct mucogingival defect and improve periodontal aesthetic
- 7-Provide access to correct bony defects

Surgical treatment include

- 1-Gingivectomy for the removal of the over growth gingival tissues
- 2-Flap surgery
- 3-Distal wedge procedure
- 4-Mucogingival surgery for correction of mucogingival and aesthetic defect
- 5-Crown lengthening to increase clinical crown length
- 6-Guided tissue regeneration (GTR) to regenerate periodontal supporting structures

Gingivectomy

This surgical procedure aimed at the excision of the soft tissue wall of a pathologic periodontal pocket and this pocket elimination was

Dr alaa omran University of Baghdad

usually combined with recontouring of the diseased gingiva to restore physiologic form(e.g. Drugs induced gingival enlargement and the resulting false pocket can be removed by this method).

Indication

- 1-Gingival enlargement or over growth
- 2-Idiopathic gingival fibromatosis.
- 3-Shallow suprabony pocket
- 4-Minor corrective procedure

Contraindication

- 1-Infrabony pocket
- 2-Thickening of marginal alveolar bone and the need for bone surgery
- 3-Attached gingiva is narrow or absent

Advantage

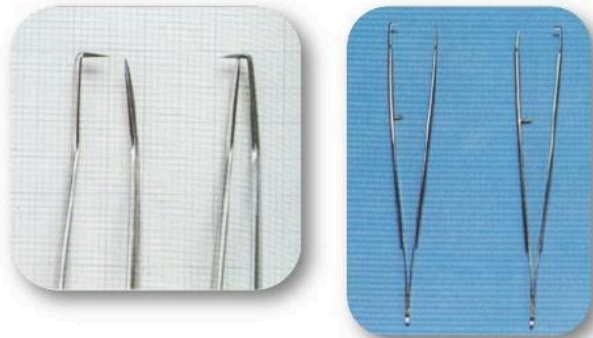
- 1-Technically simple, good visual access
- 2-Complete pocket elimination
- 3-Restoration of a physiologic gingival contour

Disadvantage

- 1-Gross wound, post operative pain
- 2-Healing by secondary intention
- 3-Danger of exposing bone
- 4-Loss of attached gingiva
- 5-phonetics and aesthetic problem in the anterior area with sensitivity due to exposure of the cervical area of tooth



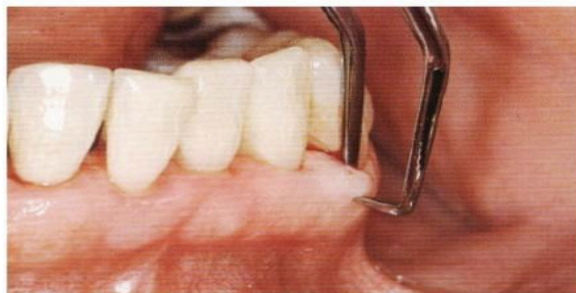Pocket marking forceps



- Paired (L & R)
- **Use:** indicate the location of the base of the pocket



Pocket marking forceps



Goldman gingivectomy procedure

-giving local anesthesia

-marking the pocket depth: the straight arm of pocket depth marker forceps is guided into buccal pocket, when the base of pocket is encountered, the

Dr alaa omran University of Baghdad

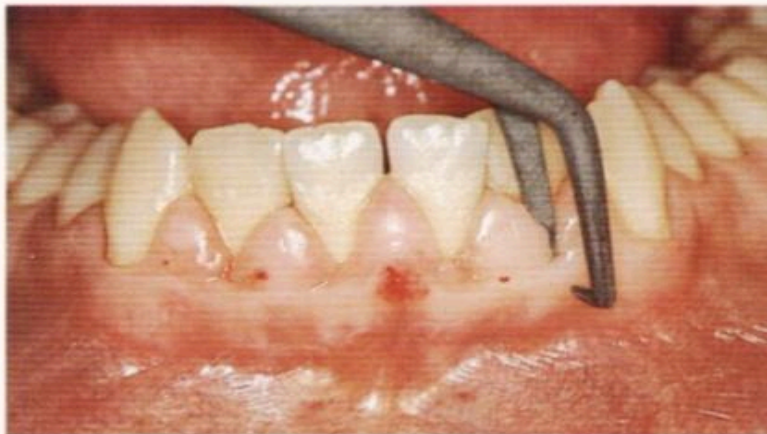forceps is pinched together causing the horizontal forceps tip to mark depth of pocket, by repeating this procedure at each tooth surface ,a series of bleeding points is created, which are used subsequently as a guide for incision.

Operative Procedure

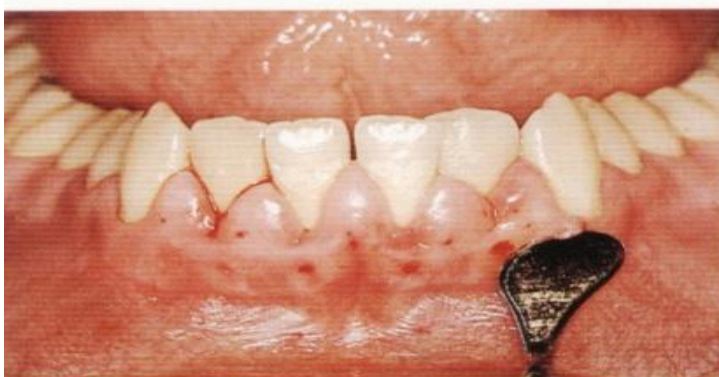414 Marking the base of pockets

The pocket marking forceps is used on papillae and on the midfacial marginal gingivae to indicate the course of the sulcus base between teeth 43 and 33.

An incision at this level would yield a blunt ledge of tissue; therefore, the incision must be made slightly apical to the bleeding points.



Operative Procedure

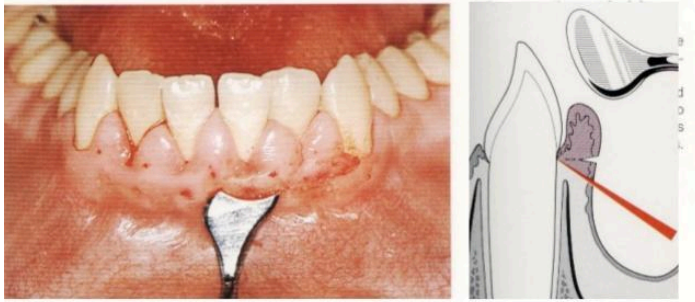


417 Proper position of the Kirkland gingivectomy knife

The GV knife is placed at a 45° angle to the tooth long axis, at the first marking point near tooth 33. From here a...

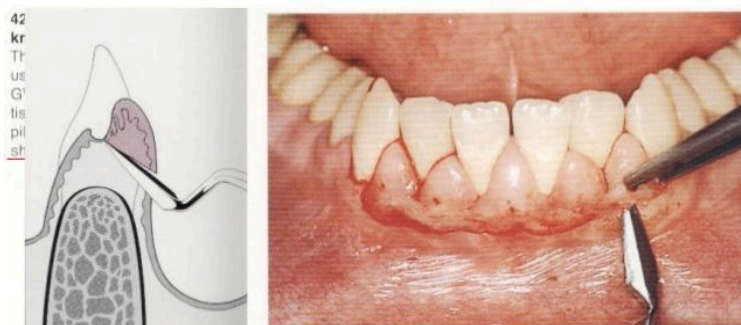Primary beveled incision which carried out 1 mm apical to bleeding points by Kirkland knife.

Operative Procedure



Continuous incision or interrupted , straight or scalloped is made.

Operative Procedure

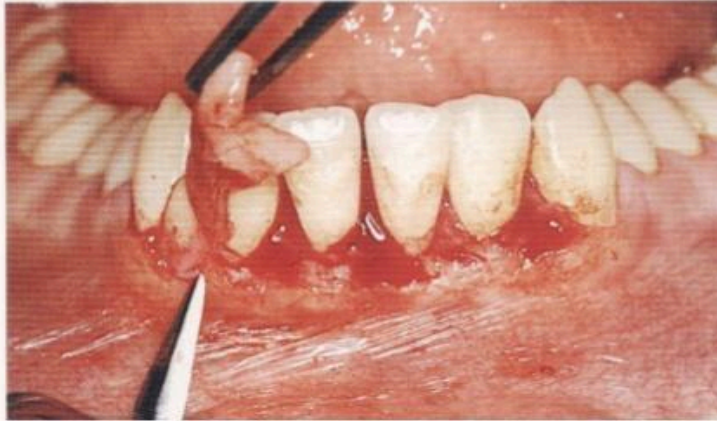

Secondary incision to separate the interproximal soft tissues from the interdental periodontium by Orban knife.

Operative Procedure

421 Removal of the tissue

The gingival segment is lifted gently with a forceps, and the papilla knife is used to sever any remaining tissue.



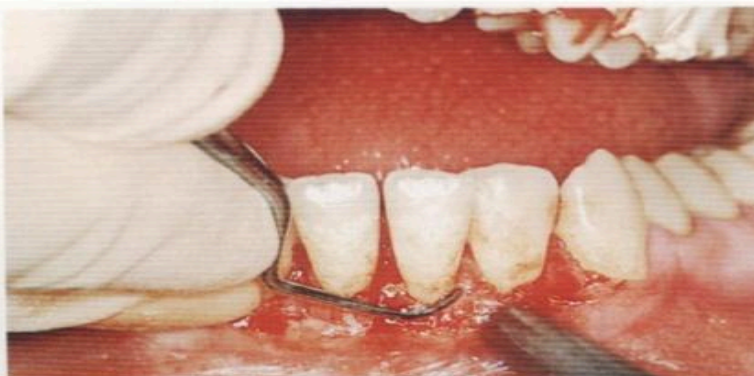
Careful removal of the incised tissues by a currete or a cumine.

Operative Procedure

423 Scaling and root planing with direct vision

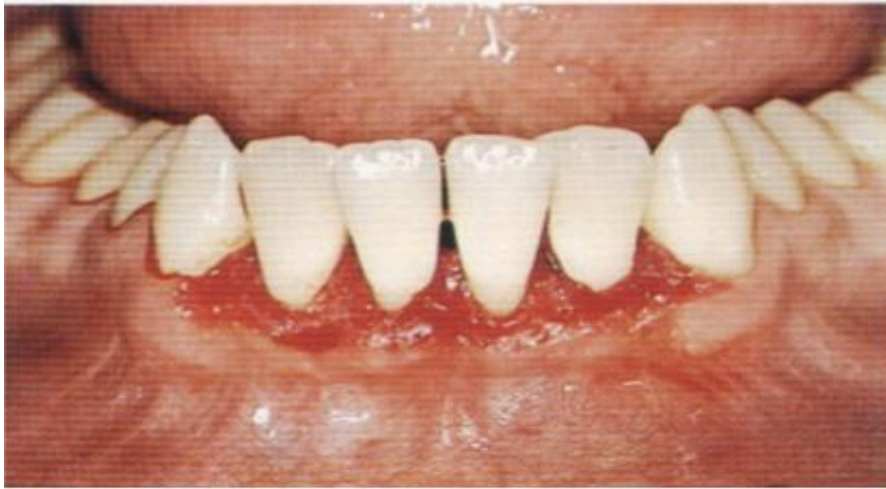Any plaque and calculus remaining in the pseudopocket after initial therapy becomes visible once the redundant tissue is removed, and can be eliminated completely during root planing.

Thus, the most important component of the gingivectomy procedure is the thorough cleansing and smoothing of the tooth. This will insure a bioacceptable surface as the new epithelial attachment and junctional epithelium form during the healing process.



By curette remove plaque, calculus and granulation tissues then smoothing teeth surfaces.

Operative Procedure

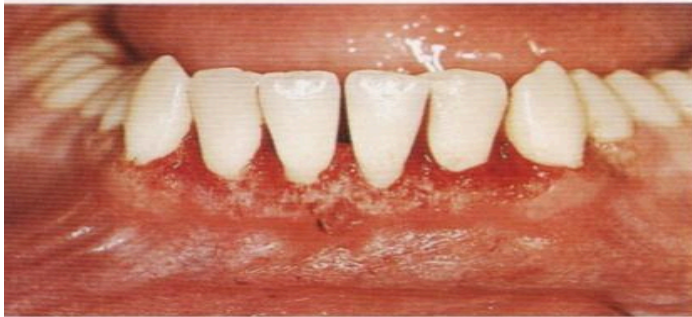

424 Gingivectomy wound after scaling

Despite the 45° angulation employed during surgery, the wound margin is still at a relatively sharp angle. This edge must be rounded in order to provide ideal gingival contour after healing.

Use Kirkland knife for gingivoplasty(minor alterations in gingival morphology without tissue excision)by shaving wound margin to create thin margin.

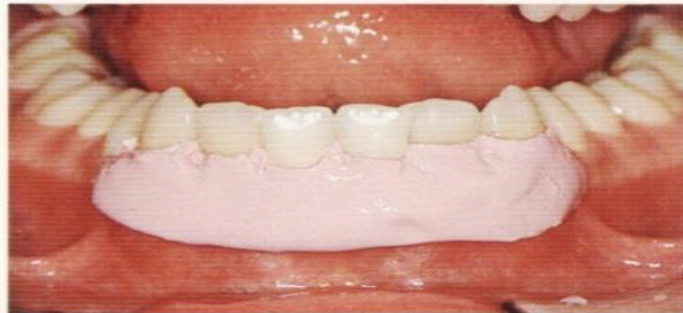Operative Procedure



427 Clinical view immediately following GV/GP
The surgical procedure has resulted in a relatively expansive open wound surface which must be covered and protected with a periodontal dressing.

Operative Procedure

429 Dressing in place
In this case, Peripac was used. This is a rigid dressing which must not encroach upon the mobile mucosa, to prevent formation of pressure areas and ulceration. The dressing should be left in situ for 7-10 days without changing it.



Control

bleeding by placing gauze packs Put dressing to cover the wound with pressure to prevent the bleeding with consequence formation of granulation tissue under dressing and without interference with occlusion or mobile mucosa

Flap surgery

Indications

- 1-In treatment of infrabony pockets
- 2-When the gingivectomy will lead to an unacceptable aesthetic results
- 3- Osseous recontouring (elimination of bony defect)

The Modified Widman flap Advantages

1-good access to root surface to facilitate S+ RP as well as the removal of the pocket epithelium and the inflamed connective tissue.

2-width of keratinized gingiva is maintained

3-replacement of the flap at presurgical location leads to less exposure of the root surfaces thus minimizes problem of aesthetic and root hypersensitivity.

4-cause minimal amount of trauma to the periodontal tissues and discomfort to the patient.

5-the possibility of obtaining a close adaptation of the soft tissues to the root surfaces.

6-provides better access to re-establish proper contour of the alveolar bone as well as the potential for bone regeneration in sites with angular bony defect.

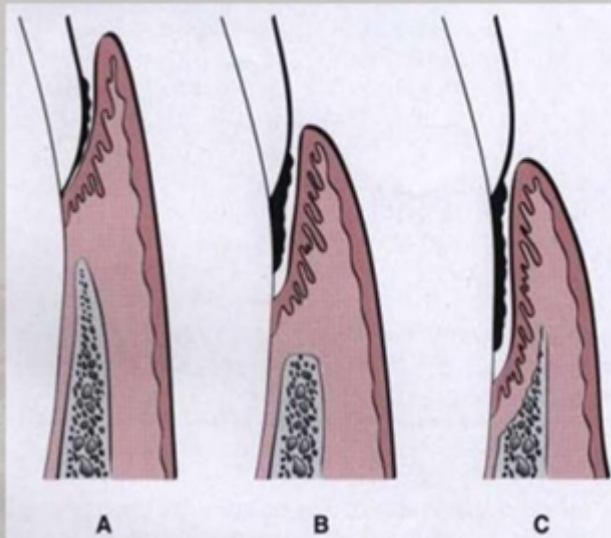
7-furcation areas can be exposed.

Following flap procedures and the removal of plaque, calculus and chronically inflamed granulation tissue, healing occurs by the formation of a Long junctional epithelium, this lead to reduced probing depth but that epithelium is more susceptible to plaque induced breakdown than the original connective tissue attachment and consequently post operative plaque control must be a very high standard, a new connective tissue attachment may form following flap procedures, although this cannot be predicted with certainty.

1. According to the relation to the crestal bone

Suprabony
supracrestal/
supraalveolar

Intrabony
subcrestal/
intraalveolar



CLASSIFICATION (Carranza)

FULL THICKNESS
FLAP

- Mucoperiosteal flap

PARTIAL
THICKNESS FLAP

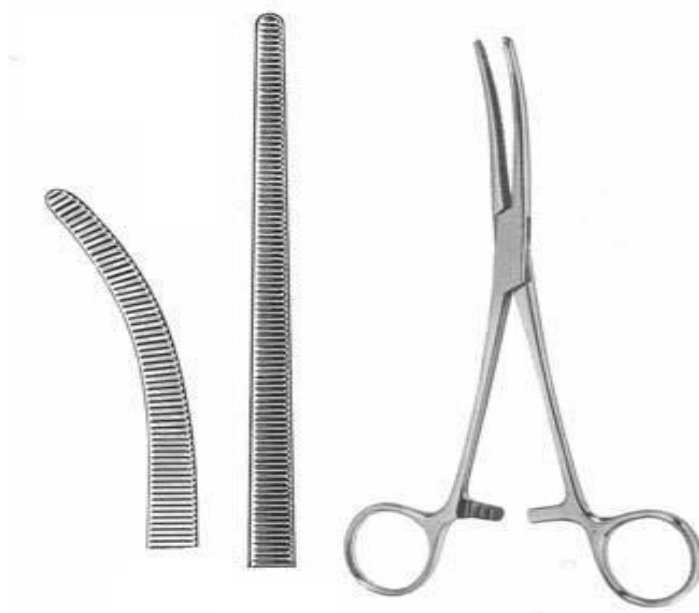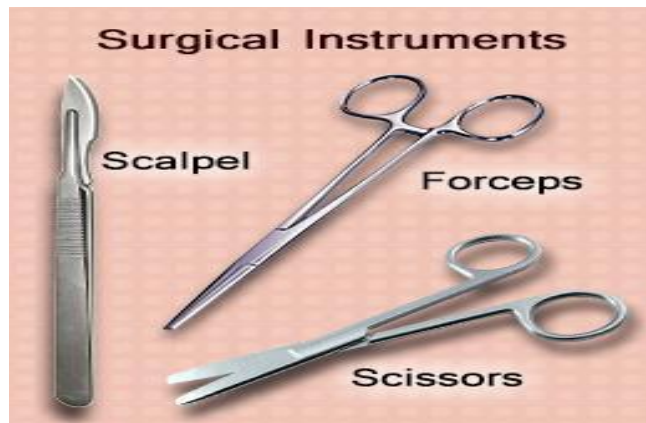- Split thickness;
mucosal



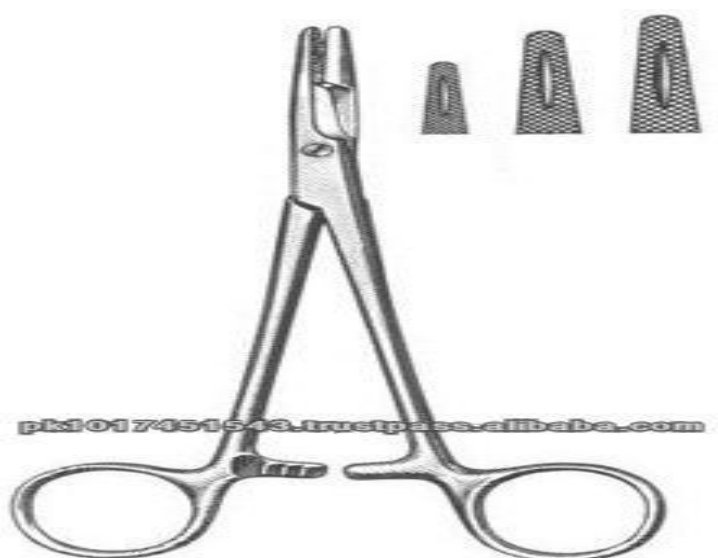
Blades





Periosteal elevator

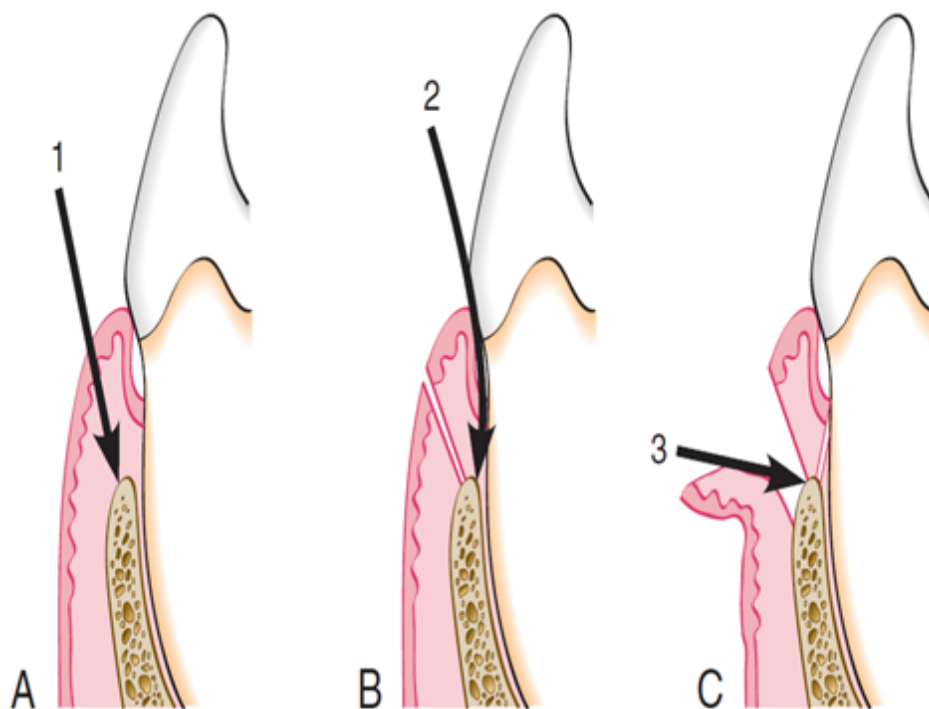
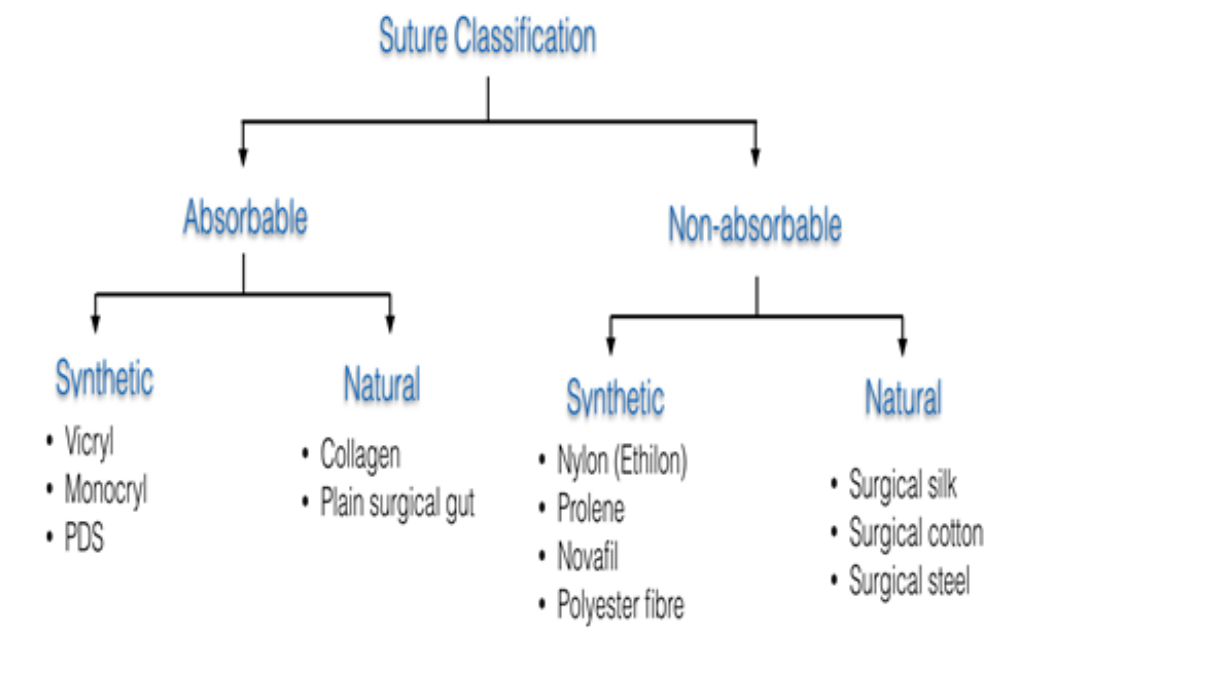


Hemostatic forceps, tissue forceps

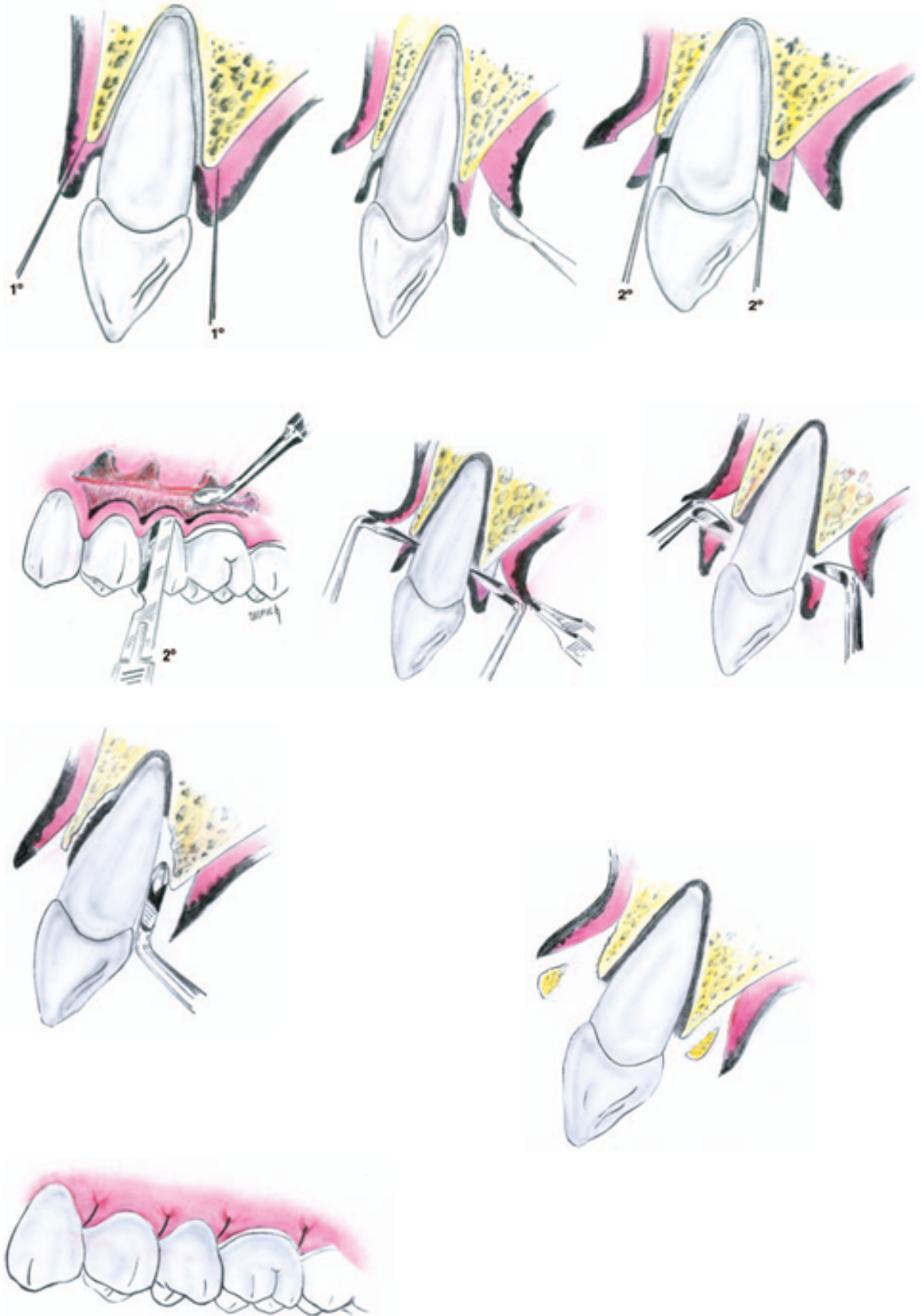




Suture



Three incisions of Modified widman flap



Modified widman flap ; reported in 1974 by Ramfjord and Nissle, it is a replaced flap. There are three incisions in this flap, it is usually conducted as following:

Primary incision:

a: First incision-scalloping

The scalloped incision is performed on both labial and palatal aspects, using the double-edge 12B scalpel. It is an inverse bevel incision extending to the alveolar crest. This incision thins the gingival tissue and permits complete closure of the interdental osseous defects postoperatively. The distance of the incision from the gingival margin may vary from 0.5 to 2mm. In this case, the incision is rather far from the gingival margin in most cases, this incision is made much closer to the free gingival margin

Flap retraction:

b: Flap reflection

An elevator is used to raise a full thickness mucoperiosteal flap as atraumatically as possible. The flap is reflected only to permit direct visualization of the root surface and the alveolar crest. In most cases it is possible to stay within the boundaries of the attached gingiva, without extending beyond the mucogingival line.

Secondary incision:

c: Second incision-crevicular

Dr alaa omran University of Baghdad

This incision is carried around each tooth, between the hard tooth structure and the diseased pocket epithelium, to the depth of the junctional epithelium. The 12B scalpel is used.

Third incision:

d: Third incision-horizontal

The horizontal incision is carried along the alveolar crest thus separating the infiltrated tissue from healthy supporting connective tissue, specially in the interdental area. The incision also permits atraumatic removal of the diseased tissue.

Direct root planing:

e: Root planing with direct vision

Fine curettes are used to remove remnants of pocket epithelium and granulation tissue, calculus necrotic cementum to obtain smooth, hard, clean surface. Root planing is performed with repeated rinsing. Root planing is the most important part of both the modified Widman procedure and all other periodontal surgical procedures.

Suturing:

f: Complete coverage of interdental defects

The labial and palatal flaps are closed over the interdental areas without tension, using interrupted sutures. The flaps should be adapted to the underlying bone and the necks of the teeth. New papillae were created by the scalloped form of the initial incision. These make it possible to cover interdental defects (e.g. bony defects) even when the interdental space is wide. For this reason, placement of a periodontal dressing is not absolutely necessary.