Title of the Article (Arial 16)

*Author[1], Author[1]***(Arial 12)**
Affiliation of the Author **(Times New Roman 9)**

Abstract (Times New Roman 12)

Background: Times New Roman 11, single space, contains the brief description of the research.

Case: Times New Roman 11, single space, contains the brief description of the research.

Conclusion: Times New Roman 11, single space, contains the brief description of the conclusion.

Keywords: Foreign body, Aspiration, Granulation tissue, Bronchoscopy **(Times New Roman 11)**

MRJ Year; Volume(Number):xx page-xx page

1. Introduction (Times New Roman 12)

Body paragraph is written using Times New Roman 12 with 1.5 space. The content of introduction usually is the background of research and position of the research towards the other similar research. It also can be a brief literature review. Reference cited according to **Vancouver,** numbered in accordance with the order of references in the research and in accordance with the sequence number in the bibliography. The number is written after dot "." in superscript. In writing the citations and references, authors are recommended to use reference management software, such as: **Mendeley®** or **Zotero.**

2. Case

This section presents the description of case report. It is written using Times New Roman 11, 1.5 space. It may be followed by table or picture to illustrate the case. All the figures, tables or informative illustration are prepared as HD image file.

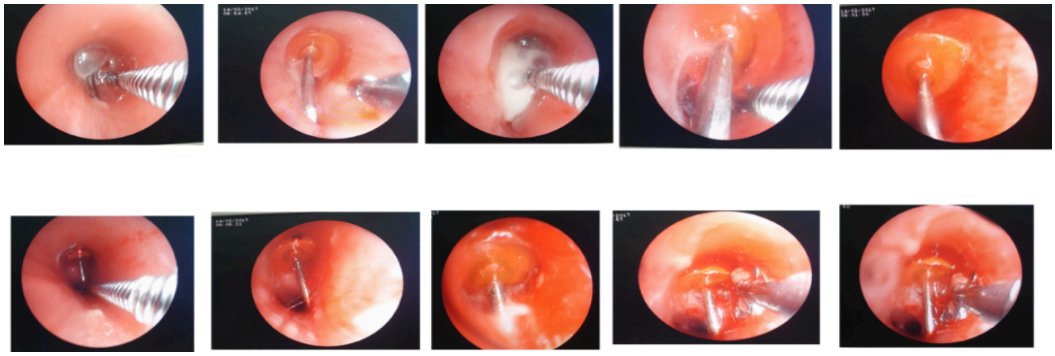

Figure 1. The figure note must be written in Times New Roman 10, justify, and place directly below the illustration.

3. Discussion

The content consists of the data and information that have been collected. It should be written using Times New Roman with 1.5 space with single space. The finding systematically might be supported by charts, tables, figures or informative illustrations.

Table 1. Legend should be written in Times New Roman 10 with single space and placed above the table content, Justify. Apply the line only for top and bottom border.

aaaa	bbbb	cccc
ddddd	hhhhh	mmmmm
eeeee	iiiii	nnnnnn
fffff	jjjjj	oooooo
ggggg	kkkkk	
	llllll	

The Nota Bene should be written in Times New Roman 10 with single space and placed directly below the table content, justify, italic.

4. Conclusion

Conclusion should clearly state the result of correlated objective (and may also possible with future direction). Avoid using point or numbering. It should be written using Times New Roman 12 with 1.5 space.

References (Times New Roman 11, Bold. It is written according to Vancouver, numbered in accordance with the order of references in the research and in accordance with the sequence number in the bibliography. Please use the reference with the most recent publishing year)

1. Dickenson O, Usalan C, Filiz A. 2002.Foreign Body Aspiration: Clinical Utility of Flexible Bronchoscopy.Postgrad Med Journal Vol 78; pp. 399-403.
2. Estella A. 2012. Bronchoscopy in Mechanical Ventilated Patients in Global Perspective of Bronchoscopy. Chapter 5.
3. Gay SB, Shaffer HA, Vu QDM, Marker CO, Kuzminski CD, Christensen JD, Bassignani MJ, Lange EE, Brant WE, Lamber DL, Padgett AV, Blount KJ, Momenian SH, Wasti MF, Fakhran S, Ho CP, Tatineny KC, Kori GA. 2013. Introduction to Gastrointestinal Radiology. University of Virginia, Health Sciences Center, Departement of Radiology.www.med-ed.virginia.edudiaksestanggal 8 Oktober 2015
4. Hitter A, Hullob E, Durand C, Righini CA. 2011. Diagnostic Value of Various

Investigations in Children with Suspected Foreign Body Aspiration Review. European Annuals of Otorhinolaryngology, Head and Neck diseases Vol.128. pp. 248-52.

5. Kaushal P, Brown DJ, Lina L, Bretzke S, Shah RK. 2011. Aspirated Foreign Bodies in Pediatric Patients, 1968-2010: A Comparison Between the US and Other Countries. International Journal of Pediatric Otorhinolaryngology Vol 75;pp. 1322–1326.
6. Marquette CH, Martinot A. 2000. Foreign Body Removal in Adult and Children. Interventional Bronchoscopy.Karger, Basel, pp. 96-106.
7. Junizaf M. 2007. Benda Asing di SaluranNapas, dalamSoepardi E, Iskandar N, Bashiruddin J, Restuti R. Buku Ajar IlmuKesehatan THT-KLEdisi 6. Jakarta. BalaiPenerbit FKUI. pp. 259-65.
8. Schoem SR, Rosbe KW, Bearelly S. 2015. Cumming Otolaryngology:Aerodigestive Foreign Body and Caustic Ingestion. 6th Ed. ElvesierSauders: Philadelphia. pp. 3185-6