REPLACE WITH UNI LOGO

BACHELOR OF MEDICINE AND BACHELOR OF SURGERY

FACULTY OF MEDICINE

DEPARTMENT OF SURGERY

SURGERY (MED XXXX) CASE WRITE-UP 1/2

CASE TOPIC:

RECTOSIGMOID CARCINOMA

NAME. :

MATRIX NUMBER. :

YEAR/SESSION. :

GROUP/ROTATION. :

POSTING. :

SUPERVISORS. :

EMAIL. :

YEAR 3 SURGERY I CASE WRITE UP MARKING SHEET

STUDENT'S NAME:

MATRIX NUMBER:

Case 1 Diagnosis		
Core component	**Marks Allocated (%)**	**Marks Given**
History		
Physical Examination		
Provisional Diagnosis & DIfferential Diagnosis		
Investigation		
Management & Discussion		
References		
Total	**100**	

INTERNAL MEDICINE

PATIENT BIODATA

- **Registration No.:** KMC-98765
- **Name:** Madam S
- **Age:** 74 years old
- **Gender:** Female
- **Ethnicity:** Malay
- **Occupation:** Retired
- **Address:** Jalan Permai, Kota Bahru
- **Ward/Bed:** 6B/12
- **Date of Admission:** 05/11/2023
- **Date of Clerking:** 06/11/2023
- **Informant:** Patient's daughter

1. **HISTORY**

1.1 CHIEF COMPLAINT

Madam S, a 74-year-old Malay lady with underlying hypertension, presented with a 2-week history of progressively worsening shortness of breath.

1.2 HISTORY OF PRESENTING ILLNESS

She was well until 2 weeks prior to admission when she started experiencing **shortness of breath (SOB)** on exertion, initially on climbing one flight of stairs (NYHA Class II). This has since worsened and she now feels breathless with minimal activity, like walking to the bathroom (NYHA Class III). She also reports **orthopnea** (needing to sleep with 3 pillows) and **paroxysmal nocturnal dyspnea (PND)**, waking up gasping for air two to three times a night.

She also complains of **pitting bilateral lower limb edema** for the past one week, which is worse at the end of the day. She has noticed a persistent **non-productive cough** and has a reduced appetite. She has a documented weight gain of 3 kg over the last 2 weeks. She denies chest pain, palpitations, fever, or syncopal attacks.

1.3 SYSTEMIC REVIEW

- General: Fatigue and weakness otherwise no not complain of loss of weight and loss of appetite.
- Cardiovascular: No chest pain or palpitations.
- Respiratory system: She did not complain of cough, haemoptysis and rhinorrhoea.
- Gastrointestinal system: Anorexia, no nausea, vomiting, or abdominal pain.
- Nervous system: She did not complaint of headache, dizziness, blurring of vision, syncope and numbness of any part of the body.
- Urinary system: She reports a decrease in urine output. No urgency, dribbling, retention, incontinence, abnormal urine stream and haematuria.
- Musculoskeletal system: No complaint of leg pain, muscle cramps, myalgia and arthralgia.
- Skin: No complain of rashes, petechiae and bruises.

1.4 PAST MEDICAL HISTORY

- **Hypertension:** Diagnosed 15 years ago, well-controlled with medication.

- **Type 2 Diabetes Mellitus:** Diagnosed 10 years ago, on metformin.
- **Dyslipidemia:** Diagnosed 8 years ago, on atorvastatin.
- **Chronic Kidney Disease (CKD):** Stage 3, diagnosed 3 years ago.

1.5 PAST SURGICAL HISTORY

- Appendectomy at 20 years old. No subsequent complication

1.6 DRUG HISTORY

The patient is compliant to all medication and has not experienced any side effects or complications.

- **Hypertension:** Ramipril 5 mg OD
- **Diabetes:** Metformin 500 mg BD
- **Dyslipidemia:** Atorvastatin 20 mg ON

1.7 ALLERGY HISTORY

No known drug or food allergy.

1.8 FAMILY HISTORY

- Both parents passed away. His Father passed away at 68years old due to a heart attack and mother passed away at 74 years old due to hypertensive complications. One elder sister with hypertension. Other siblings are alive and well. He has 2 children, both healthy.

1.9 SOCIAL HISTORY

- A retired clerk, currently living with her daughter in Klang. She is financially supported by both her children. Non-smoker, no alcohol consumption. Diet is high in salt, but she has recently reduced it.

1.10 IDEA, CONCERN, EXPECTATION

- **Idea:** Thinks her shortness of breath is due to her "weak heart."
- **Concern:** Worried about being a burden to her family.
- **Expectation:** Wants to feel better and be able to perform her daily activities without getting breathless.

2. PHYSICAL EXAMINATION

Chaperone present, consent obtained.

2.1 GENERAL INSPECTION

On general inspection, the patient was alert, fully conscious, and breathing comfortably while lying at a 45° angle. She appeared pale and had a walking frame placed beside bed. Notably, she had two brachiocephalic fistulas on both his right and left upper arms, and a branula inserted on the dorsum of his left hand. His vital signs were recorded as follows:

- **BP:** 150/90 mmHg
- **HR:** 98 bpm, regular
- **RR:** 24 breaths/min
- **Temp:** 36.8°C
- **SpO_2:** 92% on room air

2.3 GENERAL EXAMINATION

- Hands: On examination, the patient's palms were cold. There was no nail bed fluctuation, tobacco staining, clubbing, splinter haemorrhages, Osler nodes, Janeway lesions, tendon xanthomas, or palmar xanthomas. Capillary refill time was less than one second. Radial pulses were 120 beats per minute, regular, with good volume and normal character. There was no radio-radial delay, radio-femoral delay, or collapsing pulse. Brachial pulses were also of good volume and normal character.
- Eyes: Conjunctival pallor was noted, but there was no scleral jaundice, xanthelasma, or corneal arcus.
- Mouth: Oral hygiene was good, with no central cyanosis or high-arched palate.
- Neck: No carotid bruits were detected. Carotid pulses were of good volume and normal character. Jugular venous pressure (JVP) was not visible.

2.4 SYSTEMIC EXAMINATION

Cardiovascular System:

- Inspection: The chest was symmetrical, with no midline sternal scars, deformities, or visible pulsations.
- JVP: Elevated at 8 cm
- Palpation: Displaced to the 6th intercostal space, anterior axillary line, suggesting **cardiomegaly**.. No parasternal heave or thrills were felt over the four valve areas.
- Auscultation: S1 and S2 were heard. S3 heart sound noted, no murmurs.
- Respiratory findings: bi-basal crepitations on inspiration sufgestive of pulmonary edena

Peripheral:

- **Edema:** Bilateral pitting edema up to the mid-thigh.
- **Pulses:** Radial pulses are regular, of good volume.

3. CASE SUMMARY

Madam S.H.M, a 74-year-old female with a history of hypertension, diabetes, dyslipidemia, and CKD, presents with a 2-week history of progressively worsening dyspnea, orthopnea, PND, and bilateral pitting pedal edema. On examination, she is dyspneic, with an elevated JVP, displaced apex beat, S3 heart sound, and bilateral basal crepitations. Her SpO_2 is 92% on room air. These findings are highly suggestive of acute decompensated congestive heart failure..

4. DIAGNOSIS

4.1 Provisional

Acute Decompensated Congestive Heart Failure (ADHF) The patient's clinical presentation, including progressively worsening dyspnea, orthopnea, PND, and signs of fluid overload (bilateral crepitations, elevated JVP, and pitting edema), strongly points to ADHF. The presence of multiple cardiovascular risk factors and a displaced apex beat further supports this diagnosis.

4.2 Differential Diagnoses

Differential Diagnosis	**Supporting Points**	**Points Against**
Pneumonia	Could cause dyspnea, cough, and a low-grade fever.	No productive cough. The physical exam shows signs of fluid overload (elevated JVP, S3, pedal edema) that are not typical for pneumonia.

Pulmonary Embolism	Can cause acute dyspnea and hypoxia, similar to a heart failure exacerbation.	The patient's symptoms have been progressive over a 2-week period, not sudden. The physical exam shows classic signs of fluid overload (JVP, crepitations, edema), which are not a feature of PE.
AE COPD	Can cause dyspnea and cough, especially in older patients.	The patient is a non-smoker and has no history of chronic cough or other features of COPD. The primary physical findings are those of heart failure, not lung disease.

5. **INVESTIGATION**

*For each test include the result if available.

1. Full Blood Count (FBC)
   - Aim: To assess for anaemia, which may precipitate the patient's condition, and to check for infection.

   - Result: White blood cell count was within normal range, indicating no infection. Red blood cell count and haemoglobin were moderately reduced, suggesting moderate anaemia. MCV was elevated, consistent with macrocytic anaemia, likely due to folate and vitamin B12 deficiency secondary to end-stage renal failure.

2. Renal Function (RF)
   - Aim: To look for electrolyte imbalance and assess severity of renal impairment, as derangements may worsen the patient's condition.

   - Result: Elevated BUN and creatinine levels, hypochloremia, and reduced BUN/Creatinine ratio, consistent with end-stage renal failure.

3. Cardiac Biomarker (Troponin I)
   - Aim: To detect cardiac cell injury or necrosis.

   - Result: Troponin I was elevated, indicating myocardial injury/necrosis, suggestive of acute coronary syndrome (STEMI/NSTEMI).

4. Electrocardiogram (ECG)
   - Aim: To detect ischaemic changes of the heart.

   - Result: Heart rate 65 bpm with regular rhythm. Left axis deviation, suggestive of left ventricular hypertrophy. Anteroposterior wall ST-segment depression noted, consistent with myocardial ischaemia.

5. Chest X-Ray (CXR)
   - Aim: To look for evidence of cardiomegaly and pleural effusion.

   - Result: Clear cardiac borders bilaterally, no widened mediastinum, no costophrenic angle blunting. Mild cardiomegaly present.

6. Other Suggested Investigations
   - Lipid profile: To assess cholesterol levels.

- Fasting blood glucose & HbA1c: To assess glycaemic control and compliance with therapy.

    - **Aim:** To assess for signs of myocardial stress, renal function, and underlying causes.
    - **Suggested Tests:**
        - **NT-proBNP:** A key biomarker for heart failure; elevated levels are highly indicative of cardiac strain.
        - **Cardiac Enzymes (Troponin I/T):** To rule out an acute coronary syndrome (ACS) as a precipitating factor.
        - **Full Blood Count (FBC):** To check for anemia (which can worsen heart failure) or infection.
        - **Renal Profile (U&E, Creatinine):** To assess kidney function, which is critical for fluid management and medication dosing.
        - **Liver Function Test (LFT):** To check for liver congestion.
        - **HbA1c & Fasting Blood Glucose:** To assess her diabetes control.
- **2. Imaging:**
    - **Aim:** To confirm cardiomegaly, assess for pulmonary edema, and evaluate cardiac function.
    - **Suggested Tests:**
        - **Chest X-Ray (CXR):** To show cardiomegaly, vascular congestion, and pleural effusions.
        - **Echocardiogram:** The gold standard to assess cardiac function, including **ejection fraction (EF)**, chamber sizes, and valvular function. This helps to classify the type of heart failure (e.g., HFrEF or HFpEF).
- **3. Electrocardiogram (ECG):**
    - **Aim:** To identify arrhythmias, signs of ischemia, or chamber hypertrophy.
    - **Suggested Test:**
        - **ECG:** May show left ventricular hypertrophy or an underlying rhythm disturbance.

6. FINAL DIAGNOSIS

Based on the clinical presentation and likely investigation findings, the final diagnosis is **Acute Decompensated Congestive Heart Failure (ADHF)**, most likely with a reduced ejection fraction (HFrEF) secondary to her long-standing hypertension. The symptoms of fluid overload, including dyspnea, orthopnea, and peripheral edema, are a direct result of the heart's inability to pump blood effectively.

7. MANAGEMENT

A. Immediate/Acute Management

- **Oxygen Therapy:** Administer oxygen to maintain SpO_2 >94% and relieve dyspnea.
- **Diuretics:** Administer a loop diuretic like **Furosemide** intravenously to reduce fluid overload. This is the cornerstone of acute management.
- **Vasodilators:** Consider using **Nitroglycerin** to reduce both preload and afterload, which can improve cardiac output.
- **Monitoring:** Continuous monitoring of vital signs, fluid balance (daily weight, input/output chart), and oxygen saturation.

B. Long-Term Management

- **Optimize Medications:**
    - **Beta-blockers (e.g., Bisoprolol):** Start at a low dose and titrate slowly once the patient is stable to improve heart function and reduce mortality.
    - **ACE Inhibitors (e.g., Ramipril) or ARBs:** Continue her ramipril, as these are essential for long-term management of HFrEF.
    - **Mineralocorticoid Receptor Antagonists (e.g., Spironolactone):** Add if EF remains low and the patient's renal function allows.
- **Lifestyle Modifications:**
    - **Salt and Fluid Restriction:** Counsel the patient on a low-salt diet and fluid intake limits to prevent fluid overload.
    - **Physical Activity:** Advise on a gradual increase in activity, and refer for cardiac rehabilitation.
- **Patient Education:** Educate the patient and her daughter on recognizing early symptoms of decompensation and the importance of medication and dietary compliance.

8.0 PATIENT PROGRESS

INSERT DAILY PROGRESS IF ANY NOTED

Day x of admission	
Day x of admission (post op)	

9. 8. LEARNING ISSUES AND DISCUSSION

1. Pathophysiology of Congestive Heart Failure Madam S.H.M's case is a classic example of heart failure secondary to **chronic hypertension**. Long-standing, uncontrolled hypertension forces the heart to pump against increased resistance (afterload), leading to **left ventricular hypertrophy (LVH)**. Initially, this is a compensatory mechanism to maintain cardiac output, but over time, it becomes maladaptive, leading to structural and functional changes in the heart. This eventually results in the inability of the ventricle to fill properly (diastolic dysfunction) or to pump blood out effectively (systolic dysfunction), leading to a reduced ejection fraction and the clinical signs of **congestive heart failure**.

2. Clinical Manifestations of ADHF Her symptoms of shortness of breath, orthopnea, and PND are due to **pulmonary congestion**. The failing left ventricle cannot pump blood forward effectively, causing blood to back up into the pulmonary circulation. This increases pressure in the lung capillaries, leading to fluid extravasation into the interstitial spaces and alveoli, a condition known as **pulmonary edema**. The **S3 gallop** on auscultation is an important sign of fluid overload and is caused by the rapid filling of a non-compliant ventricle.

3. Classification of Heart Failure Heart failure is classified based on the **ejection fraction (EF)**, a measure of how much blood is pumped out with each contraction:

- **Heart Failure with Reduced Ejection Fraction (HFrEF):** EF < 40%. This is often due to conditions like ischemic heart disease or chronic hypertension.
- **Heart Failure with Preserved Ejection Fraction (HFpEF):** EF > 50%. This is more common in elderly women with hypertension.

Given her long-standing hypertension and the signs of LVH (displaced apex beat), her condition is most likely **HFrEF**. The diagnosis of HFrEF guides the choice of long-term medications, as ACE inhibitors, beta-blockers, and mineralocorticoid receptor antagonists have been shown to improve outcomes in this group.

REFERENCE

1. Kasper, D. L., Fauci, A. S., Hauser, S. L., Longo, D. L., Jameson, J. L., & Loscalzo, J. (2018). Harrison's Principles of Internal Medicine (19th ed.). McGraw-Hill.

2. Kumar, P., & Clark, M. (2017). Kumar and Clark's Clinical Medicine (9th ed.). Elsevier.

3. Colledge, N. R., Walker, B. R., Ralston, S. H., & Penman, I. D. (2021). Davidson's Principles and Practice of Medicine (22nd ed.). Elsevier.

4. Talley, N., & O'Connor, S. (2017). Clinical Examination (7th ed.). Elsevier.

5. Longmore, M., Wilkinson, J., Baldwin, A., & Wallin, E. (2014). Oxford Handbook of Clinical Medicine (9th ed.). Oxford University Press.

APPENDICES

- Add if any

PAEDIATRICS CASE WRITE-UP

PATIENT'S DEMOGRAPHIC DATA

- **Name:** A.A
- **Age:** 4 years old
- **Gender:** Female
- **Race:** Malay
- **Address:** Taman Cempaka, Petaling Jaya
- **Registration number:** PJ00000000
- **Date of admission:** 05/09/2024
- **Date of clerking:** 06/09/2024
- **Informant:** Patient's father

HISTORY TAKING

Chief Complaint Aisyah, a 4-year-old Malay girl, was admitted for a 4-day history of high-grade fever, body aches, and a rash. This history was taken from her father.

History of Presenting Illness (HOPI)

The patient was apparently well until 4 days prior to admission when she developed a **high-grade fever** of up to 39.5°C. The fever was intermittent, spiking mainly in the evening, and was partially relieved by paracetamol. It was associated with **headaches** and a feeling of **general malaise**.

One day after the fever started, she developed **body aches** and **joint pains**, which made her reluctant to walk. She also had an episode of **vomiting** (non-bloody, non-bilious) and **poor appetite**. The father also noticed that her gums bled slightly when she brushed her teeth. On the third day of her illness, a **maculopapular rash** appeared on her body, starting on her chest and spreading to her face and limbs. The rash was not itchy.

On the day of admission, her fever had subsided (**defervescence**), but her symptoms of body aches and weakness persisted. She was lethargic and her appetite was very poor. Her father was concerned and brought her to the hospital. There were no reports of abdominal pain, diarrhea, or shortness of breath.

Systemic Review

- **General:** Lethargic, pale, no chill or rigors. No sick contact reported.
- **Respiratory System:** No cough, no rapid or noisy breathing.
- **Central Nervous System:** No syncope, dizziness, or seizures. Headaches were present during the fever period.
- **Haematology:** Pale, lethargic, no easy bruising or gum bleeding other than what was noticed during tooth brushing.
- **Cardiovascular System:** No cyanosis, no chest pain, no palpitations.
- **Gastrointestinal System:** Poor appetite, one episode of vomiting, no abdominal pain, no diarrhea.
- **Genitourinary System:** No dysuria, no change in urine frequency, no hematuria.
- **Musculoskeletal System:** Myalgia and joint pain.

- **Dermatology:** A non-pruritic, maculopapular rash was present on the chest, face, and limbs.

Antenatal, Birth, and Postnatal History

- **Antenatal:** Mother is P1A0, 30 years old, attended routine antenatal check-ups with no complications.
- **Birth:** Full-term, spontaneous vaginal delivery. Birth weight 3.0 kg. No complications.
- **Postnatal:** No neonatal jaundice, no other issues.

Developmental History

- Development is normal for her age. She can walk, run, and communicate in full sentences. She can play with other children and draw simple figures.

Immunisation History

- Immunisations are up-to-date according to the National Immunisation Program.

Nutritional History

- She is on a regular diet. Appetite has been poor for the past 4 days.

Past Medical and Surgical History

- No known medical illnesses or past hospitalizations.

Drug and Allergic History

- No significant drug history. No known drug or food allergies.

Family and Social History

- The patient lives with her parents in a landed house. The father is an engineer, and the mother is a teacher. They have no other children. There has been an ongoing Dengue outbreak in their residential area.
- No family history of chronic diseases or bleeding disorders.

PHYSICAL EXAMINATION

Growth Chart

- The patient's weight is 16 kg (at the 50th percentile) and her height is 100 cm (at the 50th percentile). Her growth is normal for her age.

General Examination

- The patient is conscious, alert, and cooperative. She appears lethargic and pale. No respiratory distress.
- **Vital Signs:**
  - **BP:** 90/60 mmHg
  - **HR:** 110 beats/min, regular, weak volume
  - **RR:** 20 breaths/min
  - **Temp:** 36.8°C (defervesced)
  - **SpO_2:** 99% on room air
- **General Inspection:** Pale, no cyanosis, no visible dysmorphic features.
- **Hands:** Cold, clammy. Capillary refill time is 3 seconds. No clubbing, no peripheral cyanosis.
- **Eyes:** Conjunctival pallor noted.
- **Mouth:** Mucous membranes are dry.
- **Skin:** Maculopapular rash on the trunk and limbs. No petechiae or ecchymoses are visible. A **positive tourniquet test** was performed (15 petechiae per square inch).

Systemic Examination

- **Cardiovascular:** S1S2 heard, no murmurs or added sounds.
- **Respiratory:** Equal air entry bilaterally, no crepitations or rhonchi.
- **Abdominal:** Soft, non-tender. The liver is palpable 2 cm below the costal margin. The spleen is not palpable.

PROVISIONAL DIAGNOSIS

Dengue Fever with Warning Signs

- **Supporting Points:**
  - **Classic symptoms:** High-grade fever, headaches, body aches, joint pain, and a maculopapular rash.
  - **Warning signs:** Signs of **plasma leakage** and bleeding such as increased hemoconcentration, elevated hematocrit, and mild spontaneous bleeding (gum bleeding). The presence of hepatomegaly and a positive tourniquet test also indicate increased vascular permeability and are classified as warning signs.
  - **Epidemiological link:** The patient lives in an area with a reported Dengue outbreak.
  - **Phases of Dengue:** The patient's current presentation aligns with the **critical phase** of Dengue, where the fever has subsided but the risk of plasma leakage and shock is highest.

DIFFERENTIAL DIAGNOSIS

Diagnosis	Point Supporting	Point Against
Measles	Fever, rash, and malaise.	The rash in measles is typically maculopapular and confluent but is often preceded by Koplik's spots (buccal lesions), which were absent. There is also typically a cough and conjunctivitis, which were not reported.
Chikungunya	High fever, severe joint pain (arthralgia).	The rash is typically non-pruritic and petechial, but can be maculopapular. The joint pain is often more severe and debilitating, and the illness is not typically associated with a critical phase of plasma leakage.
Typhoid Fever	High-grade fever, malaise, and poor appetite.	The fever is typically sustained and non-remitting. The rash (rose spots) is less common and the illness is not characterized by a critical phase of plasma leakage or a positive tourniquet test.
Leptospirosis	High-grade fever, myalgia, and headache.	This disease is more common in rural areas and is associated with contact with contaminated water or animal urine. It is typically not associated with a rash or plasma leakage.

INVESTIGATIONS

- **Full Blood Count (FBC):** To check for **leukopenia** (low white blood cells) and **thrombocytopenia** (low platelets), which are characteristic of Dengue.
- **Dengue Serology (NS1 antigen):** To confirm acute Dengue infection. NS1 antigen is detectable in the first few days of the illness, which is when the patient was admitted.
- **Liver Function Test (LFT):** To assess for liver involvement (e.g., elevated AST/ALT), which is common in Dengue.
- **Renal Profile (Urea & Electrolytes):** To assess for dehydration and kidney function.
- **Tourniquet Test:** To assess capillary fragility (already done and positive).
- **Chest X-Ray (CXR):** To check for pleural effusions (a sign of plasma leakage).
- **Ultrasound of Abdomen:** To check for ascites (fluid in the abdomen) and hepatomegaly, which are also signs of plasma leakage.

FINAL DIAGNOSIS

Dengue Fever with Warning Signs

DISCUSSION & LEARNING ISSUES

1. Phases of Dengue Fever Dengue fever has three clinical phases:

- **Febrile Phase (Day 1-4):** Characterized by high fever, headache, retro-orbital pain, myalgia, and a general feeling of malaise.
- **Critical Phase (Day 4-6):** The patient's fever drops (defervescence). This is when the risk of **plasma leakage** is highest. Fluids from the blood vessels leak into the surrounding tissues, leading to signs like pleural effusion, ascites, and hemoconcentration (rise in hematocrit). **Warning signs** appear during this phase, including persistent vomiting, severe abdominal pain, and lethargy.
- **Recovery Phase (Day 7 onwards):** The patient's condition improves, and fluid is reabsorbed. This is characterized by a "re-challenge" rash.

2. Pathophysiology of Dengue with Warning Signs The patient's condition progressed to the critical phase, indicated by the resolution of fever and the appearance of warning signs. The key pathophysiological event in this phase is **increased vascular permeability**, caused by the release of cytokines. This leads to the leakage of plasma from the intravascular to the extravascular space. This leakage results in **hemoconcentration** (high hematocrit) and, if severe, can lead to **Dengue shock syndrome (DSS)**. The platelet count drops (**thrombocytopenia**), which, combined with capillary fragility, leads to bleeding manifestations. The elevated hematocrit and the positive tourniquet test in this patient are clinical signs of plasma leakage.

3. Management Plan The management of Dengue is primarily **supportive**.

- **Monitoring:** The patient needs close monitoring of vital signs, fluid intake and output, and serial monitoring of FBC and hematocrit.
- **Fluid Therapy:** Since the patient is in the critical phase with signs of plasma leakage, careful **fluid resuscitation with** crystalloids is essential.
- **Symptomatic Management:** Paracetamol can be given for fever and pain, but **NSAIDs (like Ibuprofen)** should be avoided as they can increase the risk of bleeding.
- **Discharge Criteria:** The patient can be discharged once they are in the recovery phase and have stable vital signs, a normal hematocrit, and a rising platelet count.

REFERENCES

- Nelson Essentials of Pediatrics, 9th Edition, Karen Marcdante, Robert Kliegman, Chapter 150, Dengue Fever, Pp 550-554.
- Illustrated Textbook of Paediatrics, 6th Edition, Tom Lissauer, Will Carroll, Chapter 27, Infectious Diseases, Pp 445-449.
- Paediatric Protocols For Malaysian Hospitals, 4th Edition, Hussain Imam, Hishamshah, Ng Hoog, Terrence Thomas, Chapter 12, Dengue and Dengue Haemorrhagic Fever, Pp 70-74.

APPENDICES (if any)

LIST OF ABBREVIATION

OBSTETRICS

Patient's Data

- **Name:** Puan A
- **Age:** 29 years
- **Race:** Malay
- **Marital Status:** Married
- **Occupation:** Teacher
- **Address:** Lives in a double-storey house, 30 minutes away from the hospital
- **Date of Admission:** Today

Gravida: 2

Parity: 1

LMP: 01/04/2024

EDD: 08/01/2025 (based on LMP)

POG: 24 weeks + 4 days

Chief Complaint

Referred for further management of newly diagnosed gestational diabetes mellitus (GDM) with an elevated oral glucose tolerance test (OGTT) result.

History of Present Illness (HOPI)

Puan A, a 29-year-old Malay lady, gravida 2, para 1, was seen at the antenatal clinic today for her routine follow-up. A routine **oral glucose tolerance test (OGTT)** was performed at **24 weeks of gestation**, and the results were elevated: fasting glucose 5.5 mmol/L, 2-hour post-glucose 9.1 mmol/L. She was immediately referred to the hospital for further management.

She denies any symptoms of hyperglycemia, such as **polyuria** (increased urination), **polydipsia** (increased thirst), or **polyphagia** (increased appetite). She reports normal fetal movement. She denies any per vaginal bleeding, leaking liquor, or any signs of infection.

History of Presenting Pregnancy

- **Planned:** Yes
- **Wanted:** Yes
- **LMP:** 01/04/2024 (certain)
- **Pregnancy Confirmed:** At 8 weeks of amenorrhea at her local clinic (KK).

Antenatal Booking

- **When:** 8 weeks of gestation at KK Gombak.
- **Investigations:** Hb normal, blood group A+, Rhesus positive, VDRL negative, HIV negative.
- **Supplements:** Obimin, folic acid.

- **Compliance:** Good, no side effects.

Progress of Pregnancy

- **1st Trimester:** No morning sickness or other issues.
- **2nd Trimester:** Anomaly scan at 20 weeks was normal.
- **Current Problem:** Gestational diabetes mellitus (GDM) diagnosed via OGTT.

Menstrual & Obstetric History

- **Menstrual History:** Menarche at 13 years old. Regular cycles (28-30 days), 5 days duration, normal flow.
- **Obstetric History:**
    - **G1 P1 (2020):** Delivered a healthy baby boy at term (40 weeks) via spontaneous vaginal delivery. Birth weight 3.2 kg. No complications during that pregnancy or delivery. No history of GDM in the previous pregnancy.

Gynaecology History

- No history of abnormal bleeding or discharge.
- No contraception history.
- No Pap smear or breast screening done.

Systemic Review

- **CVS:** No chest pain, palpitations, or syncope.
- **RS:** No dyspnea or cough.
- **GIT:** No constipation or diarrhea.
- **CNS:** No headaches, blurring of vision.
- **Haematology:** No bleeding tendency.

Past Medical & Surgical History

- **Medical:** No hypertension, diabetes, asthma, or other chronic illnesses.
- **Surgical:** None.
- **Allergies:** No known drug, food, or environmental allergies.

Drug & Social History

- **Current Medications:** Obimin, folic acid.
- **Family History:** Father has Type 2 DM.
- **Marital & Social History:** Married for 5 years, lives with husband and one child. Non-smoker and non-alcoholic. Stable financially. Diet consists of a typical Malaysian diet.

Physical Examination

- **General:** Alert, oriented, comfortable, no distress.
- **Vital Signs:** BP 120/78 mmHg, Pulse 72 bpm, RR 16/min, Temp 36.5°C, SpO_2 99% on room air.
- **Abdomen:**

- **SFH:** 26 cm (corresponds to 24 weeks).
- **Palpation:** Single fetus, longitudinal lie, cephalic presentation.
- **FHS:** 140 bpm, regular.

Provisional Diagnosis

Gestational Diabetes Mellitus (GDM)

- **Supporting Points:**
  - Elevated **OGTT** results (fasting 5.5 mmol/L, 2-hour 9.1 mmol/L) at **24 weeks of gestation**.
  - This is a **new-onset glucose intolerance** detected for the first time during pregnancy.
  - **Risk Factors:** Family history of Type 2 DM (father) and a history of a previous large-for-gestational-age baby (although her first baby was a normal 3.2 kg).

Differential Diagnosis	Supporting Points	Points Against
Pre-existing (Type 2) Diabetes Mellitus	The patient has elevated blood glucose readings. Her father has a history of T2DM.	No history of diabetes before pregnancy. Her blood work and glucose screening at her initial booking visit (8 weeks) were normal.
Hyperglycemia due to other conditions	Could be caused by a concurrent illness or medication.	No signs of a concurrent illness. The patient's only medications are routine prenatal supplements.

Investigations

1. **Confirm Diagnosis:** The diagnosis is confirmed by the OGTT results, so no further tests are needed to confirm GDM itself.
2. **Maternal Investigations:**
   - **HbA1c:** To determine if hyperglycemia was present before the pregnancy (ruling out pre-existing diabetes).
   - **Urine Ketone Check:** To monitor for ketosis.
   - **Renal Profile & LFTs:** To assess for any end-organ damage.
3. **Fetal Investigations:**
   - **Ultrasound Scan:** To monitor fetal growth, specifically for **macrosomia** (large baby) or polyhydramnios (excess amniotic fluid).
   - **Fetal Kick Chart:** To monitor fetal well-being.
   - **Cardiotocography (CTG):** To assess fetal well-being in the third trimester.

Management Plan

The management of GDM involves a multi-pronged approach to control blood glucose levels and ensure a healthy pregnancy outcome for both mother and baby.

1. **Dietary and Lifestyle Modification:**
    - Referral to a dietitian for a **structured meal plan** to manage carbohydrate intake.
    - Advise on regular, **moderate exercise**.
2. **Blood Glucose Monitoring:**
    - Teach the patient to perform **self-monitoring of blood glucose (SMBG)** multiple times a day (fasting and 2-hour post-meals).
3. **Pharmacological Management:**
    - If diet and exercise fail to achieve target blood glucose levels, start **pharmacological therapy** with oral hypoglycemic agents (e.g., metformin) or insulin.
4. **Fetal Monitoring:**
    - Regular antenatal visits with serial ultrasounds to monitor fetal growth.
    - Discuss the importance of a **fetal kick chart**.
5. **Delivery Planning:**
    - Discuss the potential need for **induction of labor** if blood glucose is poorly controlled or if there is suspected macrosomia.
    - Counsel on the risks of GDM, including the need for future screening for Type 2 Diabetes Mellitus.

DISCUSSION

Pathophysiology of GDM

GDM is a condition where glucose intolerance begins or is first recognized during pregnancy. The underlying mechanism is a state of **insulin resistance**, which normally increases throughout pregnancy due to the secretion of hormones like human placental lactogen (HPL), placental growth hormone, and cortisol from the placenta. These hormones ensure a constant supply of glucose to the growing fetus. In some women, this natural insulin resistance is exaggerated, and their pancreas cannot produce enough extra insulin to overcome it, leading to hyperglycemia.

The elevated blood glucose levels in the mother cross the placenta to the fetus, which then triggers the fetal pancreas to produce more insulin (fetal hyperinsulinemia). This leads to increased fetal growth and fat deposition, a condition known as **macrosomia**.

Risk and Complications

Uncontrolled GDM poses risks to both the mother and the fetus.

Maternal Risks:

- **Preeclampsia:** GDM increases the risk of developing preeclampsia.
- **Polyhydramnios:** Excessive amniotic fluid, which can lead to preterm labor.
- **Complications during Delivery:** Increased risk of operative delivery (e.g., C-section) due to macrosomia.
- **Future Diabetes:** Women with GDM have a significantly higher risk of developing Type 2 Diabetes Mellitus later in life.

Fetal Risks:

- **Macrosomia:** A large baby, which can lead to birth trauma (e.g., shoulder dystocia).
- **Neonatal Hypoglycemia:** After birth, the baby's pancreas continues to produce high levels of insulin, leading to a rapid drop in blood sugar.
- **Respiratory Distress Syndrome:** The high insulin levels can delay fetal lung maturation.
- **Childhood Obesity and Diabetes:** Offspring of mothers with GDM have a higher risk of developing obesity and Type 2 diabetes later in life.

Management Principles

The primary goal of GDM management is to **normalize maternal blood glucose levels** to prevent these complications. The management plan for Puan Aishah should be based on a stepped approach:

1. **Diet and Exercise:** This is the cornerstone of management. Referral to a dietitian for a specific meal plan to control carbohydrate intake is crucial.
2. **Blood Glucose Monitoring:** The patient must be taught how to perform **self-monitoring of blood glucose (SMBG)** at home to track her progress and inform treatment decisions.
3. **Pharmacological Therapy:** If blood glucose targets are not met with diet and exercise alone, medication will be initiated. The first-line oral agent is **metformin**, as it is safe in pregnancy. If oral agents are ineffective, **insulin therapy** will be started.

4. **Fetal and Maternal Surveillance:** Regular antenatal follow-ups are essential to monitor both mother and fetus. This includes serial ultrasounds to assess fetal growth (specifically for macrosomia) and amniotic fluid volume, as well as kick counts and potentially Cardiotocography (CTG) in the third trimester to monitor fetal well-being.
5. **Postpartum Care:** After delivery, her blood glucose levels should be checked to ensure they have returned to normal. She should be advised to have a routine glucose screen 6-12 weeks postpartum and be counseled on the high lifetime risk of developing Type 2 Diabetes.

REFERENCES

1.

APPENDICES (if any)

LIST OF ABBREVIATION

Gynaecology Case Write-Up

Patient's Data

- **Name:** Puan Z
- **Age:** 62 years
- **Race:** Malay
- **Marital Status:** Widowed
- **Occupation:** Retired Clerk
- **Address:** Lives with her daughter, 15 minutes away from the hospital.
- **Date of Admission:** Today

Chief Complaint

Post-menopausal bleeding for 3 months, with a feeling of a lump in her abdomen.

History of Present Illness (HOPI)

Puan Z, a 62-year-old Malay lady, presented with a 3-month history of **post-menopausal bleeding (PMB)**. Her menopause occurred 10 years ago, at the age of 52. The bleeding started as intermittent spotting, but over the last month, it has become more frequent, requiring the use of one to two pads per day. The blood is described as dark red, with no clots, foul smell, or associated pain.

Concurrently, she has noticed a gradual increase in her abdominal size and a persistent feeling of a **hard lump** in her lower abdomen for the past two months. This is accompanied by a sensation of **early satiety** (feeling full quickly after eating) and a **bloating sensation**. She reports a weight loss of about 5 kg in the past 3 months, despite a good appetite. She denies any pain, nausea, vomiting, or changes in bowel or urinary habits.

Menstrual & Gynaecology History

- **Menstrual History:** Menarche at 14 years old. Regular cycles, 28 days, 5 days duration, with normal flow. Menopause at 52 years old.
- **Gynaecology History:**
    - No history of abnormal vaginal discharge, pelvic inflammatory disease, or sexually transmitted infections.
    - No history of contraception use or hormone replacement therapy (HRT).
    - Last Pap smear was 5 years ago, with a normal result.

Obstetric History

- **Gravida 3 Para 3:** Delivered three healthy children via spontaneous vaginal delivery at term, with no complications. Her last child was born 28 years ago.

Past Medical & Surgical History

- **Medical:** Known case of **Hypertension**, well-controlled with amlodipine. No history of diabetes, asthma, or other chronic illnesses.
- **Surgical:** None.
- **Family History:** Her mother had a history of **breast cancer**. Her sister was diagnosed with **ovarian cancer** at the age of 55.

Drug & Social History

- **Medications:** Amlodipine 5mg daily.
- **Allergies:** No known drug, food, or environmental allergies.
- **Social History:** Widowed for 5 years, lives with her daughter. Non-smoker and non-alcoholic. She is financially stable and leads an active lifestyle.

Physical Examination

- **General:** Alert, conscious, and oriented. Appears well and not in distress.
- **Vital Signs:** BP 130/80 mmHg, Pulse 75 bpm, RR 18/min, Temp 36.6°C.
- **Abdomen:**
    - **Inspection:** Abdomen is visibly distended, especially in the lower half.
    - **Palpation:** A large, firm, irregular mass is palpable in the suprapubic and umbilical region, extending to the right iliac fossa. It is non-tender and non-mobile. There is no shifting dullness.
- **Per Speculum & Bimanual Examination:**
    - **Per Speculum:** Small amount of blood is visible coming from the cervical os. The cervix appears healthy.
    - **Bimanual:** The uterus cannot be palpated separately from the mass. A large, non-tender, irregular pelvic mass is felt in the pouch of Douglas. It is difficult to assess its mobility.

Provisional Diagnosis

Ovarian Cancer (likely advanced)

- **Supporting Points:**
    - **Post-menopausal status** with a palpable pelvic mass.
    - Symptoms of **abdominal bloating**, **early satiety**, and **weight loss**, which are classic features of advanced ovarian cancer.
    - Family history of **breast and ovarian cancer**, which suggests a possible genetic predisposition (e.g., BRCA mutation).
    - The post-menopausal bleeding could be due to hormone production by the tumor or metastatic spread to the uterus.

Differential Diagnoses

Differential Diagnosis	Supporting Points	Points Against
Endometrial Cancer	The patient's chief complaint is post-menopausal bleeding, which is the most common symptom of endometrial cancer.	The presence of a large, palpable pelvic mass, bloating, and early satiety are more classic for ovarian cancer. These symptoms are not typical for early-stage endometrial cancer.
Uterine Leiomyoma (Fibroids)	They can present as a pelvic mass and cause bleeding.	They are highly unlikely to grow or cause symptoms after menopause. Post-menopausal bleeding is not a typical symptom of a fibroid unless the patient is on HRT, which she is not.
Benign Ovarian Cyst	Can be large and palpable and can cause symptoms of abdominal fullness.	The patient's age and post-menopausal status, combined with symptoms like weight loss, bloating, and early satiety, make a benign diagnosis less likely. Her family history is also a strong point for malignancy.

Investigations

1. **Transvaginal Ultrasound (TVS) with Doppler:**
    - To visualize the mass, its size, solid components, and vascularity.
    - To assess the ovaries and uterus.
2. **Tumor Markers:**
    - **CA-125:** This is a key tumor marker for epithelial ovarian cancer.
    - **Other markers** (e.g., CEA, AFP, beta-hCG) may be checked to rule out other types of tumors.
3. **Endometrial Biopsy (Pipelle Sampling):**
    - To rule out co-existing or primary endometrial cancer. This is crucial given the presenting symptom of PMB.
4. **CT Scan (Chest/Abdomen/Pelvis):**
    - To assess the extent of the disease, including lymph node involvement and distant metastases, and to confirm the origin of the mass.
5. **Colonoscopy:**
    - To rule out a primary colorectal malignancy with ovarian metastasis.
6. **Genetic Testing:**
    - Consider **BRCA1/BRCA2** gene testing due to her strong family history of breast and ovarian cancer.

Management

- **Initial:** The immediate priority is to confirm the diagnosis and stage the disease.
- **Surgical:** The definitive treatment will likely involve a **Total Abdominal Hysterectomy with Bilpateral Salpingo-oophorectomy (TAH-BSO)**, and **surgical debulking** (removing as much of the tumor as possible).
- **Adjuvant Therapy:** Depending on the final pathology and stage, she may require **adjuvant chemotherapy** after surgery.
- **Post-Operative Care:** Monitor for post-operative complications and provide appropriate pain management and supportive care

---

REFERENCES

1.

APPENDICES (if any)

LIST OF ABBREVIATION

ORTHOPAEDIC

1. Patient Details

- Registration No.:
- Name: Madam Y
- Age: 62 years old
- Gender: Female
- Ethnicity: Malay
- Occupation: Retired / Homemaker
- Address:
- Ward/Bed:
- Date of admission:
- Date of clerking:
- Informant: Patient herself

2. HISTORY

2.1 Chief Complaint

Madam Y, a 62-year-old Malay woman with no known medical illness, presented with progressive left hip pain over the past 5 years

2.2 History of Presenting Illness

The hip pain initially started as mild and intermittent, without functional limitation. Approximately 6 months ago, a misstep while walking caused pain and swelling in the left thigh. She did not seek formal medical attention and instead received a weekly traditional massage for 2 months, with partial relief.

One month ago, another misstep led to significant worsening of pain. She sought treatment at a Klinik Kesihatan (KK), receiving topical ointment without improvement. She then presented to the hospital, where X-ray imaging revealed features suggestive of osteonecrosis with concern for underlying malignancy.

Currently, the pain is sharp, persistent, and localized to the proximal left thigh/hip. It is mechanical, aggravated by weight-bearing and movement, and partially relieved by rest. Pain score is 10/10 on movement, significantly limiting ambulation and daily activities. She denies radiation to the back or lower limb.

Associated symptoms include fatigue, anorexia, 8 kg unintentional weight loss over 6 months, urinary incontinence, and local inflammatory signs (warmth, redness, swelling). She denies fever, night sweats, numbness, back pain, or bowel incontinence.

History of right hip trauma and surgery at age 22 (following MVA) was uneventful post-operatively, with full functional recovery until recent symptoms.

Systemic Review

- Urinary: Reduced frequency; no bowel complaints
- Respiratory/GI: No cough, dyspnea, vomiting, or abdominal pain
- Neurological: No numbness, weakness, or radiculopathy

Medical History

- No known chronic illnesses (DM, HTN, hyperlipidemia, metabolic bone disease, autoimmune disease, malignancy)

Surgical History

- Right hip surgery at age 22; no other surgical history

Obstetric

- G4P4; first via ELSCS for trauma, remaining SVD

Drug and Allergy

- Not on any long term medication. no steroid, HRT, OCP, or herbal/traditional medications
- No known drug/ food allergy

Family History

- Mother has HTN; strong family history of malignancy (3 of 10 older siblings with cancer: bone, colon, colon)

Social History

- Non-smoker, non-alcoholic; independent in ADLs prior to current symptoms; now uses walking stick for ambulation

3. PHYSICAL EXAMINATION

3.1 General Inspection

- Conscious, alert, oriented (GCS 15/15)
- Cachectic, no pallor
- Not in pain at rest
- Branula on left cubital fossa attached to IV NACL
- No walking aid currently in use
- No surgical prescription chart or medications noted

3.2 LOOK: Local Inspection (Left Hip/Lower Limb)

- Anterior view: No scars, swelling, bruises, or asymmetry; muscle bulk preserved
- Lateral view: No flexion deformity; lumbar lordosis normal
- Posterior view: Gluteal bulk symmetrical; no scars or wasting
- Right lower limb: Healed surgical scar over lateral thigh (~15 cm) and knee joint from prior MVA

3.3 FEEL

- Supine: No warmth or tenderness over left hip joint, greater trochanter, ASIS, PSIS, or femur
- Capillary refill <2 sec
- Dorsalis pedis and posterior tibial pulses palpable bilaterally
- Leg length: No discrepancy (true and apparent)
- **Neurovascular**
    - Sensation intact in all dermatomes
    - Peripheral pulses palpable

3.4 **MOVE**

Left Hip (Active/Passive):

- Flexion: Limited (pain beyond 70–80°)
- Extension: Limited; patient avoids prone
- Abduction: Limited by pain

- Adduction: Limited by pain
- Internal/External Rotation: Significantly restricted and painful

Right Hip
- Full ROM, painless

3.5 **SPECIAL TEST**
- Not performed due to pain and guarding: Trendelenburg, Thomas, and other provocative tests

4. DIAGNOSIS

4.1 Provisional Diagnosis
Left proximal femur lesion, suspicious for malignancy (primary osteosarcoma vs metastatic lesion), with underlying osteonecrosis.

4.2 Differential Diagnosis

Differential	Supporting Points	Points Against
Osteosarcoma (primary)	Persistent progressive hip/thigh pain, radiographic suspicion of bone lesion, unintentional weight loss	Age atypical for primary osteosarcoma (usually <30)
Metastatic bone disease	Progressive pain, cachexia, positive family history of malignancy, radiographic lesion	No known primary malignancy diagnosed yet
Osteonecrosis	Radiographic changes, history of minor trauma, mechanical hip pain	Local inflammatory signs less typical, pain severe
Post-traumatic OA	History of previous missteps causing mild trauma, gradual progression	Rapid worsening and systemic symptoms less typical
Septic arthritis	Pain, swelling, local warmth, redness	No fever, no systemic toxicity, chronic duration >1 month

5. INVESTIGATION
Local Orthopaedic Workup:
1. X-ray Left Hip/Femur: Suggestive of osteonecrosis; concern for malignancy
2. MRI Left Hip: Planned for detailed bone lesion characterization
3. CT Thorax/Abdomen/Pelvis: Planned for metastasis or primary lesion detection

Systemic/Preoperative Workup:
- Full Blood Count (FBC)
- Renal Profile & Liver Function Test (baseline)
- Coagulation Profile (PT, aPTT, INR)
- Blood Group & Crossmatch
- ECG and Echocardiogram (if indicated)

- Chest X-ray
- Urinalysis
- CRP and ESR (baseline inflammatory markers)
- Fasting Blood Sugar/HbA1c

6. MANAGEMENT

Acute/ Symptomatic

1. Pain control:
    - Paracetamol first-line, escalate to NSAIDs if needed
    - Avoid opioids unless pain severe

2. Activity modification:
    - Use walking aid (cane/walker)
    - Avoid weight-bearing if possible

3. Adjunct:
    - Physical therapy for mobility without stressing hip
    - Monitor nutritional status due to cachexia

Definitive Management

- Orthopaedic oncology referral for surgical excision or biopsy
- Multidisciplinary approach (oncology, orthopaedics, radiology)
- Consider total hip replacement if lesion localized and benign or post-oncologic resection

Post-operative / Long-term Care

- Pain monitoring and management
- Early mobilization with physiotherapy
- Wound care and infection monitoring
- Follow-up imaging for recurrence or metastasis
- Nutritional support and rehabilitation

7. DISCUSSION

1. Primary vs Secondary Osteonecrosis / Lesion
    - Primary osteonecrosis can be idiopathic; secondary causes include trauma, corticosteroid use, alcohol, or systemic disease. In this patient, prior trauma and osteonecrotic changes may predispose the hip to degeneration.
    - Suspicion for malignancy arises due to radiographic lesion, cachexia, systemic symptoms, and positive family history of cancer.

2. Mechanical Pain Pattern
    - Pain worsens with movement and weight-bearing, consistent with mechanical/structural bone pathology.
    - Inflammatory causes are less likely due to absence of fever, systemic toxicity, or prolonged stiffness.

3. Impact of Trauma
    - Recent missteps may have exacerbated underlying osteonecrosis or unmasked an early malignant lesion.
    - Differentiating post-traumatic OA vs malignancy requires imaging (MRI, CT) and possibly biopsy.

4. Importance of Imaging
    - Radiographs suggest osteonecrosis and bone lesion.
    - MRI provides better delineation of marrow and soft tissue involvement.
    - CT scans assist in staging and metastasis assessment.

5. Functional Implications

    - Hip ROM significantly limited, impacting ADLs and mobility.
    - Walking aid recommended until definitive management.

6. Red Flags

    - Weight loss, fatigue, local inflammatory signs, and strong family history of malignancy highlight need for urgent workup and possible oncological intervention.

REFERENCES

1.

APPENDICES (if any)

LIST OF ABBREVIATION

1.0 PATIENTS DEMOGRAPHIC DATA

- Name: M
- Hosp Reg No: XXX
- Age: 32 years old
- Sex: Male
- Ethnic: Malay
- Religion: Islam
- Occupation: Security Guard (currently unemployed)
- Address: Melaka. Lives with mother and younger brother.
- Informant: Patient's mother
- Reliability: Fair reliability (due to poor insight)
- Date of admission: 11 November 2024
- Status of admission: Involuntary under Form 2 (due to aggression towards family)
- Date of clerking: 13 November 2024
- Psychiatry status: Known case of Schizophrenia (diagnosed 3 years ago, poor compliance to medication)

2.0 HISTORY

2.1 Chief Complaint

The patient was admitted to the psychiatric ward after allegedly attempting to assault his younger brother with a stick while shouting that "he is a spy."

2.2 History of Presenting Illness

According to the patient's mother, his illness started around 3 years ago when he began to behave oddly, often talking and laughing by himself. He would spend long hours in his room whispering and appearing suspicious of family members. He was first diagnosed with Schizophrenia in 2021 and was started on antipsychotics (T. Risperidone 2mg ON). However, compliance has been poor as he frequently defaulted follow-up, claiming "the doctors are trying to poison him."

For the current episode, symptoms worsened about 1 month ago after he stopped medication completely. He started saying that his younger brother was "working with outsiders to monitor him," frequently accusing him of planting cameras in the house. Patient also reported hearing voices commenting on his actions, such as "He is useless," or "They are watching you." These voices are second person in nature, derogatory, and occur daily. He admitted to seeing "dark shadows" in the house, especially at night.

His sleep has been markedly reduced, often staying awake until morning pacing around the house. Appetite is poor, and he appears neglectful of hygiene (not bathing for days, wearing dirty clothes).

On the day of admission, he suddenly became aggressive after accusing his younger brother

of spying. He shouted, picked up a stick, and attempted to hit him. Family members intervened, and he was brought to ED by police assistance.

He denies any suicidal ideation or attempts. No depressive symptoms noted. No manic symptoms such as pressured speech, flight of ideas, or grandiosity. No obsessive-compulsive symptoms.

2.3 Past psychiatry history

- Diagnosed with Schizophrenia in 2021, admitted once before for acute psychosis.
- Poor medication compliance.
- No history of ECT.

2.4 Past medical & surgical history

- No known medical illness
- No past surgery

2.5 Drug history

- Previously prescribed T. Risperidone 2mg ON, T. Trihexyphenidyl 2mg ON.
- The patient has defaulted medication for 1 month.
- Denies use of any other medications.

2.6 Allergy

He has no known food, environmental or drugs allergy.

2.7 Family history

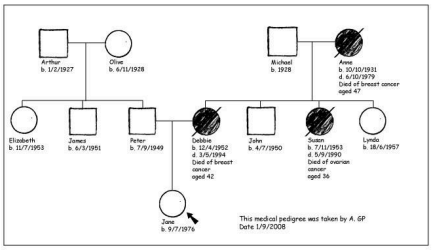

(*example)*

- No family history of psychiatric illness.
- Both parents have u/l hypertension, otherwise well.
- No history of suicide, addiction, or major mental illness in family.

Mr. M has a good relationship with siblings and mother. He is closest with his sister as he thinks that she understands his condition better because she previously had postpartum depression. Sister is currently fully recovered however she has bad perception on antidepressant and will advise the patient to not take his medication. Beside this, there is no other history of mental illness, suicide or addiction in the family.

He is Married and blessed with 2 children who are 3 years old girl and 5 month old boy. Both have normal developmental milestones and have no hospital admission or any known illness.

2.8 Personal History

Birth: Patient is unsure of his birth history.

Childhood: Normal birth and developmental milestones. No history of febrile seizures, CNS infections, or head trauma. No neurotic traits in childhood.

Education: Completed SPM with average performance. Described as quiet but had some friends.

Occupation: Worked as a security guard until 2022 when he lost his job due to frequent absenteeism and poor performance. Since then, unemployed and financially dependent on mother.

Relationship/Marital/Sexual: Single, never married. No known relationships. No abnormal sexual behaviour reported.

Social: Limited social network, isolated, prefers to stay at home.

2.9 Smoking, Alcohol, or Drugs history:

- Denies alcohol, tobacco, or illicit drugs.
- Urine drug screen negative on admission.

2.10 Forensic history

- No past legal issues.
- The current episode involved aggression towards a family requiring police escort to hospital.

2.11 Premorbid personality

Prior to his illness, the patient was known to be extroverted and able to communicate well with hotel guests. He was also seen as a dependable person by his friends, and family members. He loved to play sports like football and basketball and used to enjoy playing with his children and used to always spend time with them. He was described as emotionally steady and even-tempered, rarely displaying anger or irritability. However he does have a history of physically abusing his now wife once prior to their marriage but the patient refuses to elaborate further. He practised islam, pray 5 times a day and recites Al-Quran occasionally. His faith has prevented him from commiting suicide many time before. Interpersonal interactions were always polite and respectful and never displayed a strong tendency toward

imaginative thinking or fantasy

3. MENTAL STATUS EXAMINATION

3.1 Appearance & Behaviour	The patient was examined as a young adult Malay male, thin build, appearing his stated age. He was seated on the ward bench wearing hospital attire, hair unkempt, and with poor personal hygiene (unkempt nails, mild body odour). He was restless at times, looking around the ward suspiciously, and occasionally muttering to himself. Rapport was difficult to establish as he was guarded and suspicious. Eye contact was poor, often staring sideways as if listening to something. No abnormal involuntary movements noted.
3.1 Speech	Speech was spontaneous but reduced in amount. Tone and volume were low, with occasional pauses suggestive of thought blocking. Coherence was fair but content was dominated by persecutory ideas. No pressure of speech or dysprosody noted.
3.2 Mood and affect	Subjectively, the patient described his mood as "ok." Objectively, affect was blunted, restricted in range, and incongruent to the context of conversation (appeared suspicious and anxious while denying distress). Affect showed limited reactivity.
3.3 Thought	● Form: No flight of ideas or loosening of associations. Occasional thought blocking observed. ● Stream: Normal pace but interrupted by pauses. ● Content: Presence of persecutory delusions (believes brother is spying on him and people are monitoring him). Also had ideas of reference (believes neighbours are talking about him). No thought possession phenomenon (insertion, withdrawal, broadcasting) elicited during the interview. No suicidal ideation, but history of homicidal ideation towards brother was noted.
3.4 Perceptions	Patient reported second-person auditory hallucinations — voices commenting and criticizing him ("He is useless," "They are watching you"). No visual, tactile, or olfactory hallucinations elicited during interview.
3.5 Cognition	
General	Alert and cooperative
Orientation	Oriented to time, place and person
Attention	● Able to perform serial 3s but failed serial 7s (distracted by internal stimuli). Digit span forward intact (6 digits), backward limited (3 digits).
Language	Patient was able to name random object shown and able to repeat word, phrase and sentences given to him
Calculation	Patient was able to do simple division and subtraction but unable to do multi digit division and subtraction.

Right hemisphere function	Patient able to draw a clock-face correctly
Abstraction (Visuospatial)	He was able to interpret given proverb and tell similarities between an apple and a banana correctly (both are fruits) and cat and dog (both are animal)
Memory	● Immediate: Intact (able to recall 3 objects immediately). ● Recent: Impaired (unable to recall 2 out of 3 objects after 5 minutes). ● Remote: Intact (remembers school details and family history).
Praxis	Can clap hands, mimic teeth brushing action and also wave goodbye
3.6 Judgement	Personal: Poor, as he has been non-compliant to treatment and does not see the need for medication. Social: Impaired, as evidenced by recent aggressive behaviour towards his brother due to delusional beliefs. Test judgement: When asked what he would do if he smelled smoke in a crowded cinema, he vaguely replied, "I will find who is causing it," instead of evacuating or calling for help.
3.7 Insight	Poor insight as the patient denies having a mental illness, attributing his admission to "family trying to harm me." Does not accept the need for treatment. Lacks awareness of the consequences of his behaviour.

4. PHYSICAL EXAMINATION

4.1 General Inspection

On general inspection, the patient was a thin-built male, lying comfortably on his bed. He was conscious, alert, and well oriented to time, place, and person. He was not tachypneic, not in respiratory distress, and not in pain (pain score 0/10). There was no gross deformity noted and no peripheral attachments were seen.

4.2 Vital sign (normal)

- Blood pressure: 128/82mmHg
- Pulse rate: 82 beats per minute (good volume and regularly regular rhythm)
- Respiratory rate: 17 breath per minute
- Temperature: 36.1 degree Celsius
- SpO2: 99% under RA

4.3 General examination

- Upper limb: Hands were pink, warm and moist, with no excessive sweating. No clubbing, no peripheral cyanosis, and capillary refill time <2 seconds. No track marks/needle marks seen.
- Head: No scars, swellings, tenderness, or bruises.

- Eyes: No scleral jaundice, conjunctival pallor, conjunctival hemorrhage, or exophthalmos.
- Mouth: Good oral hygiene, moist mucosa, no central cyanosis. Dentition intact, no tongue fasciculations.
- Neck: No masses, no bruising, no spinal tenderness.
- Chest: Well-healed scars consistent with old chickenpox lesions. No chest wall deformities.
- Back: No scars, no bruises, no spinal tenderness.
- Lower limb: No edema, no bruises, no joint tenderness. Well-healed surgical scar noted over the right ankle.

4.4 Systemic examination

- Neurological: GCS 15/15. Pupils 2 mm, equal and reactive to light. Cranial nerves grossly intact. Normal tone and power in all limbs. Reflexes normal, No rigidity, tremor, or involuntary movement noted. Gait were steady.
- Thyroid: No bruit heard on auscultation.
- Cardiovascular: S1 and S2 present, no murmurs or added sounds. Peripheral pulses are equal and regular.
- Respiratory: Normal vesicular breath sounds bilaterally, no added sounds.
- Abdomen: Soft, non-tender, no hepatosplenomegaly, no masses. Bowel sounds present.

5. SUMMARY

A.R. is a 32-year-old Malay male, single, unemployed security guard, with a known history of schizophrenia diagnosed 3 years ago, admitted involuntarily under Form 2 on 11th November 2024 due to aggression towards family. He has poor compliance to antipsychotic medication, with a background of deteriorating functioning and increasing hostility at home. He lives with his mother and younger brother.

On mental status examination, he appeared thin, disheveled but cooperative, with poor eye contact. Speech was spontaneous and coherent but reduced in amount. His affect was constricted and incongruent to his self-reported euthymic mood, appearing sad. He did not demonstrate formal thought disorder, but admitted to ongoing suicidal ideation without a specific plan. There were no delusions or hallucinations elicited. Cognition was grossly intact with some deficits in attention, calculation, and recent memory. Judgment was preserved, and he demonstrated good insight, attributing his illness to substance use and accepting the need for treatment.

On physical examination, he was alert and oriented, with stable vital signs. He was thin but not malnourished. No self-harm scars, no stigmata of substance use, and no neurological deficits or extrapyramidal side effects were noted. Systemic examinations were unremarkable.

6. PROBLEM LIST

a) Schizophrenia, poorly controlled due to poor compliance with medication.
b) Risk of aggression towards family leading to involuntary admission under Form 2.
c) Suicide risk active suicidal ideation without specific plan, with previous history of attempt.
d) Poor insight into illness despite partial acknowledgement, compliance has been inconsistent.
e) Adherence issue with antipsychotic treatment contributing to relapse and readmission.
f) Psychosocial stressors: unemployment, financial difficulty, and strained family dynamics.
g) Functional decline: currently unemployed, social withdrawal, and impaired daily functioning.
h) Caregiver burden: mother and younger brother struggling with aggression and safety concerns.
i) Risk of substance use contribution: as patient attributes illness to substance use (needs further clarification).
j) Stigma and family misperception: negative attitude towards psychiatric medication and illness, limiting support

7. PROVISIONAL DIAGNOSIS

Major Depressive Disorder (MDD), Severe with suicidal risk

The patient presents with a history of depression with symptoms such as persistent low mood, anhedonia, sleep disturbances, weight loss, poor concentration, and feelings of worthlessness and hopelessness. These symptoms lasted for a prominent duration which was since June 2024 and also affected his functionality as he is unable to do any work. Additionally, he reports on multiple suicide thought and attempt in the past indicating a severe depressive episode with high suicidal risk.

8. DIFFERENTIAL DIAGNOSIS

Differential	**Supporting point**	**Point against**
Bipolar II Disorder in depressive phase	● Brief hypomanic-like episode, with elevated mood, increased energy, excessive talking, and job-seeking behaviour lasting for 2 weeks after starting medication ● Mood Variability: Bipolar II Disorder is often marked by episodes of major depression and intermittent hypomanic states, which seems consistent with his cycling of depressive and "happy" episodes.	● The symptoms did not mount to an episode of BMD as it does not fulfil criteria for a hypomanic in DSM-5. ● Elevated mood started with antidepressant intake and resolved once he stopped taking medication, suggesting a possible antidepressant-induced mood shift rather than a true hypomanic episode. ● No history of prior hypomanic episodes before the onset of depression
Substance-Induced Mood Disorder	● History of magic mushroom abuse (psilocybin) for 1 year. ● Symptoms began following cessation of magic mushroom use. ● Magic mushrooms affect serotonin and can induce depressive symptoms during and after use	● This patient's depressive symptoms persisted for several months after stopping substance use ● He has been substance free or 5 month
Mood Disorder Due to Another Medical Condition	● Conditions like hypothyroidism can cause depressive symptoms	● No known medical illness ● No hypothyroid history in the family. ● depressive symptoms are more closely associated with life stressors and substance withdrawal
Adjustment Disorder with Depressed Mood	● Symptoms began following several stressors, including financial difficulties, loss of employment, and conflict with family members	● severity, persistence, and psychotic features of his symptoms ● Suicidal behavior and significant impairment suggest a more severe disorder

9.0 INVESTIGATION (all result obtained from patient investigation chart)

9.1 BIOLOGICAL

Full Blood Count

Aims: Baseline investigation for future comparison and also to rule out medical cause of the symptoms such as:

1) Anaemia by checking Hb level since anaemia can cause fatigue, weakness, cognitive changes, and mood disturbances, which may be mistaken for psychiatric conditions.
2) Infections by checking WBC level because some infections such as urinary tract infections can cause delirium or worsen pre-existing psychiatric conditions.
3) Assess platelet function as antidepressant (SSRI) can alter serotonin level which is required for platelet activation/aggregation and hence SSRI can increase risk of bleeding.

* Patient result were **Normal**

Lipid profile

Aims:-Baseline measurement for future reference and as a guide to decide medications as some antidepressant and cause metabolic changes

-Assessing the patient's cardiovascular risk if there is need for any change in medication.

* Patient result were **Normal**

Liver function test

Aims:

- Baseline before starting a patient on medications to ensure the liver can safely metabolise these drugs and avoid potential drug-induced liver injury since selective serotonin reuptake inhibitors (SSRIs), serotonin-norepinephrine reuptake inhibitors (SNRIs), tricyclic antidepressants (TCAs), and other medications like mirtazapine, are metabolised by the liver.
- Detect any changes in liver function after starting treatment with his previous result
- Rule out any underlying medical cause of the depressive symptoms such as hepatic encephalopathy, chronic liver disease and cirrhosis.

* Patient result were **Normal**

Renal Profile and biochemistry test & Serum electrolyte

Aims:

- To assess patient renal condition as SSRI like sertraline can have negative effect especially in this case as the patient overdose so the effect can be more severe.

- Ensure the kidneys are functioning adequately to handle medications
- Adjust dosages if there is pre-existing kidney dysfunction.
- To check for any electrolyte imbalances, which can affect mood and general health.
- To assess imbalance since sertraline can cause hyponatremia and in this case of overdose it can be severe which can worsen the patient pre-existing depressive symptoms
- Imbalance of other electrolytes like magnesium and phosphatase can also cause irregular cardiac rhythm.

* Patient result were **Normal**

Hematology CoA

Aim:

to check for any clotting abnormality since SSRIs like sertraline can have antiplatelet effects especially if there is liver abnormality

* Patient result were **Normal**

Thyroid function test

Aims: Baseline for future reference and to rule out hypothyroid which can also cause the sign and symptoms of depressive mood.

* Patient result were **Normal**

Urine toxicology test:

Aim: To Identify potential substance abuse.

* Patient results were **negative** for all substances tested. However this test could not detect Magic Mushrooms.

ECG: To check baseline cardiac function and assess side effects of medication and overdose. His ECG were normal

Brain CT scan: To rule out any structural abnormality or organic lesion that can lead to patient sign and symptoms. Patient result revealed no acute intracranial haemorrhage or focal brain parenchymal lesion.

Other suggestion: -

Serum Toxicology: To check the level of Sertraline/other substances post overdose. However these test are not available in Malaysia.

9.2 PSYCHOLOGICAL INVESTIGATION

- ➢ Structured Clinical Interviews & MSE to assess cognitive function
- ➢ Spiritual evaluation: The patient's faith and spiritual practices may provide strength and act as protective factors in mental health recovery.
- ➢ Standardised Rating Scales:
- Beck depression Inventory to assess severity of depressive symptoms
- Young Mania Rating Scale since patient report of hypomanic symptoms
- Sad person scale or Beck Suicidal scale to assess suicidal intent, or planning
- ➢ Psychological evaluation of stressors such as marital conflict and financial struggles, which appear to exacerbate symptoms.

9.3 SOCIAL INVESTIGATION

- Collateral history from other family members to obtain accurate information to form an accurate diagnosis.
- Social functioning assessment by using tools like Global Assessment of Functioning (GAF) to evaluate the patient's daily functioning in areas such as work, self-care, and social relationships.
- Social Support Assessment: To determine the level and quality of the patient's support network and identify social deficits that may impact recovery.
- Assess social context history of substance use to understand if peer relationships or other environmental factors may be contributing.
- Family Assessment: For potential support systems and stressor
- Cultural assessment since cultural beliefs and practices can influence perceptions of mental illness and treatment adherence.
- Assessment of financial stability, as financial stress is a significant stressor in this patient.

10.0 FINAL DIAGNOSIS

Major Depressive Disorder, Severe, with Suicidal risk all other diagnosis has been ruled out in clinical interview and MSE except Depressive disorder due to other medical condition which was ruled out by the investigation.

11.0 MANAGEMENT

11.1 ACUTE MANAGEMENT

1) **Admit the patient as he has high suicidal risk.**
2) **Explain ward conditions to the patient.**
3) **Sedate patient using T. lorazepam during transfer for safety.**

11.2 SPECIFIC MANAGEMENT

PHARMACOLOGICAL

- Antidepressant Therapy: Optimise the sertraline dose or consider switching to an alternative SSRI such as Fluoxetine if ineffective.
- Benzodiazepine such as Lorazepam as-needed, to help with sleeping disturbance. Clear guidance on dosage and timing must be given to prevent excessive drowsiness and interference with caregiving as it is the issue raised by the patient.
- If patient are still suicidal or condition worsen then Electroconvulsive Therapy (ECT) can be considered.

PSYCHOLOGICAL

a) Psychoeducation: Education for the patient and family on MDD including relapse sign, treatment options, and coping strategies to manage symptoms. Also address any medication misconception in the family and educate them on the importance of adherence for a better prognosis. And in this case, inform on the impact of substance use on his condition.
b) Psychotherapy

- Cognitive Behavioral Therapy (CBT): Helps patients recognize and change negative thoughts such as feelings of worthlessness and guilt for relapse prevention.
- Dialectical Behavior Therapy (DBT): Useful for patients with suicidal ideation or past attempts, by focusing on emotion regulation.
- Supportive psychotherapy therapy: Helps improve coping skills

SOCIAL

- Spiritual theraphy: Refer patient to religious leader and encourage him to use their spiritual practices as it may play an important role in their coping, healing process and suicide prevention.
- Family therapy: Family conflict is a strong stressor for the patient's depressive symptoms, so better communication, and understanding family is crucial for as a support system and relapse prevention.
- Peer Support Groups: Engaging with support groups for depression and substance abuse recovery may offer a sense of community and help with emotional healing.
- Supportive employment: The patient is currently unemployed and experiencing financial stress, which contributes to feelings of worthlessness. Referring the patient to Occupational Therapies for job search can help improve self-esteem and reduce the stress associated with unemployment.

11.3 DISCHARGE PLAN (discuss with both patient and family- Wife and mother)

a) Discuss medication adherence & relapse prevention as mentioned
b) Outpatient psychiatry follow-up to assess progress of the patient and any side effect of medications
c) Safety plan and suicide prevention:

- Provide written safety plan on recognizing and managing symptoms including communicating his feelings with family, self distraction by joining sport events or playing with his kids, and also islamic therapy by praying or reciting the Quran since faith is one of his protective factor.
- Inform family to remove means of self harm by removing or limiting access to potentially harmful substances, medications, or tools at home

d) Sleep Hygiene: Improve sleep quality, as poor sleep can worsen depressive symptoms.

12.0 PROGRESS OF ILLNESS/PRESENTATION

Date/ Day of admission	**Progress**
29/10/2024 (Day4 of adm.)	● Slept well last night with T. lorazepam. No awakening at night ● Visited by his wife and school friends ● MSE and PE were normal with no significant findings. ● Good eye contact. Mood improved, described as euthymic. The Effect was congruent with his mood. ● No more suicidal thought.
30/10/2024	● Patient well, MSE and PE was normal ● Appear happy, can't wait to see his child ● No suicidal thought ● Discharged, waiting for wife to pick him up

13.0 LIFE-EVENT CHART

*** From birth to admission*

**** Include all significant mental event/ past admission*

DISCUSSION

1) *Criteria A: ≥5 of the following symptoms for a minimum duration of 2 weeks (at least 1 is depressed mood/loss of interest or pleasure

a. Depressed mood most of the day (feels sad, empty, or hopeless)

b. Diminished interest in almost all activities/ Anhedonia

c. Weight loss of more than 5% of body weight within a month's duration or loss of appetite

d. Sleep disturbances (insomnia or hypersomnia) almost everyday

e. Psychomotor changes (either agitation or retardation)

f. Generalised feelings of low energy or fatigue almost everyday

g. Feeling worthless, or excessive guilt

h. Attention and concentration difficulties

i. Recurrent thoughts of death/ suicide ideation/ attempts

*These symptoms must have caused marked impairments in terms of premorbid functioning.

2) The importance of specifiers is to help guide pharmacological and therapeutic interventions for different types of MDD. It also identifies prognosis since some types, such as melancholic features or psychotic features, are associated with a more severe course of depression and may require more intensive treatment or close monitoring. Differentiation from other conditions: Specifiers can also help distinguish MDD from other mood disorders, such as bipolar disorder or anxiety disorders, ensuring a more accurate diagnosis and more effective management.

3) This article discusses major depressive disorder (MDD), a global health issue affecting about 300 million people and leading to significant disability and societal burden. By 2030, it may become the top cause of global disease burden, highlighting the need for effective approaches in prevention, diagnosis, and treatment.

First part of the article focuses on understanding MDD symptoms beyond mental health as MDD also affects an individual physically, such as fatigue, weight loss, changes in sleep, and cognitive challenges.

The second part focuses on the etiological theory of MDD such as neurotransmitter imbalance theory that suggests that shortage of certain brain chemicals like serotonin, leads to depressive symptoms. Second theory is Stress Response System (HPA Axis) suggesting over-activate the body's stress response hormone caused by stress and potentially leading to depression. Other theories suggest the role of inflammation in MDD, structural changes in brain regions like the prefrontal cortex, hippocampus, and amygdala, which are involved in mood regulation, memory, and stress response. Genetics and environmental aspect might also play a role, besides the involvement of Astrocytes which help regulate neurotransmitters, protect neurons, and maintain the blood-brain barrier and their interaction with glial cells (support cells) in the brain contribute to MDD by affecting brain communication, inflammation, and stress responses.

Second part focuses on diagnostic challenges in MDD as its symptoms overlap with those of other conditions, and there's no simple test for it unlike medical illness. Researchers are looking for measurable indicators of MDD to improve diagnosis. This part also focuses on treatment options beside antidepressants, including drugs that target inflammation, astrocyte function, or even light therapy and acupuncture. The goal is to address the various pathways involved in MDD rather than focusing on just one aspect, like neurotransmitter levels.

This article also involves a systemic view of MDD isn't just about the brain so other systems including immune system, gastrointestinal, and endocrine system should also be taken into account when a person is presented with depressive symptoms.

4) Serotonin syndrome is a condition that can occur when there is excessive serotonin activity in the brain. This is often caused by the use of serotonin-enhancing drugs such as SSRIs, including sertraline, especially when taken in higher doses as seen in this case of overdose. Symptoms might include cognitive changes like agitation, confusion, hallucinations, delirium; Autonomic dysfunction such as fever, tachycardia, hypertension, sweating, shivering; Neuromuscular abnormalities including tremors, hyperreflexia, muscle rigidity, and clonus; Gastrointestinal symptoms such as , nausea, vomiting, diarrhoea. Treatment options for this syndrome include, antiseizure drugs, muscle relaxants, and 5-HT receptors blockers such as cyproheptadine can be used.

REFERENCES

1) Diagnostic and Statistical Manual of Mental Disorders 5th edition DSM-5, President Dilip V. Jeste, President-Elect Jeffrey A. Lieberman, David Fassler, Rcxser Peele, 2013 American Psychiatric Association
2) Kaplan & Sadock's Synopsis of Psychiatry 12th edition, Robert Joseph Boland, Marcia L. Verduin, Pedro Ruiz, 2022 Wolters Kluwer.
3) New Oxford Textbook of Psychiatry 3rd edition, John R. Geddes, Nancy C. Andreasen, Guy M. Goodwin, Oxford University Press 2020
4) Mastering Psychiatry A core textbook for Undergraduates 2016 edition, Melvyn WB Zhang, Cyrus SH Ho,
5) DSM-5 Handbook of Differential Diagnosis, Michael B. First, 2014 American Psychiatric Association.
6) Millier A, Schmidt U, Angermeyer MC, Chauhan D, Murthy V, Toumi M, Cadi-Soussi N., 2014, Humanistic burden in schizophrenia: a literature review.
7) Cui, Lulu et al. "Major depressive disorder: hypothesis, mechanism, prevention and treatment." *Signal transduction and targeted therapy* vol. 9,1 30. 9 Feb. 2024, doi:10.1038/s41392-024-01738-y

---

APPENDICES (if any)

LIST OF ABBREVIATION

FORENSIC

1. DETAIL OF THE DECEASED

- **Name:** Encik H
- **Sex:** Male
- **Age:** 32 years old
- **Race:** Malay
- **Date of Birth:** 01/10/1992
- **Date/Time of Death:** 19/08/2025 (10:15 AM)
- **Date/Time of Autopsy:** 19/08/2025 (3:00 PM)
- **Type of case:** Medico-legal case

2. HISTORY

- **Ante-mortem History:** The deceased, a marathon runner, had no known past medical history. He was reportedly in good health and a non-smoker. His last medical check-up was two years prior, and all results were normal. He had no history of palpitations, syncope, or chest pain.
- **Events Leading to Death:** On the morning of his death, the deceased was participating in a 10km charity run. Witnesses reported that he was jogging at a steady pace near the 8km mark when he suddenly collapsed without any apparent warning. Bystanders, including a medical doctor, immediately initiated CPR. Paramedics arrived within 10 minutes and continued resuscitation efforts.
- **Hospital Presentation:** The deceased was transported to the nearest hospital's Emergency Department (ED). On arrival, he was in cardiac arrest. Despite advanced resuscitation, including defibrillation and administration of cardiac medications, there was no return of spontaneous circulation (ROSC). He was officially pronounced dead at 10:15 AM.

3. EXAMINATION

External Examination

The body is that of a well-built, 32-year-old male with a lean body habitus consistent with an athlete. The body is still warm. Livor mortis is present and well-established on the posterior aspect of the body. Rigor mortis is just beginning in the jaw.

- **General:** No external signs of trauma, such as abrasions, contusions, or fractures. No sign of a struggle or foul play. There are therapeutic marks consistent with CPR, including bruising over the sternum and defibrillation pad burns on the chest.
- **Head and Neck:** No external injuries.
- **Musculoskeletal System:** Normal.

Internal Examination

- **Head and Brain:** The skull is intact, and the brain weighs 1,450 grams, with no signs of hemorrhage, contusion, or edema.
- **Cardiovascular System:** The heart weighs 580 grams, which is significantly higher than the average for an adult male of his size.

The left ventricular wall is markedly thickened (2.5 cm at its thickest point), and the septum is disproportionately thickened compared to the free wall. The coronary arteries are patent and free of atherosclerosis. The great vessels are normal.

- **Respiratory System:** The lungs are congested, but no other gross abnormalities are noted.
- **Abdominal Organs:** All abdominal organs are grossly normal and show no signs of trauma or disease. The liver is unremarkable, and the kidneys appear normal.
- **Other Systems:** All other systems are unremarkable.

4. SUMMARY

A 32-year-old male athlete, with no significant past medical history, suddenly collapsed and died during a 10km run. CPR efforts by bystanders and paramedics were unsuccessful. External examination revealed no signs of trauma, but the autopsy revealed a **markedly hypertrophied heart**, with a left ventricular wall thickness of 2.5 cm. This finding is consistent with **Hypertrophic Cardiomyopathy (HCM)**, which is the leading cause of sudden cardiac death in young athletes.

5. INVESTIGATION

- **Toxicology:** Postmortem blood and urine samples were collected for toxicology screening to rule out drug use, including performance-enhancing drugs or stimulants, which could have precipitated a cardiac event.
- **Histopathology:** Tissue samples from the heart (left ventricle, right ventricle, and septum) were taken for microscopic examination. Histology is crucial to confirm the diagnosis of HCM by identifying disorganized myocardial fibers, a hallmark finding.
- **Genetic Testing:** Blood or tissue samples were preserved for a potential molecular autopsy. Genetic testing can identify mutations in genes (e.g., *MYBPC3*, *MYH7*) associated with inherited cardiac conditions like HCM. This information is vital for screening surviving family members who may also be at risk.
- **Family History:** A detailed family history was obtained to check for a history of sudden cardiac death or other known cardiac conditions.

6. CAUSE OF DEATH

Cause of Death: Sudden cardiac death due to Hypertrophic Cardiomyopathy (HCM).

7. DISCUSSION

Sudden Cardiac Death in Athletes: Sudden cardiac death (SCD) in young athletes is a rare but tragic event, with a reported incidence of 1 in 40,000 to 1 in 80,000 athletes per year. The most common cause is an underlying, often undiagnosed, cardiovascular condition. **Hypertrophic cardiomyopathy (HCM)** is the leading culprit, accounting for approximately 36% of cases.

Hypertrophic Cardiomyopathy (HCM): HCM is a genetic disease characterized by a thickened heart muscle, particularly the left ventricle, without an obvious cause like hypertension. The thickened muscle can impede blood flow out of the heart and, more importantly from a forensic standpoint, predispose the individual to life-threatening arrhythmias, such as ventricular fibrillation. These arrhythmias can be triggered by the physiological stress of intense exercise, leading to sudden death

REFERENCES

1)

APPENDICES (if any)

LIST OF ABBREVIATION

Anaesthesiology Case Write-Up

PATIENT'S DETAILS

- **Name:** Mr. L
- **Gender:** Male
- **Age:** 45 years old
- **MRN:** 0001009000
- **Race:** Chinese
- **Operation date:** 03/12/2024
- **Diagnosis:** Inguinal Hernia
- **Procedure:** Herniorrhaphy under general anaesthesia

1. HISTORY

1.1 Chief Complaint

A 45-year-old male was admitted for elective hernioplasty for a painless, reducible swelling in the right groin.

1.2 History of Presenting Illness (HOPI)

The patient was well until about six months ago when he noticed a small, soft swelling in his right groin. The swelling was painless and would disappear when he was lying down or when he pushed on it. Over the last two months, the swelling has increased slightly in size and is more prominent when he is standing for long periods or coughing. He reports no pain, nausea, vomiting, or change in bowel habits. He was seen by a general surgeon who diagnosed a reducible right inguinal hernia and scheduled him for an elective hernioplasty.

1.3 Past Medical & Surgical History

- **Hypertension:** Diagnosed 5 years ago, well-controlled on Amlodipine 5mg OD.
- **Surgical History:** None.
- **Previous Hospital Admissions:** None.

1.4 Drug and Allergy History

- **Medications:** Amlodipine 5mg OD.
- **Allergies:** No known drug, food, or environmental allergies.

1.5 Social History

- He is married with two children and works as a factory supervisor. He is a non-smoker and drinks alcohol occasionally.

1.6 Family History

- His father had a history of inguinal hernia.

2. PHYSICAL EXAMINATION

2.1 General Inspection The patient is a male with a medium body built. He was conscious, alert, and well-oriented to time, place, and person (GCS 15/15). He was not in any distress.

2.2 Vital Signs

- **Blood Pressure:** 135/85 mmHg
- **Pulse Rate:** 78 beats per minute, regular
- **Respiratory Rate:** 16 breaths per minute
- **Temperature:** 36.8°C
- **SpO_2:** 98% under room air

2.3 General Examination

- **Head & Neck:** Normal. Mallampati score of 2. Good mouth opening. No dentures.
- **Cardiovascular:** S1S2 heard with no murmurs.
- **Respiratory:** Clear breath sounds on both sides.
- **Abdominal:** Soft, non-tender.
- **Hernia Site:** A reducible swelling was noted in the right inguinal region on coughing and standing.

3. INVESTIGATIONS

- **Full Blood Count (FBC):**
  - **Aim:** To assess for any underlying anemia, infection, or thrombocytopenia.
  - **Result:** Within normal range.
- **Renal Profile (RP):**
  - **Aim:** To evaluate baseline renal function and electrolyte balance.
  - **Result:** Within normal range.
- **Coagulation Profile:**
  - **Aim:** To assess clotting function and bleeding risk.
  - **Result:** Within normal range.
- **Electrocardiogram (ECG):**
  - **Aim:** To assess baseline cardiac function and screen for any arrhythmias, given the history of hypertension.
  - **Result:** Sinus rhythm, no acute ischemic changes.
- **Chest X-Ray:**
  - **Aim:** To rule out any cardiorespiratory conditions.
  - **Result:** Clear lung fields, no cardiomegaly.

4. FINAL DIAGNOSIS

Right Inguinal Hernia

5. MANAGEMENT

- **Pre-operative Management:**
  - The patient was assessed by an anesthesiologist.
  - **Physical Status:** ASA II (due to controlled hypertension).
  - **Airway Assessment:** Mallampati score 2, good mouth opening. No anticipated difficult airway.
  - **Patient Consent:** The patient was informed of the risks and benefits of general anesthesia.
  - **Fasting:** The patient was instructed to be NPO for at least 6 hours prior to the surgery.
  - His regular morning dose of Amlodipine was held as per protocol.
- **Intra-operative Management:**
  - **Type of Anesthesia:** General anesthesia with IPPV. This was chosen to provide complete muscle relaxation, which is essential for a clean and tension-free hernia repair.
  - **Airway Management:** The patient was intubated with an endotracheal tube after induction.
  - **Monitoring:** Standard ASA monitoring including non-invasive blood pressure, ECG, pulse oximetry, and capnography.
  - **Intra-operative Drugs:** Standard induction agents (Propofol), muscle relaxants (Atracurium), and opioids (Fentanyl) were used. Maintenance of anesthesia was achieved with a volatile agent (Sevoflurane).
  - **Fluid Management:** Normal Saline IV fluid was administered.
- **Post-operative Management:**
  - The patient was transferred to the Post-Anesthesia Care Unit (PACU).
  - **Aldrete Score:** He achieved a score of 6, indicating he was stable and ready for discharge to the ward.
  - **Pain Management:** Oral analgesia (Paracetamol and Tramadol) was prescribed.
  - **Discharge Orders:** He was allowed oral fluids and a light diet as tolerated. He was instructed to ambulate with assistance and was monitored for post-operative nausea and vomiting.

6. DISCUSSION

Choice of Anesthesia

For an inguinal hernia repair, a few anesthetic options are available, including general anesthesia, spinal anesthesia, and local anesthesia with sedation. **General anesthesia** was chosen in this case because it provides excellent muscle relaxation and ensures the patient is unconscious and pain-free throughout the procedure. This is particularly important for a tension-free repair, which reduces the

risk of recurrence. Spinal anesthesia is also a good option, but some surgeons prefer general anesthesia for its predictability and because the patient is completely immobile.

Management of Coexisting Medical Conditions

The patient has a history of well-controlled hypertension. The anesthesiologist must be aware of this to ensure his blood pressure remains stable throughout the surgery. Careful monitoring of his **hemodynamics** and the appropriate use of anesthetic agents are crucial. Some anesthetic agents can cause a drop in blood pressure, so careful titration is necessary.The decision to hold or continue his anti-hypertensive medication is based on institutional guidelines, but generally, most are continued except for certain classes like ACE inhibitors and ARBs.

The Importance of IPPV

Like in many other general anesthesia cases, IPPV is required because the muscle relaxant (**Atracurium**) used during surgery causes **respiratory muscle paralysis**. The patient cannot breathe on his own, so the ventilator takes over, ensuring adequate oxygenation and removal of carbon dioxide. This allows the surgeon to operate on a completely still patient, which is essential for a precise and safe procedure.

Post-operative Pain Management

Post-operative pain is a common concern after hernia repair. A multimodal approach is the best practice for pain management. This involves using different types of analgesics to target pain via different mechanisms. In this case, oral **Paracetamol** (a non-opioid) and **Tramadol** (a weak opioid) were prescribed to provide effective pain control while minimizing the side effects of a single drug class. This approach facilitates early ambulation and discharge from the hospital.

REFERENCES

1)

APPENDICES (if any)

LIST OF ABBREVIATION

ENT CASE WRITE-UP

PATIENT'S DEMOGRAPHIC DATA

- **Name:** Encik L.B.K
- **Gender:** Male
- **Age:** 55 years old
- **MRN:** 0001009990
- **Race:** Chinese
- **Date of Clerking:** 15/01/2025

HISTORY

Chief Complaint A 55-year-old Chinese male presented with a 2-month history of a growing lump in his neck.

History of Presenting Illness (HOPI) The patient was well until 2 months ago when he first noticed a lump on the left side of his neck. The lump was initially small but has been growing steadily and is now about 3 cm in diameter. The patient reports no pain associated with the lump.

In the past month, he has also experienced **ear fullness and a reduced hearing** in his left ear. He describes the sensation as if his ear is blocked. This has not been associated with ear pain, discharge, or tinnitus.

He also reports intermittent **nasal obstruction** in his left nostril for the past few weeks, which is made worse at night. He denies any nasal discharge, epistaxis, or facial pain. There are no other symptoms such as headache, diplopia, or swallowing difficulties. He has not experienced any significant weight loss, fever, or night sweats.

He was referred to the ENT clinic by his general practitioner after a physical examination revealed a palpable neck mass and ear changes.

Past Medical & Surgical History

- **Hypertension:** Diagnosed 10 years ago, well-controlled on a calcium channel blocker (amlodipine).
- **Type 2 Diabetes Mellitus:** Diagnosed 5 years ago, on metformin.
- **Surgical History:** None.
- **Past Hospital Admissions:** None.

Drug and Allergy History

- **Medications:** Amlodipine 5mg OD, Metformin 500mg BD.
- **Allergies:** No known drug, food, or environmental allergies.

Family History

- His father passed away from lung cancer. No other family history of malignancy.

Social History

- He is a retired businessman and financially stable. He lives with his wife in Kuala Lumpur. He has been a chronic smoker for 30 years (quit 5 years ago) but denies alcohol consumption. He has a history of consuming salted fish regularly in his younger years.

PHYSICAL EXAMINATION

General Inspection

- The patient is a well-built male, conscious, alert, and cooperative. He is not in pain or respiratory distress. No gross deformities are noted.

Vital Signs

- **Blood Pressure:** 135/85 mmHg
- **Pulse Rate:** 72 bpm
- **Respiratory Rate:** 16 breaths/min
- **Temperature:** 36.7°C
- **SpO_2:** 99% on room air

General Examination

- **Upper Limb:** Hands are warm and well-perfused. Capillary refill is <2 seconds. No signs of systemic disease.
- **Head & Neck:**
  - **Neck:** A firm, non-tender, non-mobile lymph node is palpable at **Level II (jugulodigastric)** on the left side, measuring approximately 3x3 cm. No other palpable cervical lymph nodes.
- **ENT-Specific Examination**
  - **Ear:** Left ear shows no discharge or inflammation. **Rinne's test** on the left ear is negative (bone conduction > air conduction), and **Weber's test** lateralizes to the left ear. This indicates a **left-sided conductive hearing loss**.
  - **Otoscopy:** Left tympanic membrane appears dull and retracted, suggesting a middle ear effusion. Right tympanic membrane is clear.
  - **Nose:** Nasal passages appear patent. No discharge or masses seen on anterior rhinoscopy.
  - **Nasal Endoscopy:** Reveals a reddish, irregular mass in the left nasopharynx, obscuring the left Eustachian tube opening. The right side is clear.
  - **Throat:** Oral cavity and oropharynx are clear with no lesions or masses. Uvula is central.
- **Systemic Examination**
  - **Neurological:** Cranial nerves appear intact. No diplopia, facial numbness, or trismus.
  - **Respiratory:** Clear breath sounds on both sides.
  - **Cardiovascular:** S1S2 heart sounds with no murmurs.
  - **Abdominal:** Soft, non-tender, no organomegaly.

SUMMARY

Encik Lim Boon Huat, a 55-year-old Chinese male with a history of hypertension and diabetes, presented with a 2-month history of a non-tender, progressively enlarging neck lump. He also complains of ear fullness and reduced hearing on the same side, along with nasal obstruction. Physical examination revealed a firm, non-mobile lymph node at the left neck, a left-sided conductive hearing loss with a retracted tympanic membrane, and a nasopharyngeal mass seen on endoscopy. These findings are highly suggestive of a primary nasopharyngeal carcinoma with cervical lymph node metastasis.

PROVISIONAL DIAGNOSIS

Nasopharyngeal Carcinoma (NPC)

- **Supporting Points:**
  - **Demographics:** The patient is a Chinese male in a common age group for NPC.
  - **Risk Factors:** History of chronic smoking and regular consumption of salted fish.
  - **Clinical Triad:** The patient presents with a classic triad of symptoms: a neck mass (lymphadenopathy), ear symptoms (conductive hearing loss due to Eustachian tube obstruction), and nasal symptoms (obstruction).
  - **Physical Findings:** A firm, non-mobile neck mass and a visible nasopharyngeal mass on endoscopy strongly support the diagnosis.

DIFFERENTIAL DIAGNOSIS

Differential Diagnosis	Supporting Points	Points Against
Lymphoma	The mass in the neck could be a primary lymphoma, as the nasopharynx is a common site for extranodal lymphoma. Cervical lymphadenopathy is also a primary feature.	Systemic symptoms like fever and weight loss are often present in lymphoma but are absent here. The endoscopic appearance of an irregular, reddish mass is more typical of a carcinoma than a smooth lymphoma.
Tuberculosis of the Nasopharynx	Both a nasopharyngeal mass and cervical lymphadenopathy can be due to TB, which is endemic in some regions.	Systemic symptoms of TB (fever, night sweats, weight loss) are not present. The patient has no history of exposure.
Benign Mass (e.g., Angiofibroma)	Can present with nasal obstruction and a mass in the nasopharynx.	Angiofibromas are typically seen in adolescent males and

		cause profuse epistaxis. The patient's age and the presence of a metastatic neck mass are inconsistent with this diagnosis.

INVESTIGATIONS

- **Laboratory/Baseline:**
  - **Full Blood Count (FBC):** To check for anemia or signs of infection.
  - **Renal Profile & LFT:** To assess baseline organ function before starting treatment.
  - **Epstein-Barr Virus (EBV) Serology:** To confirm association with EBV, which is a strong marker for NPC.
  - **Biopsy of Nasopharyngeal Mass:** The definitive diagnostic test for NPC. A biopsy specimen will be sent for histopathological examination (HPE).
- **Imaging:**
  - **MRI of the Nasopharynx and Neck:** Provides detailed images of the primary tumor's extent and soft tissue involvement.
  - **CT Scan of Thorax, Abdomen, and Pelvis:** For distant staging to check for metastases.
  - **PET-CT Scan:** A highly sensitive scan used to detect distant metastases and guide treatment.
- **Other:**
  - **Audiogram:** To confirm the type and degree of hearing loss.
  - **Dental Examination:** Essential to assess dental health before radiotherapy, which can increase the risk of osteoradionecrosis.

FINAL DIAGNOSIS

Based on clinical findings and the anticipated biopsy results, the final diagnosis is **Non-keratinizing Nasopharyngeal Carcinoma, Undifferentiated Type**, with regional cervical lymph node metastasis. The TNM staging will be determined after all imaging and biopsy results are available.

MANAGEMENT

- **Treatment Plan:**
  - The primary treatment for NPC is a combination of **radiotherapy and chemotherapy**.
  - The patient will likely undergo **concurrent chemoradiation** with a platinum-based chemotherapy agent (e.g., Cisplatin) to make the cancer cells more sensitive to radiation.

    - **Radiotherapy** will be delivered to the nasopharynx and the affected lymph nodes using Intensity-Modulated Radiotherapy (IMRT) to spare surrounding healthy tissue.
- **Supportive Care:**
    - **Symptom Management:** Managing ear fullness, hearing loss, and nasal obstruction.
    - **Nutritional Support:** The patient should be referred to a dietitian to prevent malnutrition due to the disease or treatment side effects.
    - **Psychosocial Support:** Offering counseling to help the patient and his family cope with the diagnosis.
- **Follow-up:**
    - The patient will require close long-term follow-up with regular physical examinations, endoscopic checks, and repeat imaging to monitor for recurrence or distant metastases.

DISCUSSION

1. Epidemiology and Risk Factors of NPC NPC is a rare cancer in most parts of the world but is **endemic in Southern China and Southeast Asia**, including Malaysia. This patient's ethnicity (Chinese) and age group are typical for the disease. Key risk factors include **genetic predisposition**, **Epstein-Barr Virus (EBV) infection**, and **environmental factors** such as the consumption of preserved foods (like salted fish) and exposure to wood dust or tobacco smoke.

2. Clinical Features The patient's presentation with a painless neck lump is the most common presenting symptom of NPC, as the cancer often spreads to the cervical lymph nodes early. The ear fullness and hearing loss are due to the mass obstructing the **Eustachian tube**, which connects the nasopharynx to the middle ear. This obstruction leads to a negative pressure in the middle ear and the accumulation of fluid, causing conductive hearing loss.

3. Spread of NPC NPC has a high propensity for both local and distant spread.

- **Local Spread:** The tumor can invade surrounding structures, including the skull base and cranial nerves. The **sixth cranial nerve** is the most commonly affected, leading to double vision (diplopia).
- **Lymphatic Spread:** It spreads early to the cervical lymph nodes.
- **Distant Metastasis:** Common sites include the **bones, lungs, and liver**. The absence of systemic symptoms like weight loss or fever is encouraging, but distant metastases must be ruled out with full staging scans.

4. The Role of Biopsy and Imaging A biopsy is essential to confirm the diagnosis and determine the histological subtype. The **non-keratinizing undifferentiated subtype** is the most common type in endemic regions and is highly sensitive to radiotherapy. Imaging, especially MRI and PET-CT, is crucial for accurate staging, which determines the appropriate treatment plan and prognosis. A multidisciplinary team approach involving ENT surgeons, oncologists, and radiologists is essential for comprehensive management.

REFERENCES

1)

APPENDICES (if any)

LIST OF ABBREVIATION

SURGERY CWU

PATIENT BIODATA

Registration No. :

Name : XYZ

Age : Y years old

Gender :

Ethnicity. :

Occupation. :

Address :

Ward/Bed. :

Date of admission:

Date of clerking. :

Informant. : Patient himself / family etc

1. HISTORY

1.1 CHIEF COMPLAINT

Mr. XYZ, a Y years old, Malay Male with no known medical illness was presented to the hospital with complaints of per rectal bleeding for 1 month.

1.2 HISTORY OF PRESENTING ILLNESS

Patient was apparently well until 1 month ago when he noticed blood mixed in his stool. Initially it was of small amount and not associated with any pain. He then visited the clinic and was treated for haemorrhoids and given Daflon. His symptoms did not resolve but got progressively worse and he also started to experience pain while passing stool and had difficulty in passing stool. Pain was score was 6/10. His bleeding also got worse until he had to wear an adult diaper since 3 days ago. This symptom was also associated with altered bowel habits for the past 1 month, normally he has BO 2-3 times per day with normal stool consistency but recently he only has BO about 1-2x/day with small pallet stool, hard. Beside this he also has a constant urge to defecate as if something is stuck (tenesmus) which is not relieved by passing stool. Since 1 week ago he started to have diarrhea which is watery diarrhea mixed with blood. He also has on and off fever 1/52 but no temperature was documented at home. Patient also noted weight loss of 10kg with loss of appetite.

Subsequently he tried traditional meds (akar kayu) to stop the bleeding. This also did not help and he then went to clinic again and was referred to hospital

Otherwise he has no vomiting, no other bleeding tendencies, no recent history of taking outside food or swimming/jungle trekking or sick contact

For anemic symptoms, he only experiences fatigue. Otherwise no, shortness of breath, pale skin, dizzyness, cold peripheries, or chest pain.

OTHER SYSTEM REVIEW

I. General

Generally, the patient is febrile, with no chills or rigors, no fatigue, no reduced effort tolerance or pallor.

II. Cardiovascular System

Patient does not experience any chest pain, orthopnea, paroxysmal nocturnal dyspnea, diaphoresis, palpitation, tachycardia or lower limb swelling.

III. Respiratory System

She has no dyspnoea, tachypnoea, cough, haemoptysis, sore throat, hoarseness of voice, rhinitis, epistaxis, or gum bleeding

IV. Genitourinary System

For the reproductive system, he has no testicular swelling or pain, no abnormal urethral discharge, and no erectile dysfunction

For urinary system, no flank pain, urinary retention, straining, hesitancy, urgency, urinary incontinence, incomplete emptying of the bladder, terminal dribbling, dysuria, hematuria, crystalluria, pyuria, pneumaturia, oliguria, polyuria, anuria, nocturia or necturia.

V. Musculoskeletal System

No bone pain or history of any bone fracture. No arthralgia, joint swelling, joint stiffness, joint limitation. No myalgia, muscle stiffness, muscle wasting, or recent trauma. No vertebral deformity such as kyphosis, scoliosis, lordosis

VI. Nervous System

No headache, no seizures, no loss of consciousness, no altered consciousness, no memory loss, no numbness, no no weakness, no tremor, no diplopia, no blurring

of vision, no tinnitus, no focal or neurological defect.

VII. Endocrine system

The patient does not experience polydipsia, polyuria, polyphagia, nocturia , no blurring of vision or tingling sensation. Additionally, she denied any neck swelling, hot or cold intolerance, excessive sweating or dry skin, easy irritation or mood swing.

VIII. Dermatological

Patient denied any abnormal hypo/hyper pigmentation, rashes, pruritus, easy bruising, purpura, ecchymoses, ulceration, skin lesions or masses elsewhere

1.3 PAST MEDICAL HISTORY

He has no known medical illness or

He was admitted to Hospital Krai for 1 week in 2022 for Paralysis of bilateral lower limb post trauma injury during playing takraw. Discharged

1.4 PAST SURGICAL HISTORY

He has never undergone any surgical procedure.

1.5 DRUG HISTORY

- No significant drug history

1.6 ALLERGY HISTORY

The patient had no known food, medication or environmental allergies.

1.7 FAMILY HISTORY

- His father passed away from an accident and mother is alive with underlying hypercholesterolemia. Patient is the 8th out of 10 siblings unsure of any underlying medical illness of his sibling but believes that they are well. There is no history of malignancy in the family or other family members with similar symptoms.

1.8 SOCIAL HISTORY

- Patient lives in ____ with his sister. He works as a factory worker and can financially support himself. He is an ex-smoker and used to smoke 1 box 3-4 days. Otherwise she denied any history of high risk behaviour, alcohol consumption or any drug abuse. For his diet, he usually consumes home cooked meals but rarely takes any fruit or vegetables. He also does not do any regular exercise and sleeps for about 6-7 hours per day. He is single, not sexually active and has never practised any sexual promiscuity previously. He also has not

travelled anywhere outside Selangor for the past 3 months.

1.9 IDEA, CONCERN AND EXPECTATION

- Idea: Patient thinks his condition is due to hemorrhoid.
- Concern: Patient is concerned about the screening that he has to undergo.
- Expectation: Patient believes that the doctors will do their best and he hopes to recover well so he can be discharged and continue to word

1. PHYSICAL EXAMINATION

For this examination, I had a chaperone with me. Before starting, I washed and sanitised my hands, introduced myself as a 3rd year medical student from University XXX and identified the patient by asking his name and age. I also explained the procedure to him and gained his consent as this procedure requires exposing the abdominal area and doing per rectal examination.

1.1 GENERAL INSPECTION

Upon general inspection, GCS was full, he was alert, fully conscious, well oriented to time, place, person & cooperative. He was pink, not tachypnea and speaks in full sentences but appears lethargic. Patient had branula at left brachial, and a 18G green cannula at right dorsum which was connected to IVD, no phlebitis seen. Otherwise no other medical equipment including no supplemental oxygen or ambulating aid in the patient's surroundings.

1.2 VITAL SIGNS

Components	Upon clerking
Blood pressure (mmHg)	109/52
Pulse rate (beats per minute)	98 regular rhythm no special characteristic (bounding pulse, radio-radial delay), good volume, and compressible vessel wall
Respiratory rate (breaths per minute)	20
Temperature (°C)	37
Oxygen saturation (% under RA)	100

Pain Score: 2/10

1.3 GENERAL EXAMINATION

Upon hand inspection, peripheries are warm, moist and pink. There is no peripheral cyanosis, no palmar erythema, no muscle wasting, no fine or flapping tremor. Upon inspection of the nail beds, capillary refill time is less than 2 seconds, no finger clubbing, no splinter haemorrhages, no koilonychia, and no leukonychia. Upon inspection of the forearm, there was a BCG vaccine scar on the left forearm and brachial pulse was palpable on both arms with full volume. Otherwise no bruising, ecchymosis, scars, erythema, or abnormal pigmentation were present.

Upon inspection of the scalp, there was no mass, swelling, tenderness, alopecia, and no tinea capitis seen.

Upon face inspection, inspection of the eyes, there is conjunctival pallor seen, scleral jaundice, or subconjunctival haemorrhage seen. On nose inspection, no nose deformity, no nasal flaring and no nasal discharge was noticed. Upon mouth examination, the patient has fair oral hygiene and good hydration, no central cyanosis, no oral thrush, no angular stomatitis or glossitis, no ulceration and no high arched palate. Tongue was moist and not coated.

Upon examination of the neck, no jugular vein was not distended, no supraclavicular lymph nodes or cervical lymph nodes and no Virchow's nodes palpable. There was no tenderness, masses, or thyroid enlargement. Carotid pulse present bilaterally, with full volume. No carotid or thyroid bruit heard upon auscultation.

Examination of the lower limb revealed no pedal oedema, or dilated prominent veins. Dorsalis pedis and posterior tibialis pulse palpable bilaterally.

1.4 SYSTEMIC EXAMINATION

2.41 Specific: Gastrointestinal system

Upon inspection from the right side and the foot of bed, the patient is lying flat and exposed properly. The abdomen was flat, symmetrical and moved with each respiration. The umbilicus was centrally located and inverted. There were no skin

discoloration, surgical scar, dilated veins, visible peristalsis, visible pulsation, caput medusa and no cough impulse seen. bilateral hernial orifices were intact.

On superficial palpation, the abdomen was soft and warm equally on all 9 regions, no abdominal guarding or tenderness noted. On deep palpation, no tenderness or palpable mass was noted. Also no hepatomegaly, or splenomegaly. Both kidneys were not ballotable and renal punch were negative.

Upon percussion, the abdomen was resonant at all 9 regions and no shifting dullness was present. Liver dullness is present at right 5th intercostal space and extended to the right costal margin, liver span was about 8 cm and Troube's space (9-11 ICS) was resonance on percussion.

Upon auscultation, on Mcburney point 15 gurgling bowel sounds were heard per minute. No aortic or renal bruit heard.

I was supposed to complete my examination, by doing a per -rectal examination and external genitalia examination but not done due to lack of consent from the patient.

Per-rectal examination was done by the doctor and assisted by me. This examination revealed blood stained mucus noted in diaper, anal region shows no excoriation or fissure but there were 3 cm polypoidal mass from anal verge which were unable to get above. Proctoscope revealed Fungating mass occupying ⅔ of the lumen. Mass surface was sloughy with contact bleeding.

2.42 Other system

RS: Vesicular breath sound with equal entry to both lung field
CVS: S1S2 Heard, No murmur
CNS: Normal Tone, Power and Reflexes

3.0 CASE SUMMARY

Mr. XYZ, a Y-year-old Malay male with no significant past medical history, presented with a

1-month history of progressive per-rectal bleeding, initially small in amount but later worsening, requiring the use of adult diapers. He also experienced pain during defecation, altered bowel habits, tenesmus, and systemic symptoms including lethargy, on-and-off fever, and significant weight loss (10 kg). Despite initial treatment for hemorrhoids and use of traditional medicine, his symptoms persisted and worsened. On examination, he appeared lethargic. Per-rectal examination revealed a 3 cm fungating, polypoidal mass occupying 2/3 of the rectal lumen with a sloughy surface and contact bleeding. There were no signs of tenderness, palpable organomegaly, or other systemic abnormalities on abdominal examination. His social history revealed a diet low in fiber, and he is an ex-smoker. The findings strongly suggest malignant rectal pathology.

4. DIAGNOSIS

4.1 Provisional

Rectosigmoid carcinoma/ tumor, as he is presented per rectal bleeding for the past 1 month associated with obstructive symptoms including tenesmus and altered bowel habits (from normal bowel habits to hard pellet stool, followed by diarrhea). He also has significant weight loss (10 kg) and loss of appetite, indicative of a systemic illness such as malignancy. Examination revealed fungating mass occupying 2/3 of the rectal lumen with contact bleeding. Besides this patient also has risk factors like smoking and low intake of fruits and vegetables, possibly leading to low dietary fiber.

4.2 Differential

No.	Differential Diagnosis	Positive Findings	Negative Findings
1.	Inflammatory Bowel Disease (IBD)	• Chronic per-rectal bleeding • Bloody diarrhea	• No prior history of similar symptoms, which is unusual for IBD as it often presents in a relapsing-remitting manner. • No systemic features like skin

		mixed with stool. ● Obstucyive Symptoms (tenesmus and altered bowel habits) ● Onset of fever suggests an inflammatory or infectious process.	lesions, joint pain, or eye involvement typically seen in IBD. ● Mass on examination is more suggestive of malignancy than IBD.
2,	Hemorrhoids	● History of per rectal bleeding initially diagnosed as hemorrhoids. ● Initial treatment with Daflon.	● Symtoms did not resolve with Daflon. ● Fungating rectal mass detected on examination is not consistent with hemorrhoids. ● Progression of symptoms such as weight loss, tenesmus, and altered bowel habits is unusual for hemorrhoids. ● No external hemorrhoids or anal fissures observed during examination.
3.	Infective Colitis	● Watery diarrhea mixed with blood for 1 week. ● Onset of fever suggests infection.	● Chronic symptoms for 1 month are more suggestive of malignancy. ● Presence of a fungating mass is not typical of infective colitis. ● No history of eating outside food, travel, or exposure to sick contacts.
4.	Rectal Polyp	● Polypoidal mass noted on per rectal examination. ● Can present with rectal bleeding and tenesmus.	● A fungating mass with sloughing and contact bleeding suggests malignancy rather than a benign polyp. ● Systemic symptoms like weight loss and loss of appetite are unusual for

			benign conditions.

5. INVESTIGATION

5.1 BLOOD/LABORATORY

I. Full Blood Count (FBC)

Components	Unit	Reading	Reference Range
White blood cell	9 10 /L	13.3 (H)	3.5.0-12.0
Red Blood Cell	12 10 /L	4.2	3.8-5.5
Haemoglobin	g/dL	8.6 (L) >9.3 post transfusion	12.0-15.0
Haematocrit	%	28 (L)	40.0-50.0
Platelet	9 10 /L	693 (H)	150-400
MCV	fL	70.7 (L)	76-100
MCH	pg	21.7 (L)	26.9-32.2

Aim: To assess overall health of the patient and detect abnormalities such as anaemia and also platelet disorder since patient has active blood loss. Also to check for any infection/inflammation and since he is presented with fever

Interpretation: Patient is anaemic as result of continuous blood loss, has increased WBC and platelet level which might be indicative of ongoing inflammation. Anemic workup was requested to look for causes of anemia,

+ **CRP**: 168 (high): Inflamation

II. Renal profile

Components	Unit	Reading	Reference Range
Urea	mmol/L	3.6	2.5-6.4
Creatinine	mmol/L	63	49-90
Sodium	mmol/L	141	138-146
Potassium	mmol/L	3.6	3.5-5.1
Chloride	mmol/L	105	98-107

eGFR	mL/min/1.73m2	112	>90

Aim: performed to assess baseline/general kidney function

Interpretation: No finding of renal pathology.

III. Liver function test

Components	Unit	Reading	Reference Range
Total Protein	g/L	76	60-80
Albumin	g/L	25 (L)	35-55
Globulin	g/L	41	35-50
A/G ratio	-	0.7 (L)	1.0-1.6
Total Bilirubin	umol/L	9	3-22
Alkaline Phosphatase	IU/L	229 (H)	33-98
Alanine Aminotransferase	IU/L	18	<35
Aspartate Aminotransferase	IU/L	16	<35

Aim: performed to assess baseline liver function as inflammation in the body can lead to liver damage and also check for sign of liver metastases

Interpretation: Reduced Albumin and A/G ratio might indicate inflammtion while elevated ALP might indicate liver metastasis in this patient so abdominal CT was requested to rule out synchronous tumor.

IV. Anemia profile

Components	Unit	Reading	Reference Range
Iron	µg/dL	2 (Very Low)	50-170
TIBC	µg/dL	31 (Very Low)	250-450
Ferritin	ng/mL	336	20-250
Folate	ng/mL	10	3-17
Transferrin	g/L	6 (H)	2-4.5

Aim: To check for anemia profile since patient have bleeding for past 1 month

Interpretation: The patint result is suggestive of anemia of chronic disease (ACD)

rather than pure iron deficiency anemia. This is suggested by the combination of low iron, low TIBC, and high ferritin. The elevated transferrin further supports this, as it is typically higher in response to iron deficiency.

V. Coagulation profile

Components	Unit	Reading	Reference Range
PT	Sec	11.1	11-13.5
INR	-	1.01	>1.1

Aim: To check for bleeding disorder since patient is presentedt with per-rectal bleeding

Interpretation: Normal

VI. Tumor Marker

Components	Unit	Patient Result	Reference range
CEA	ng/mL	1.6	0-2.9
PSA	ng/mL	1.19	1-1.5
CA19-9	U/mL	7	<40
AFP	ng/mL	<1.1	<40

Aim: Protocol screening since rectosigmoid carcinoma is suspected. And to check for metastases

Interpretation: Normal

5.2 IMAGING

VII. Abdominal X-Ray: No dilated bowel

- Include pic

VIII. Chest X-Ray: Clear

- Incl Pic

IX. CT Abdomen/Pelvis (CT-TAP):

- Incl pic

Finding:

- There is large heterogeneous enhancing fungating mass seen arising from the anterior bowel wall at rectosigmoid junction, measuring approximately 6.4cm x 7.0cm x 6.8cm (APx W x CC). The mass has seen almost obliterating the bowel lumen, however contrast still able to pass through. No bowel dilatations seen proximally.
- Anteriorly, there is poor fat plane

- Minimal atelactasis changes seen at the visualized both lung bases.
- Few pleural based nodule seen at posterior segment of night lower lobe with largest measuring 0.5cm x 0.9cm (AP x W).

Impression:

- Rectosigmoid junction bowel mass high likely of malignancy with liver and pleural based metastasis. No evidence of acute bowel obstruction.

X. Sigmoidoscopy:

Finding

- Tumor occupying >75% of lumen (5 cm from anal verge).
- Contact bleeding noted.
- Biopsies taken (x8).

Impression: Rectal tumor TRO malignancy

OTHER INVESTIGATIONS (pending result)

1. Histopatholgy examination
2. CT abdomen to rule put syncronous tumor

6.0 FINAL DIAGNOSIS

Rectosigmoid carcinoma, as suggested by clinical finding and investigation.

7. MANAGEMENT

7.1 IMMEDIATE

1) Admit patient
2) Complete full history taking, clinical examination, physical examination, and investigation of the patient.
3) Monitor vital signs every 4 hourly.
4) NPO (Nil Per Oral): Keep the patient fasting to prepare for potential surgery.
5) IV Fluids: Start isotonic fluids such as normal saline to maintain hydration and correct dehydration from diarrhea. **This patient was given IVD 4 pints (2 pint NS and 2 pint Dextrose 5%) over 24h.**
6) Oral rehydration solution per purge since patient is having diarrhea
7) Blood transfusion to correct blood loss from per-rectal bleeding. **This patient was given 1 pint of packed RBC followed by IV cosmofer, IV zincofer, IV**

folic acid prior to surgery.

8) Administer IV analgesics like Paracetamol or opioids like morphine if pain is severe for pain management
9) Antibiotics: Start broad-spectrum antibiotics such as ceftriaxone + metronidazole to cover gut flora and reduce infection risk.

7.2 PRE-OPERATION

1) Inform patient on risk and obtain consent for Trephine proximal transverse loop colostomy
2) KNBM and support with IV fluid
3) Reassess sign and symptoms of anemia

- **This patient had a newly discovered Grade 4 murmur with palpable thrill loudest at apex when examined pre operatively, however operation still goes on and high risk consent was taken from the family.**

7.3 OPERATION

- Trephine proximal transverse loop colostomy on 10/12/24 for rectosigmoid tumour

7.4 POST-OPERATION

1. Monitor vital sign, pain score, and urine output and ECG since patient had murmur preoperatively
2. Check for signs of complications (bleeding, infection, or sepsis)
3. Pain Management: IV paracetamol or NSAIDs initially, followed by oral analgesics as tolerated.
4. Continue antibiotics post-op for 24–48 hours if no perforation.
5. Fluids and Dietary intake: Continue IV fluids until bowel sounds return and gradually advance from clear liquids to a regular diet.
6. Wound Care: Keep the wound clean and dry. Educate the patient on wound inspection for signs of infection (e.g., redness, swelling, or discharge).
7. Encourage ambulation to reduce the risk of post-op complications like deep vein thrombosis.
8. Discharge when the patient is stable.

7.5 Follow Up

- To assess wound healing and overall recovery. It is also important to detect recurrence by doing CT scans, colonoscopy, and CEA (carcinoembryonic antigen) testing.
- Adjuvant chemotherapy may be recommended after surgery, particularly in high-risk patients (e.g., stage III or high-risk stage II).
- Quality of life measures, including bowel function, sexual health, and psychosocial support, should be addressed in the postoperative period.

8.0 PATIENT PROGRESS

INSERT DAILY PROGRESS IF ANY NOTED

Day x of admission	
Day x of admission (post op)	

DISCUSSION

1. **Definition and Pathogenesis**

- Colorectal carcinoma (CRC) refers to malignant tumors arising from the inner lining of the colon or rectum. It is the third most common cancer worldwide.
- The pathogenesis involves genetic and environmental factors. The most commonly implicated genetic alterations are in the APC gene (adenomatous polyposis coli) in the adenoma-carcinoma sequence, which is the most common pathway. Other mutations involve KRAS, p53, and DCC. The carcinogenesis process can be influenced by environmental factors such as diet, lifestyle, and inflammatory bowel disease (IBD).

2. **Clinical Presentation**

- CRC often presents with nonspecific symptoms like change in bowel habits, rectal bleeding, abdominal pain, weight loss, and anemia.

- Early-stage: disease may be asymptomatic, which is why screening is critical in high-risk populations. As the tumor grows, more localized symptoms such as abdominal mass, bloody stool, and obstruction may develop. While, advanced stage can present with systemic symptoms like fatigue, unexplained weight loss, and anemia, with metastasis seen in the liver, lungs, and peritoneum.
- Rectal carcinomas tend to present with more localized symptoms like rectal bleeding, tenesmus, and changes in bowel habits. The presence of a fungating mass and chronic bleeding, with systemic symptoms (fever, weight loss) in this patient may suggest an advanced stage of disease.

3. **Risk Factor**

- Risk factors for CRC include age (most common in individuals >50 years), family history of CRC or polyposis syndromes (e.g., familial adenomatous polyposis, Lynch syndrome), diet (high-fat, low-fiber), inflammatory bowel disease (e.g., Crohn's disease, ulcerative colitis), physical inactivity, obesity, and smoking. Other risk factors include alcohol consumption, type 2 diabetes, and a history of colorectal polyps.

4. **Surgical Anatomy**

- The colon is divided into four sections: ascending, transverse, descending, and sigmoid. The rectosigmoid junction marks the transition from the sigmoid colon to the rectum, and is a common site for rectosigmoid tumors. loop colostomy involves bringing a loop of the colon to the surface of the abdominal wall, allowing for the diversion of fecal matter
- The rectal anatomy is particularly important in cancer surgery, as rectal cancers may involve structures like the pelvic floor, bladder, prostate. The mesorectal fascia is critical in determining whether the tumor is amenable to resection. Additionally, inferior and superior mesenteric artery, and vagus nerve need to be identified and protected.

5. **Complications**

- Bowel obstruction
- Perforation,
- Bleeding
- Metastasis: typically involves the liver and lungs, but local recurrence can occur in the pelvic area. Peritoneal carcinomatosis is another complication in advanced cases.
- Post-operative complications include wound infections, anastomotic leaks, bleeding, and sepsis.
- Long-term complications could include bowel dysfunction, **sexual dysfunction (especially in rectal cancer patients as seen in this case)**, and the psychological impacts of the disease.
- Given the patient's presentation with a fungating rectal mass and bleeding, hemorrhagic shock and iron deficiency anemia are immediate concerns

6. **Psychological and Social Aspects of Care**

- A cancer diagnosis, particularly colorectal cancer, can have significant psychological and social impacts on patients. Issues like anxiety, depression, and body image concerns (especially after a colostomy) must be addressed. Supportive care, including psycho-oncology services, social work, and nutritional counseling, are essential to improve quality of life and outcomes. Patient education is key in helping patients understand their diagnosis, treatment options, and the expected course of treatment.

REFERENCES

1. Bailey & Love's Short Practice of Surgery, by Norman S. Williams, P. Ronan O'Connell, Christopher J.K. Bultrode, 27th Edition, 2019.

2. Browse's Introduction to the Symptoms and Signs of Surgical Disease, 6th Edition, Edited by Kevin G Burnad, John Black, Steven A Carbett and William EG Thomas, 6th Edition, 2021.

3. Oxford Handbook of Clinical Surgery by Greg McLatchie, Neil borley, and Joanna Chikwe, 4th edition, 2013, Oxford University Press

4. Schwartz's Principles of Surgery by F. Charles Brunicardi, Dana K. Anderson, Timothy R. Billiar, David L. Dunn, John G. Hunter, Lillian S. Kao, Jeffrey B. Matthews & Raphael E. Pollock. 11th Edition, 2019. McGraw-Hill Education.

5. Schwartz's Principles of Surgery by F. Charles Brunicardi, Dana K. Anderson, Timothy R. Billiar, David L. Dunn, John G. Hunter, Lillian S. Kao, Jeffrey B. Matthews & Raphael E. Pollock. 11th Edition, 2019. McGraw-Hill Education.

6. Guides on Clinical Surgery: Doctrina Perpetua by Diganta Das, et al. 2nd Edition, 2018. R & S Publishing House.

7. Preparation Handbook: Undergraduate Medical Professional Exit Exam by Chan Chee Yong